NYCPM
New York College of Podiatric Medicine

NYCPM STUDENTS UNDER THE DIRECTION OF DR. JOHANNA GODOY WIN FIRST PLACE AT ACFAS STUDENT POSTER COMPETITION



NYCPM students Britton Plemmons, '13 (left) and Spencer J. Monaco, '13 (right) with their poster.
Not are pictured are Samantha DelRegno, '13 and Todd M. Chappell, '14.

A Rare Incidence of a Fibrosarcoma in the Plantar Foot that Mirrored Fibromatosis: A Case Report

Spencer J. Monaco, BS; Britton Plemmons, BS; Samantha DelRegno, BS; Todd M. Chappell, BA

New York College of Podiatric Medicine 53 East 124th Street New York, NY 10035

Purpose

A case report is presented of a fibrosarcoma that arose in the plantar foot mimicking plantar fibromatosis.

Literature Review

- Fibrosarcoma: a life-threatening malignant tumor of fibroblasts that shows no other evidence of cellular differentiation and is capable of recurrence and metastasis.
- It is known that fibrosarcoma mimics the clinical presentation of the more commonly diagnosed plantar fibromatosis (Ledderhose disease) and is often excluded from the differential diagnosis.
- Fibrosarcoma is a rare soft tissue tumor in the foot and ankle. (Table 1)

	% of all STM	Prevalence in Foot & Ankle (%)	M/F (%)	Mean Age (years)	Recurrence (%)	Survival >5 years (%)
Fibrosarcoma	4.5–6.2	2.5	54/46	38 – 53	57	39

Table 1 (1-5)

- Clinical findings consist of a firm, lobulated mass with ill-defined borders, typically 3-8 cm in size and sometimes accompanied by pain(5,6).
- Most fibrosarcomas are primary tumors that arise de novo from deep fibrous structures.
- Secondary fibrosarcomas may originate in pre-existing lesions and/or areas of previous trauma(2,7,8,9).
- Early diagnosis of this soft tissue neoplasm is paramount. The literature demonstrates that an analytical approach is necessary to diagnose any soft tissue mass including clinical information, prevalence, age, location, findings on radiography, ultrasonography, CT scan, MRI, cytogenetics, molecular genetics, and biopsy (10-12).
- The differential diagnosis may vary dramatically and should completely encompass the many benign as well as malignant possibilities (Tables 2 and 3).

Table 2 (2)

Differential Diagnosis for Foot and Ankle Soft Tissue Masses
▶ Fibroma
▶ Lipoma
▶ Ganglion
▶ Giant Cell Tumor
▶ Rhabdomyosarcoma
▶ Fibrosarcoma
▶ Fibrous Histiocytoma
▶ Leiomyosarcoma
▶ Synovial Sarcoma
▶ Angiosarcoma
▶ Keloid

Table 3 (12)

Case Study

A retrospective case report is presented of a 38-year-old Caucasian male with a two-year history of a plantar soft tissue mass (STM) of his right foot. The patient was first seen by another practitioner four months prior to the initial visit where he was treated conservatively with a dispersion pad. The patient consulted us with an interest in surgical excision of the STM. He states that the mass was originally the size of a peanut, however has since grown larger and is becoming painful on weight bearing.

The patient denies any medical conditions, family history of medical conditions or medication use. He has a ½ pack/day history of smoking cigarettes, and besides the discomfort of the right plantar mass on weight bearing, has no other complaints.

Upon physical examination, the STM was located on the plantar aspect of the right mid-foot near the level of the second tarsometatarsal joint (Figure 1). The size of the lesion was measured to be 3.0x2.0x2.0 cm. Mild tenderness was elicited on direct palpation. The STM was supple to the touch and freely mobile, however the lesion did not move with the plantar fascia when the hallux was dorsiflexed and the windlass mechanism engaged. The patient's vascular, dermatological and neurological status was intact. X-rays and an MRI with and without contrast were ordered to evaluate the integrity of the STM of the right foot (Figure 2).

Fig 1. Gross depiction of STM. A superficial compressible, mobile mass was identified measuring 3.0x2.0x2.0 cm.

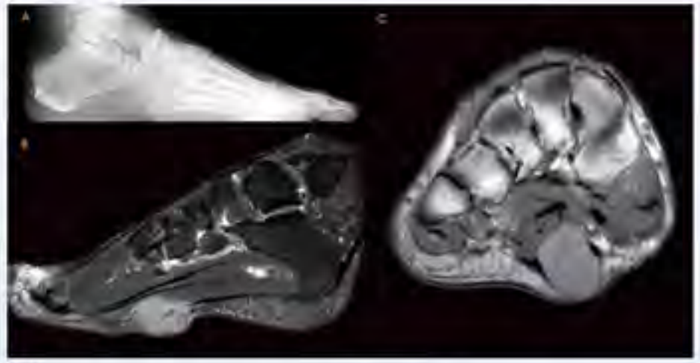

Fig 2.
A. Lateral radiograph with no evidence of bone penetration.
B. T2 - weighted sagittal image demonstrating a hyper-intense signal. Mass size- 3.9x2.2x1.8 cm
C. T1- weighted coronal image demonstrating a hyper-intense signal.

Fig 3. Mass penetrating through the medial band of the plantar fascia with a pedicle extending distally.

The MRI was performed without contrast at the discretion of the reading radiologist and was interpreted as a lesion that demonstrates imaging features most consistent with solitary superficial plantar fibromatosis.

The patient was scheduled for surgical resection of the plantar fibroma. A 6.0 cm curvilinear incision was made over the lesion and blunt dissection to the level of the fibroma was performed. It was observed intra-operatively that the mass penetrated through the plantar fascia (Figure 3) and had a pedicle extending distally which received a relatively large blood vessel medially.

Fig 4. Widely excised specimen measuring 4.5x4.0x4.4 cm

Fig 5. Immunohistochemistry analysis of the tumor. Tumor consists of monotonous spindle neoplastic cells forming intersecting bundles with focal areas displaying herringbone pattern. The cellularity is high and the cytological atypia is moderate. There are many mitotic figures, but necrosis is not seen.

The specimen was widely excised making sure that dissection encompassed 1.0 cm beyond the periphery of the mass. The specimen was sent to pathology for further analysis (Figure 4). The excision site was closely inspected, irrigated with copious lavage and closed primarily. The patient tolerated the procedure well and no complications were reported.

The immunohistochemistry pathology report was analyzed by the radiology department and interpreted as a spindle cell sarcoma which favored an intermediate grade fibrosarcoma (Figure 5).

Results

Two weeks status post-operative surgical resection of the fibrosarcoma, the patient returned for a follow-up visit and the results of the pathology report were discussed. The patient was referred to the oncology department at a nearby hospital in which additional MRI imaging with contrast was ordered. The results of the MRI imaging did not indicate any remaining fibrosarcoma from the post-operative excision site (Figure 6), however the patient underwent an additional surgical wide resection to ensure all malignant tissue was successfully excised and there was no metastasis of the fibrosarcoma. The patient was referred to physical therapy. Five months after resection of fibrosarcoma, there are no signs of recurrence. Patient's life was saved and limb salvage was achieved.

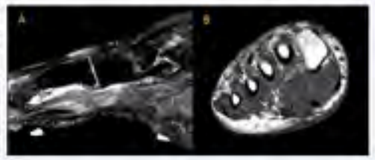

Fig 6.
T-2 weighted sagittal image (A) and T-1 weighted coronal image (B) with contrast showing no evidence of remaining fibrosarcoma.

Discussion

- Soft tissue sarcomas are rare and account for only 0.5 to 1% of all adult malignancies in the United States (1,2).
- MRI is the imaging modality of choice in the assessment of soft tissue tumors of the foot (14,15).
- MRI with contrast provides a peripheral pattern of enhancement when imaging fibrosarcoma that may lead to a more definitive diagnosis (10).
- Incisional biopsy remains the only way to definitively diagnose a fibrosarcoma (13).
- Surgical treatment options include wide excision with a 2cm margin, partial amputation, proximal amputation, and/or local excision with adjunct chemotherapy or radiation treatments (12,16).
- In the recent past, below-knee amputation was the surgical treatment of choice for fibrosarcoma of the foot and ankle, due to the inherent risk of metastasis.
- In 2010, Cribb et al. reported that the presence of a soft-tissue sarcoma in the foot or ankle is not an indication for amputation(17).
- With early detection, proper diagnosis and an aggressive treatment plan, perservation of life and limb can be achieved.

References

1. Brendel M.H. Malignant soft tissue tumors in a large referral population: distribution of diagnoses by age, sex, and location. Eur Am J Roentgenol. 1995;29-134. 1995.
2. Bakotic BW, Borovecki P. Primary soft-tissue sarcomas of the foot: the clinicopathologic profile. Int J Orthop Surg 4:229-236. 2011.
3. Pritchard DJ, Soule EH, Taylor WF, Ivins JC. Fibrosarcoma in clinicopathologic and statistical study. J Bone Joint Surg Am 56:1663-1674. 1974.
4. Meyer A, Hoogendoorn J, Bohlin L, Hansen B. Fibrosarcoma of the foot: a review of the literature. Clin Orthop Relat Res 2000;229-244. 1996.
5. Lang JE, Dodd L, Mentzer S, Bigelow BL. Case report: soft-tissue fibromatosis mimicking fibrosarcoma: report of five cases and literature review. Clin Orthop Relat Res 2003;200-2.
6. Chen MJ, Chen PJ, Mentzer SJ, Chen JH, Hsieh CC. Fibrosarcoma of the foot mimicking plantar fibromatosis. J Am Podiatr Med Assoc 92:101-103. 2002.
7. Ryan RF. Fibrosarcoma of the foot. J Foot Ankle Surg 26:470-534. 1987.
8. Sheehan MA, Weiss SW, Soft tissue fibrosarcoma. A clinicopathologic and statistical study of the literature. Cancer 29:1679-1686. 1982.
9. Stout AP, The fibromatoses and fibrosarcomas. Bull Hosp Joint Dis 12:126-140. 1951.
10. Dominguez-Pinilla N, Barreiro J, Soft tissue sarcoma grading, staging and risk-based prognosis. Top Magn Reson Imaging 19:263-268. 2009.
11. Dickens HM, Finn H, Vinson C, Sugar T. Tumors of the foot and ankle: analysis of 186 cases. J Foot Ankle Surg 36:472-480. 1997.
12. Burns PA, Lewis JW, Coughlin DJ, Grossman DA. Fibrosarcoma of the foot: a case presentation and review of the literature. J Foot Ankle Surg 50:74-78. 1997.
13. Sabo MA. Forefoot as an indication for amputation in the foot. Clin Podiatr Med Surg 14:1:1-9. 1997.
14. Dimitri A, Cosmanschi A, Imaki J, MR imaging of soft tissue masses of the foot. Semin Musculoskelet Radiol 5:61-150. 2001.
15. Weber J, Bleich H, Kunzeler U, Moser E, Imaging of benign and malignant soft tissue masses of the foot. Eur Radiol 10:1351-1356. 2000.
16. Horn JJ, Hoekstra HJ, Bakker PH, Oldhoff J, Schaffer P, Schraffordt Koops H. The feasibility of limb foot amputation preserved extensions of the knee. J Surg Oncol 50:75-77-81, discussion 81-2. 1992.
17. Cribb GL, Lee DC, Dickinson I. Limb salvage for soft tissue sarcomas of the foot and ankle. J Bone Joint Surg Br 92:06-470. 2010.

We acknowledge Johanna Godoy, DPM and Garrett Desman, MD for their guidance and mentorship.

References

1. Kransdorf MJ. Malignant soft-tissue tumors in a large referral population: distribution of diagnoses by age, sex, and location. AJR Am J Roentgenol 164:129-134, 1995.
2. Bakotic BW, Borkowski P. Primary soft-tissue neoplasms of the foot: the clinicopathologic features of 401 cases. J Foot Ankle Surg 40:28-35, 2001.
3. Pritchard DJ, Soule EH, Taylor WF, Ivins JC. Fibrosarcoma--a clinicopathologic and statistical study of 199 tumors of the soft tissues of the extremities and trunk. Cancer 33:888-897, 1974.
4. Inoue A, Hasegawa T, Ikata T, Hizawa K. Fibrosarcoma of the toe: a destructive lesion of the distal phalanx. Clin Orthop and Relat Res (333):239-244, 1996.
5. Lang JE, Dodd L, Martinez S, Brigman BE. Case reports: acral myxoinflammatory fibroblastic sarcoma: a report of five cases and literature review. Clin Orthop and Relat 445:254-260, 2006.
6. Chen ML, Graf P, Masotto M, Shihabi NS. Fibrosarcoma of the foot masquerading as plantar fasciitis. J Am Podiatr Med Assoc 92:507-511, 2002.
7. Wu KK. Fibrosarcoma of the foot.. J Foot Ankle Surg 26:530-534, 1987.
8. Silvers SH, Weinstein S. Soft tissue fibrosarcoma. A case report and review of the literature. Cutis 29:195-198, 1982.
9. Stout AP. The fibromatoses and fibrosarcoma. Bull Hosp Joint Dis 12:126-130, 1951.
10. De Schepper AM, Bloem JL. Soft tissue tumors: grading, staging, and tissue specific diagnosis. Top Magn Reson Imaging 18:431-444, 2007.
11. Ozdemir HM, Yildiz Y, Yilmaz C, Saglik Y. Tumors of the foot and ankle: analysis of 196 cases. J Foot Ankle Surg 36:403-408, 1997.
12. Blume PA, Niemi WJ, Courtright DJ, Gorecki GA. Fibrosarcoma of the foot: a case presentation and review of the literature. J Foot Ankle Surg 36:51-54, 1997.
13. Sage, RA. Tumor as an indication for amputation in the foot. Clin Podiatr Med Surg 14: 613-619, 1997.
14. Gentili A, Sorenson S, Masih S. MR imaging of soft-tissue masses of the foot. Semin Musculoskelet Radiol 6:141-152, 2002.
15. Waldt S, Rechl H, Rummeny EJ, Woertler K. Imaging of benign and malignant soft tissue masses of the foot. Eur Radiol 13:1125-1136, 2003.
16. Ham SJ, Hoekstra HJ, Eisma WH, Oldhoff J, Schraffordt Koops H. The feasibility of hind foot amputation in selected sarcomas of the foot. J Surg Oncol 50(1):37-41; discussion 41-2, 1992.
17. Cribb GL, Loo SC, Dickinson I. Limb salvage for soft-tissue sarcomas of the foot and ankle. J Bone Joint Surg Br 92:424-429, 2010.