New York College of Podiatric Medicine

Podiatric Medical Review

Volume 24 2015-2016

Case Report: Gangrenous Toes due to Heparin-Induced Thrombocytopenia
Mika Hirano, BS, and Sharon Barlizo, DPM 4

Herpes Zoster as a Rare Cause of Foot Drop: A Literature Review of Case Reports
Sara Stachura, BS, BA, Adenike Sonaike, BS, Lauren Kuenzi, BS 11

The Role of the Windlass Mechanism in the Pathogenesis of Plantar Fasciitis
Djavlon Khakimov, BS, Raymond Morales, BS, Sang Hyub Kim, BA, Diltaj Singh, BS 20

A Literature Review on the Contributing Factors of Second Metatarsal Stress Fractures in Ballet Dancers
Pooja Shah, BA, Maya Robinson, BS, Suganthi Kandasamy, BA, MPH 28

A Systematic Review of Plantar Calcaneonavicular Ligament Reconstruction Techniques And Its Role In Maintaining The Medial Longitudinal Arch
Gireesh Reddy, BS, Ammar Al Rubaiay, BA, Ibn Ansari, BS 36

The Apert Foot: Anatomy and Management
James H. Chung, BS, and Hye Jin Yoo, BS 44

A Systematic Review of Mesenchymal and Amniotic Stem Cell Therapy of Achilles Tendinopathies
Sirisha V. Pokala, BS, Sahar R. Zadeh, BS, 53

A Comparative Review of Minimally Invasive Surgical Treatment Options for Intra-articular Calcaneal Fractures
Danielle Dubois, BS, Mark Rotenstein, BS, Nicholas Salerno, BS 61

The Effects of Foot Orthoses on Achilles Tendinopathy in Runners: A Systematic Review
Maria C. Cifone, BS, and Hye Jin Yoo, BS 75

Low-Level Laser Therapy in Patients with Diabetic Peripheral Neuropathy: A Systematic Literature Review
Sahar Zadeh, BS, Daniel J. Stevens, MLS(ASCP)CM 87

Bone Marrow Edema Syndrome of the Talus: A Case Report and Literature Review
Joseph Waterhouse, BS, and Glenn Weiss, DPM 96

A Review of Current Case Reports Involving Sports-Related Tarsometatarsal (TMT) Joint Complex Pathologies
Alexandra Black, BA, Rosario Saccomanno, BS, Jered M. Stowers, BS, BA 102

A Comparison of Non-Surgical and Surgical Treatment Options in Diabetic Foot Calcaneal Osteomyelitis: A Literature Review
Tyrone Mayorga, BA, Yasmin Sarraf, BS, Dhaval Patel, BS 115

The Efficacy of Maggot Debridement Therapy on Diabetic Foot Ulcers and Its Further Applications
Gabrielle Lee, BA, Paulina Piekarska, BS, Michael Sayad, BS 126

Current Surgical Management of Charcot Neuroarthropathy: A Systematic Qualitative Review
Abigail B. Dunklee, BS, Alisha Poonja, BS, Edwin Zhu, BA, Kenny Luong, BA, Sam Mark, BS 143

Effects of Adjuvants on Onset and Duration of Local Anesthetics Used In Regional Nerve Block
Amara Abid, BS, MSC, Alina Kogan, BS, Nader Ghobrial, BS, MSC 153

A Literature Review of Malignancies Masquerading as Diabetic Ulcers
McKenna Green, BS, Traci Bologna-Jill, BA, Vrunda Dalal, BA, MBS, Disha Shah, BA 162

A Qualitative Review of Surgical Interventions in the Treatment of Jones Fractures: Comparison of Intramedullary Screw Fixation and External Fixation
Kevin Yee, BA, Brittany Hervey, BS, Sang Hyub Kim, BA 170

The Advantages of Dermoscopy in the diagnosis of Acral Melanoma from Other Podiatric Lesions: A Literature Review
HyunJi Boo, BS, Suganthi Khandasamy, BA, MPH, Dhagash Patel, BA, BS, Mansi Patel, BA 180

PMR

STUDENT JOURNAL OF THE NEW YORK COLLEGE OF PODIATRIC MEDICINE



A Note from the Editors



We are delighted to present the twenty-fourth volume of the Podiatric Medical Review (PMR). The efforts from previous Editors-in-Chief Dr. Adrian Wright and Dr. Michael Rossidis have considerably raised the stature and quality of the PMR over the past four years. Since its hiatus four years ago, the journal has grown immensely and has adapted to the evolving field. Our editorial board has expanded to adjust for the record volume of manuscript submissions this year. This year we also implemented an Executive Board mentorship program to cultivate peer editing skills in addition to continuing the monthly research workshops we offer to all students on campus.

Additionally, we would like to extend our gratitude to the senior editor, editors, and peer reviewers for their countless efforts and sacrifices. This year's journal would not have been possible without their hard work and dedication. The peer reviewers are all strongly dedicated to advancing practices to reflect the evolving research and techniques of podiatric medicine.

Though the PMR has continued to evolve year after year, the direction of the PMR still remains committed to serve as a learning platform for podiatric medical students. We are proud of the fact that this journal is run by the student body at the NYCPM campus.

Our hope is that the readers not only learn from the topics presented, but also use this platform as a stepping stone to ignite curiosity that encourages the pursuit of new research. With this new research we hope to obtain the ultimate goal of improving care for our patients.

Danielle Boyle, BS
Editor-in-Chief

Aaron Bradley, BS
Editor-in-Chief

Case Report: Gangrenous Toes due to Heparin-Induced Thrombocytopenia

Mika Hirano, BS and Sharon Barlizo, DPM

Abstract

Introduction
Heparin-induced-thrombocytopenia has been proven in literature to cause distal limb gangrene, although it is uncommon. It is a condition in which heparin exposure causes individuals to form IgG antibodies against platelet factor 4 (PF4) and heparin complex. The antibodies bind to platelets and endothelial receptors, resulting in platelet activation and a limb threatening, paradoxical thrombotic state that can manifest as distal limb gangrene.

Methods
A careful history was taken from the patient when she came into clinic. The patient's past medical notes were reviewed to get further information of her situation. A thorough literature search was done to review other cases of gangrene from heparin-induced thrombocytopenia.

Study Design: Case Report

Results
A 59 year old female patient presented with a reaction to heparin, which was administered following a stroke she suffered during an aortic dissection repair surgery. Subsequent to the reaction, the patient developed gangrene on the right second and fourth toes. Patient was taken off of heparin immediately and she has been taking Coumadin since her discharge. Her clinic notes indicate that she was positive for heparin-induced-thrombocytopenia and spontaneous platelet aggregation at the onset of gangrene. This patient's case of gangrene has not yet resolved after five months and continues to get progressively worse. There have been cases in literature in which the gangrene has resolved without complications, has resulted in amputations, and has been fatal.

Conclusion
It is important for us physicians to recognize and monitor for this disorder as well as identify those individuals at increased risk for heparin-induced-thrombocytopenia in order to reduce the likelihood and severity of associated complications, such as an amputation.

Keywords: Heparin-induced thrombocytopenia, gangrene

Level of Evidence: 4

INTRODUCTION

Heparin is a commonly used intravenous anticoagulant agent worldwide for treatment and prophylaxis of thrombosis, emboli, and stroke. Although severe side effects to this drug are rare, heparin-induced-thrombocytopenia (HIT) is a very dangerous complication characterized by a drop in platelet count and a paradoxical hypercoagulable state[1]. Gangrene at the distal ends of their extremities will occur as a result of the thrombosis. If treatment is not initiated promptly, the body will continue to form thromboses, despite progressively decreasing levels of platelets, leading to life-threatening complications.

There are two types of heparin-induced thrombocytopenia described in literature. Type 1 HIT occurs due to direct activation of platelets by heparin and usually resolves on its own. However, it is mostly implied that the term "heparin-induced thrombocytopenia" is referring to type 2 and the distinction between type 1 and type 2 are historical.[1] Type 2 HIT occurs due to formation of IgG antibodies against platelet factor 4 (PF4) and heparin complex. Platelet factor 4 is a chemokine expressed by megakaryocytes and is released from platelet α-granules when platelets become activated.[1] Cosmi et al. has found that only the IgG antibody is pathological, even though IgM and IgA antibodies are also created. The roles of IgM and IgA antibodies in the development of HIT currently remain uncertain. In addition, Nazi et al. has found that the IgG antibodies need to be present at a certain titer level in order for HIT to occur. When the antibodies bind to the complex, platelets get activated and depleted. This usually occurs about 5-10 days after initial exposure to heparin, or earlier if there was another previous exposure to heparin less than 30 days ago.[2] Although the platelet count decreases, it causes a thrombotic state as the complexes release platelet-derived procoagulant microparticles and activates monocytes and endothelial cells.[1] This is paradoxical because thrombotic state is usually associated with increasing levels of platelets, however in the case of HIT, the thrombotic state is caused by the increased levels of complex formed by IgG antibody, PF4, and heparin. As a result, thrombins may form, which subsequently can cause arterial and venous thrombosis and gangrene.

Fig 1. *Dorsal view of patient's foot*

In this case report, we present a patient who presented to the podiatry clinic with gangrenous toes as a result of heparin-induced-thrombocytopenia, following an aortic dissection repair surgery.

CASE REPORT

A 59 year old female patient with past medical history of hypertension and rheumatoid arthritis presented to the hospital with abdominal pain, nausea, and vomiting. This patient was found to have type A aortic dissection, which involved the superior mesenteric artery. A CT scan of the abdomen and pelvis (CTAP) also revealed occlusion of the celiac artery, left retroperitoneal

Fig 2. *Distal view of patient's foot*

hematoma, and left kidney mass. The patient was given multiple blood transfusions and sent to surgery immediately. During the surgery, she suffered from a stroke, causing left sided neurological deficit. CT angiography showed acute right frontal cortical infarct and dissection flap of the brachiocephalic artery and right common carotid artery. The patient was given heparin and Coumadin postoperatively as a treatment for the stroke and subsequently developed heparin-induced thrombocytopenia. Her records show that she had positive results for Serotonin Release Assay (SRA), which is highly suggestive of HIT. As a result of the HIT, patient's right second and fourth toes became gangrenous. Heparin therapy was stopped at the time of diagnosis with HIT and she was instructed to avoid heparin for life. The patient was then taken to a rehabilitation center for treatment. The patient was discharged 35 days after the surgery on a six month therapy of Coumadin and follow up with hematology, vascular, cardiology, and podiatry clinics.

Three months after discharge, the patient has suffered from an auto-amputation of the distal aspect of her right fourth toe. The patient has also presented with cellulitis of the second and fourth toes, proximal to the gangrenous sites. Patient's condition has continued to digress months after discharge with no signs of improvement. Figures 1, 2,

Fig 3. Dorsal view of patient's foot

and 3 show the patient's right foot following auto-amputation of her fourth toe. Since there have been no signs of improvement for the past few months, it is likely that this patient will endure future auto-amputations or require surgical amputation of affected toes.

DISCUSSION

Heparin-induced thrombocytopenia is a rare but dangerous complication. The incidence of HIT is especially common after cardiac surgery, such as the type that this patient endured. The most likely reason for this is because patients who undergo cardiac surgery are exposed to large amounts of heparin before, during, and after the surgery.[3] As a result, an increased number of antibodies to PF4/heparin complex have been reported in these patients.

Heparin-induced thrombocytopenia should be suspected as soon as there is a decrease in platelet count in patients who have recently been exposed to heparin, especially if the decrease is 40% or more and occurs about 5-10 days after heparin exposure[4]. HIT is diagnosed through enzyme-linked immnosorbent assay (ELISA), which detects the antibodies against PF4/heparin complex, and Serotonin Release Assay (SRA), which measures platelet aggregation caused by heparin.[1] However, due to the overdiagnosis

of HIT made via ELISA test alone and the time consuming process of SRA, a pretest scoring system called the '4 T's' has been created to use with ELISA to predict the SRA value and better diagnose HIT. The overdiagnosis occurs because about 50% of patients undergoing cardiac surgery may be positive for the antibodies but only a small number of those patients actually develop clinical HIT.[2] The consequences of overdiagnosis are substantial as patients may be denied of optimal anticoagulant therapy and critical surgeries in the future when they need them.[5] Therefore, an accurate way to diagnose HIT is critical. Table 1 shows the 4 T's scoring system that was developed by Lo et al. Bayat et al. has confirmed in their study that a high 4 T's score highly corresponds with a high SRA value and vice versa. A score of 6-8 is considered to be high risk (50% probability of HIT), a score of 4-5 is considered to be intermediate risk (10% probability of HIT), and a score of 0-3 is considered to be low risk (less than 1% probability of HIT)[8]. Since detection of IgG antibodies against PF4/heparin does not guarantee that the patient has HIT, using the 4 T's scoring system with the ELISA test would assist to decrease overdiagnosis of HIT and reduce the need to use SRA test.[7,9]

Treatment guidelines for HIT are still undergoing development and it is unclear what treatment this patient received when she was diagnosed with HIT as she was transferred to another facility at the time. When HIT is suspected, the patient is taken off of all forms of heparin, as in this case study. However, since HIT patients are still in

Categories	2 points	1 point	0 point
Thrombocytopenia	Platelet count fall >50% and platelet low point ≥20	Platelet count fall 30-50% or platelet low point 10-19	Platelet count fall <30% or platelet low point < 10
Timing of platelet count fall	Onset clearly on days 5-10 or ≤1 day (if within 30 days of prior heparin exposure)	Onset most likely on days 5-10 fall (ex. missing platelet counts). onset after day 10. Platelet fall <1 day (if within 30-100 days of prior heparin exposure)	Platelet count fall <4 days without recent exposure
Thrombosis or other sequelae	New thrombosis (confirmed), skin necrosis, acute systemic reaction postintravenous unfractionated heparin bolus	Progressive or recurrent thrombosis, non-necrotizing (erythematous) skin lesions, suspected thrombosis (unconfirmed)	None
Other causes for thrombocytopenia	None apparent	Possible	Possible

Table 1. The 4 T's scoring system

a thrombotic state, alternative forms of anticoagulants must be used. The current treatments that are approved for HIT in the United States, are Argatroban and Bivalirudin, which are non-heparin anticoagulants[1]. Argatroban is the main drug that is used in the United States for HIT and it is a synthetic direct thrombin inhibitor derived from L-arginine. It has a short half-life and is usually does not have adverse effects on patients with renal dysfunction.[10] Demma et al. and Tardy-Poncet et al. studied the efficacy of Argatroban in patients in intensive care unit and found it to be a safe and effective treatment with minimal risk of hemorrhage. It is recommended that Argatroban therapy is initiated immediately when HIT is suspected with a 4T score of 4-5 to reduce its complications.[7,10,11] Bivalirudin is also a synthetic direct thrombin inhibitor and is mostly used as anticoagulant for patients with risk of HIT undergoing percutaneous coronary intervention. In recent years, therapeutic plasma exchange has been described as a possible treatment that requires less close monitoring compared to Argatroban and Bivalirudin.[12,13] However, further investigation is still needed to figure out the efficacy of this treatment method.

After platelet count improves to more than 150 x $10^3/\mu l$ with treatment with Argatroban or Bivalirudin, patients are normally switched to warfarin, also known as Coumadin, for continued anticoagulation.[7] However, warfarin should be avoided during acute HIT, when platelet counts are still low, as warfarin can also induce venous limb ischemia or gangrene in HIT patients.[14] Warfarin inhibits the synthesis of natural anticoagulant proteins C and S, in addition to clotting factors II, VII, IX, and X, by blocking vitamin K dependent synthesis of these proteins. Since proteins C and S have shorter half-lives than the clotting factors, warfarin causes a relative hypercoagulable state during the first 24 to 48 hours of warfarin therapy.[14] Therefore, patients who develop HIT must be under careful and knowledgeable care during the initial stage.

It is important to recognize the signs and symptoms of patients with HIT and know the course of treatment, as it is common to see this complication present in the lower extremity. It is estimated that about 50% of the patients who are diagnosed with HIT have a thromboembolic complication, more often in the venous system than in the arterial system.[2] Although HIT may be overdiagnosed in most cases, it is also easy to miss the diagnosis as the drop in platelet count may be thought of as a normal course of surgical recovery. In post-surgical patients, there can be a significant drop in platelets due to dilution, consumption, or direct agglutinating effect of heparin.[6] It is possible that the diagnosis of HIT was made too late for the patient in this study. Since venous thrombosis is often treated with heparin or warfarin,[15] it is possible that the patient in this study was given heparin again or warfarin too early, before the platelet counts went up to normal ranges, if HIT was not diagnosed at the appropriate time.

There are several cases in literature that describe lower extremity gangrene due to HIT with mixed outcomes. In some cases the HIT induced gangrene resolved without complications,[7,15,16,17] while in others the gangrenous areas required amputation.[16,17] There are even reports in the literature in which the complications were fatal[18]. Looking at the literature, it is difficult to decipher exactly which treatment plan would result in no complications and which treatment plan would result in amputations, however, a prompt diagnosis and commencement of treatment seems to be the key to decreased amount of complications. In addition, other risk factors, such as renal insufficiency, seem to affect the outcome negatively.[18] The patient in this study will most likely end up with amputations of her right second and fourth toes in the near future, as the clinical images show that these digits have been gangrenous for an extended period of time, even though her INR levels have fallen into normal range by taking Coumadin. Perhaps a

more extensive study on the risk factors, diagnostic tests, and progression of complications associated with each outcome may help to better construct and understand the diagnosis and treatment guidelines of HIT.

CONCLUSION

Heparin-induced thrombocytopenia is a dangerous disorder that can affect the lower extremity. When lower extremity gangrene occurs in post-surgical patients, HIT should be in the differential diagnosis and treatment plans must be made carefully. Treatment for HIT with Argatroban or Bivalirudin should begin immediately after HIT is suspected using the 4T scoring system and ELISA test should be utilized effectively and efficiently to confirm diagnosis of HIT. Since heparin and warfarin are very dangerous drugs for patients with HIT but also common drugs for gangrenous extremities, it is important to be familiar with the signs and treatment protocols of HIT. Prompt and appropriate care is vital to saving one's limbs, or even life, when managing patients with HIT.

AUTHORS' CONTRIBUTIONS

MH and SB equally conceived the design of the study, performed the database advanced search and evaluated abstracts. SP supplemented the research. The authors designed figures, read, and approved the paper.

STATEMENT OF COMPETING INTERESTS

The authors declare that they have no competing interest.

REFERENCES

1. Cosmi, B. Current management of heparin-induced thrombocytopenia. *Expert Review of Hematology* 2015; 8(6): 837-849.
2. Ortel, T.L. Heparin-induced thrombocytopenia: when a low platelet count is a mandate for anticoagulation. *Hematology American Society Hematology Education Program* 2009; 225-232.
3. Nazi, I., Arnold, D.M., Warkentin, T.E., Smith, J. W., Staibano, P., and Kelton, J.G. Distinguishing between anti-platelet factor 4/ heparin antibodies that can and cannot cause heparin-induced thrombocytopenia. *Journal of Thrombosis and Haemostasis* 2015; 13: 1900-1907.
4. Selleng, S., Selleng, K., Wollert, H.G., Muellejans, B., Lietz, T., Warkentins, T.E., Greinacher, A. Heparin-induced thrombocytopenia in patients requiring prolonged intensive care unit treatment after cardiopulmonary bypass. *Journal of Thrombosis and Haemostasis* 2007; 6(3): 428-435.
5. Rice, L. There Is No Such Thing as a "Positive" Antibody Test. *Chest* 2015; 148(1): 1-3.
6. Lo, G.K., Juhl D., Warkentin, T.E., Sigouin, C.S., Eichler, P., and Greinacher, A. Evaluation of pretest clinical score (4 T's) for the diagnosis of heparin-induced thrombocytopenia in two clinical settings. *Journal of Thrombosis and Haemostasis* 2006; 4: 759-765.
7. Bayat, M., Macedo, F.Y.B., Ansari, A.S., Bracey, A.W., Akinyele, S., and Salazar, M. Evaluation of clinical and laboratory data for early diagnosis of heparin-induced thrombocytopenia. *American Journal of Health-System Pharmacy* 2015; 72: 1649-1655.
8. Khanal, R., Karmacharya, P., Forman, D.A. Heparin-induced thrombocytopenia following coronary artery bypass grafting: a diagnostic dilemma. *Journal of Community Hospital Internal Medicine Perspectives* 2015; 5(5).

9. Raschke, R.A., Curry, S.C., Warkentin, T.E., Gerkin, R.D. Improving Clinical Interpretation of the Anti-Platelet Factor 4/ Heparin Enzyme-Linked Immuosorbent Assay for the Diagnosis of Heparin-Induced Thrombocytopenia Through the Use of Receiver Operating Characteristic Analysis, Stratum-Specific Likelihood Ratios, and Bayes Theorem. *Chest* 2013; 144(4): 1269-1275.

10. Demma, L.J., Paciullo, C.A., Levy, J.H. Recognition of heparin-induced thrombocytopenia and initiation of argatroban therapy after cardiothoracic surgery in the intensive care unit. *Journal of Thoracic Cardiovascular Surgery* 2012; 143(5): 1213-1218.

11. Tardy-Poncet, B., Nguyen P., Thiranos, J., Morange, P., Biron-Andreani, C., Gruel, Y., Morel, J., Wynckel, A., Grunebaum, L., Villacorta-Torres, J., Grosjean, S., and Maistre, E. Argatroban in the management of heparin-induced thrombocytopenia: a multicenter clinical trial. *Critical Care* 2015; 19: 396-406.

12. Chaudhary, R.K., Khanal, N., Giri, S., Pathak R., Bhatt, V.R. Emerging therapy options in heparin-induced thrombocytopenia. *Cardiovascular & Hematological Agents in Medicinal Chemistry* 2014; 12(1): 50-58.

13. Schell, A.M., Petras, M., Szczepiorkowski, Z.M., Ornstein, D.L. Refractory heparin induced thrombocytopenia with thrombosis (HITT) treated with therapeutic plasma exchange and rituximab as adjuvant therapy. *Transfusion and Apheresis Science* 2013; 49(2): 185-188.

14. Hostetler, S.G., Sopkovich, J., Dean S., and Zirwas, M. Warfarin-induced Venous Limb Gangrene. The Journal of Clinical and Aesthetic Dermatology. (2012) 5(111): 38-42.

15. Rozati, H., Shah, S.P., Peng, Y.Y. Lower limb gangrene postcardiac surgery. *BMJ Case Reports* 2013; 1-4.

16. Smythe, M.A., Warkentin, T.E., Stephens, J.L., Zakalik, D., and Mattson, J.C. Venous Limb Gangrene During Overlapping Therapy With Warfarin and a Direct Thrombin Inhibitor for Immune Heparin-Induced Thrombocytopenia. *American Journal of Hematology* 2002; 71: 50-52.

17. Warkentin, T.E., Elavathil, L.J., Haywar, C.P.M., Johnson, M.A., Russett, J.I., Kelton, J.G. The Pathogenesis of Venous Limb Gangrene Associated with Heparin-Induced Thrombocytopenia. *Annals of Internal Medicine* 1997; 127(9): 804-812.

18. Nazli, Y., Colak, N., Dermicelik, B., Alpay, M.F., Cakir, O., and Cagli, K. A fatal complication after repair of post-infarction ventricular septal rupture: heparin-induced thrombocytopenia with thrombosis. *Cardiovascular Journal of Africa* 2015; 26(3): e11-15.

Herpes Zoster as a Rare Cause of Foot Drop: A Literature Review of Case Reports

Sara Stachura, BS, BA, Adenike Sonaike, BS, and Lauren Kuenzi, BS

Abstract

Introduction
Varicella-zoster virus (VZV) can be reactivated as the disease herpes zoster. Rarely, herpes zoster causes paresis, which can present clinically as foot drop when the L3-L5 myotomes are involved. The purpose of this paper is to compare case reports describing patients who suffered from foot drop caused by herpes zoster.

Study Design: Qualitative Systematic Review of Literature

Methods
The authors performed a systematic search utilizing PubMed, including keywords such as “foot drop”, “herpes zoster”, “leg paresis”, “leg paralysis”, and “peroneal nerve”. A manual search of Google Scholar was also performed. Inclusion criteria were articles written in the English language, case reports, paresis of dorsiflexor muscles of the foot, diagnosis of herpes zoster, and articles written after the year 2000. Exclusion criteria eliminated articles describing lower extremity pathology without foot drop and VZV.

Results
Fifteen case reports were chosen describing nineteen patients. The average age of patients was 63 years old. All patients developed a vesicular rash. Ten patients developed the rash before motor paresis, five patients developed the rash after motor paresis, and four cases did not include when the rash appeared. Fifteen patients suffered unilateral weakness and four patients suffered bilateral weakness. Treatments included, but were not limited to, antiviral medication, pain management, physical therapy, and foot-ankle orthosis. Eight patients showed complete improvement in muscle strength, three improved with residual weakness, seven saw no improvement, and one died of respiratory infection before improvement could be assessed.

Discussion and Conclusions
The vesicular rash did not always appear before paresis, delaying the diagnosis and treatment of herpes zoster. Patient history and neurological exam were important contributors to diagnosis. Various methods were used to treat herpes zoster, including physical therapy, which may be useful for motor improvement. Clinicians should be aware of the differential diagnosis of herpes zoster as a cause of foot drop, especially in patients who have not received the chickenpox or shingles vaccines. Earlier diagnosis and appropriate treatment of herpes zoster may lead to a better outcome for the patient.

Key Words: herpes zoster, shingles, foot drop, paresis

Level of Evidence: *4*

INTRODUCTION

Varicella-zoster virus (VZV) causes the diseases varicella and herpes zoster, commonly known as chickenpox and shingles, respectively.[1] Humans are the only reservoir for this virus and it is spread between individuals via air transmission.[2] VZV is generally contracted in childhood and manifests as the disease varicella. A distinguishing symptom of varicella is an exanthematous vesicular rash seen on the body.[3] Other symptoms may include cerebellitis, encephalitis, and myelitis, which can occur in up to 0.5 – 1.5 out of every 1,000 cases of chickenpox.[1] Varicella tends to resolve within a few weeks without treatment, but antivirals such as acyclovir may be given for more severe symptoms.[4,1] Studies have shown that the varicella vaccine has been 100% successful in the prevention of these severe symptoms.[5]

After symptoms of varicella resolve, VZV remains latent within the dorsal root ganglion, autonomic ganglia, and cranial nerve ganglia.[6] Viral replication is suppressed by cell-mediated immunity. When the cell-mediated immunity decreases, reactivation of VZV can occur.[2] This causes the disease herpes zoster, in which the virus travels along axons to the skin, causing symptoms in a dermatomal distribution. It has been reported that about 20% of people experience herpes zoster at least once.[4] Herpes zoster most commonly affects the thoracic dermatome, followed by the cranial dermatome. Lumbar and sacral dermatomes are least affected.[7]

There are four clinical phases of herpes zoster, although in some instances patients affected may not experience every phase or may experience the phases in a different order. The first phase is known as the prodromic phase. Symptoms may include fever, headache, malaise, pruritus, and burning sensations. Next is the acute phase, which generally begins 1-5 days after the prodromic phase. A vesicular rash appears in one or more dermatomes of a sensory nerve, and is generally unilateral. The vesicles of the rash contain VZV, and are contagious until they crust. Pain may also accompany this phase and the quality of the pain may vary from case to case. The third, or sub-acute phase, generally begins 30-90 days after the onset of the acute phase, followed by the fourth, chronic phase. The chronic phase involves post-herpetic neuralgia, characterized by moderate to severe pain after the vesicular rash has healed, which may last months or years.[2]

Complications associated with herpes zoster occur in 13-40% of cases, usually occurring in immunocompromised individuals.[2] The most common complications include disseminated herpes zoster, herpes zoster opthalmicus, encephalitis, Bell's palsy, and Ramsay Hunt syndrome.[2] Treatment of herpes zoster may include prevention of viral replication with antiviral medications; pain management with analgesics, corticosteroids, or neural blockades; and prevention of further complications. A live attenuated vaccine is used to prevent or decrease severity of herpes zoster and associated complications.[7]

One of the more rare complications of herpes zoster is segmental zoster motor paresis. This results when motor neurons become involved in the viral reactivation along with the sensory neurons. Paresis may result from damage of the ventral root, plexus, or peripheral nerve. Severity of the damage seems to increase with age. When segmental zoster motor paresis occurs in the lower limb, it may cause foot drop.[8] The term foot drop describes dorsiflexor muscle weakness in the foot. There are many causes of foot drop, including damage to motor neurons, L4 or L5 nerve roots, lumbosacral plexus, sciatic nerve, and fibular nerve.[9] This weakness of the dorsiflexor muscles results in gait abnormalities, which includes slapping and steppage gaits.[9,10] This disruption of gait may lead to falling, which can result in injury.[9]

Figure 1. Scars on the left lower limb and foot drop due to herpes zoster.[22]

The purpose of this paper is to review and compare case reports describing patients who suffered from foot drop caused by herpes zoster. Though rare, this should be considered in the differential diagnosis, especially in elderly patients presenting with a vesicular rash who have not received the chickenpox or shingles vaccines.

METHODS

The authors performed a systematic search utilizing PubMed, entering keywords "'foot drop' AND 'Herpes'". The search yielded seven articles, all of which were selected. Keywords "'peroneal nerve' AND 'Herpes'" yielded one selected result. Keywords "leg paresis herpes zoster" yielded one selected result. Keywords "leg paralysis herpes zoster" yielded two selected results. Additional searches on PubMed, including "'foot drop' AND 'Varicella'", "'fibular nerve' AND 'Varicella'", "'fibular nerve' AND 'Herpes'", and "'peroneal nerve' AND 'Varicella'", yielded no unrepeated selectable results. All of the stated keywords were entered into Biomed Central, Cochrane databases, and JAPMA, yielding no selected articles. A manual search of Google Scholar yielded four selected articles. Inclusion criteria required articles written in the English language, case reports, paralysis of dorsiflexor muscles of the foot, diagnosis of herpes zoster, and articles written after the year 2000. Exclusion criteria eliminated articles describing lower extremity pathology without foot drop and VZV. Overall, fifteen case reports were chosen describing nineteen patients diagnosed with herpes zoster as the cause of paresis of dorsiflexor muscles of the foot.

RESULTS

Presentation

Fifteen case studies were selected based on the inclusion and exclusion criteria.[3,10-23] Twelve of the reviewed studies were written after 2008.[3,10,12-20,22] Two case studies described two patients each and one case study described three patients [10,11,23] The other articles were based on one patient each.[3,10,12-22] There were a total of twelve male and seven female patients. The patients were between 40 and 86 years old, except for one individual who was 21 years old. The average age, including the 21 year old patient, was 63 years old. The vaccination status was not provided for any of the patients. Nine patients suffered from weakness or paralysis of the right foot, four of the left foot, and four had bilateral weakness or paralysis, two of which had more severe weakness on the right side than left.[3,10-23] Two cases did not specify the afflicted side.[23] All of the patients developed the vesicular rash characteristic of shingles. Ten patients developed the rash between four days and six weeks prior to motor weakness, five patients developed the rash between 2 days and 1 month after lower leg weakness, and four case studies did not provide the order of

Leg Affected by Foot Drop	
Right leg	9
Left leg	4
Bilateral	4
Non-specified	2

Table 1. Data suggests that the right leg is more often affected by paresis resulting from herpes zoster.

Onset of Rash vs Foot Drop	
Rash first	10
Foot drop first	5
Non-specified order	4

Table 2. Five patients reported weakness prior to herpetic rash.

Dermatome Affected by Rash	
Leg with foot drop	15
Thoracic dermatomes	3
Lumbosacral spine	1

Table 3. Majority of patients saw herpetic rash corresponding to area of paresis.

the appearance of the rash in relation to onset of foot drop.[3,10-23]

Fifteen of the patients developed the vesicular rash on the lower limb on the same side as the muscular weakness.[3,10,12,14-19,21-23] One patient developed the rash on the lumbosacral spine.[13] Three patients developed rashes over thoracic dermatomes, all of which were immunocompromised and presented with bilateral limb weakness or paralysis.[11,20] Nine patients had diminished or absent deep tendon reflexes on the affected lower limb, two of which had absent deep tendon reflexes in the thoracic myotome below the thoracic dermatome afflicted with the rash. Presence or absence of deep tendon reflexes did not appear to correspond with treatment outcome.[3,10-13,15,19,22] Fourteen patients were noted to have pain of varying severity, of which four cases specified lumbar pain, four described lower limb pain on the affected side, and two described pain in the gluteal region.[3,10,13,15-19,21-23] Twelve patients were specified to have pain as one of the first symptoms. Pain corresponded with the dermatome affected with the rash.[3,10,13,16-19,21-23] Seven patients were described to have altered or reduced sensation which also corresponded with the dermatome affected with the rash.[3,10,12,13,15,17,21] Myotomes most commonly involved were between L2 and S1, with an increased incidence between L4 and L5.[3,10-23]

Previous illnesses

Five of the patients were previously healthy before the onset of the disease of interest, three of which were elderly and may have had immunocompromised status due to age.[10,12,14,17,23] One previously healthy 42 year old man was affected.[14] One 74 year old male only suffered from mild ischemic heart disease prior to the illness of interest.[10] A 46 year old female had no past medical history other than having smoker status.[17] The other thirteen patients were all immunocompromised in one or multiple ways, including HIV positive, chronic lymphocytic leukemia, mantle cell lymphoma, steroid therapy for various types of arthritis, systemic lupus erythematosus, chronic myelogenous leukemia, liver cirrhosis resulting in transplant, chronic renal insufficiency, chronic respiratory failure, diabetes mellitus, anemia secondary to a bleeding duodenal ulcer, atrial fibrillation, and joint replacements.[3,11,13,15,16,18-22] None of the patients had previously suffered a herpes zoster outbreak except for one 79 year old female who had three prior cases of herpes zoster as well as two cases of Bell's palsy.[3,10-23]

Diagnostic tests

All of the patients had a physical exam and a neurological exam, which included muscle strength tests and reflex tests.[3,10-23] Six of the case reports noted serological tests for pathogens such as HIV, syphilis, Lyme disease, West Nile virus, cryptococcal antigen, and acid-fast bacilli.[3,10-12,14,23] Eleven patients were reported to have blood tests or standard laboratory procedures, including cell counts, serum chemistry, and cultures.[3,11,12,14,17-20,23] Nine of the patients were noted to have lumbar punctures and cerebral spinal fluid analysis.[3,11,12,16,18,22,23] Four patients were tested for VZV antibody titers, all of

which were elevated.[14,16,21,23] Fourteen of the patients underwent electrophysiological examinations, including tests such as needle electromyography and nerve conduction studies.[3,10,12-17,20-23] Ten patients had magnetic resonance imaging (MRI) performed on the spine, all of which were normal or showed no pathology which could explain the present symptoms.[3,10-14,17,19,21,22] Computed tomography scans were done on five patients, one of which had received an MRI as well, another of which received X-ray studies as well, and one which underwent radiculography.[11,18,23] Polymerase chain reaction analysis was mentioned for five patients.[3,16,18,23] Other tests, mentioned less frequently, include urinary analysis, videofluoroscopic swallowing study, investigations for malignancy, histopathologic analysis, and electroencephalogram.[3,11,16,19,20,23] One study based the diagnosis on clinical findings alone without further investigation.[10]

Treatments and Outcomes

Fourteen of the patients were treated with antiviral medication, including acyclovir, valcyclovir, and famcyclovir.[3,10-12,16-23] Eight of these patients went through physical therapy as well.[10-12,17,20-22] Of the six patients who received antiviral therapy alone, four saw no improvement in muscle function, one was described as walking independently without mention of residual weakness, and one patient died of a respiratory infection before the level of recovery could be assessed.[3,16,18,19,23] Of the eight patients who were treated with antiviral medication and physical therapy, five saw complete recovery of muscle strength (one of which received a foot orthosis as well), one saw improvement of muscle strength with residual weakness, and two saw no improvement of foot drop after treatment.[10-12,17,20-22] Three patients were treated with physical therapy without antiviral medication, two of which received a foot orthosis as well. The patient who received physical therapy alone made a complete recovery, one patient who received physical therapy and a foot orthosis saw improved muscle strength, and the other saw minimal improvement.[13-15] One patient was treated with a foot orthosis alone and made a complete recovery.[10] Two patients treated with steroid therapy on top of various other treatments saw no improvement of foot drop.[16,21] Two patients were treated with low voltage electrostimulation to prevent atrophy along with other treatments, one of which made a full recovery and the other still had foot drop after treatment.[17,21] Eight patients were treated for pain along with the other therapies. Common pain medications included gabapentin and amitriptyline, one patient was treated with pregabalin, one with hydrocodone and lidocaine patches, and one received an epidural block.[3,11,13,15-17,22,23]

Effectiveness of Treatment in Patient Recovery from Foot Drop

Treatment	Utilized	Effective	Ineffective	Partially	Unknown
Antiviral Medication	6	0	4	1	1
Antiviral & PT	8	5	2	1	0
PT	1	1	0	0	0
PT & Foot Orthosis	2	0	1	1	0
Foot Drop Splint	1	1	0	0	0

Table 4. More patients improved with antiviral medication and physical therapy (PT) as opposed to antiviral medication alone.

DISCUSSION

Herpes zoster results from the reactivation of VZV due to decreased cell mediated immunity, which may occur in elderly or immunocompromised individuals.[6] In this study, thirteen patients were immunocompromised, while four were immunocompetent and elderly. These patients were all within the population at risk for developing herpes zoster. When herpes zoster occurs in healthy individuals, it is believed to be the result of contracting varicella before the age of four.[6] Two healthy adults were affected in this study. The age at which varicella was contracted in these two individuals is unknown, so it cannot be determined whether the age of contraction could explain development of herpes zoster in these patients.

In the disease history of herpes zoster, pain and sensory abnormalities tend to precede formation of the vesicular rash.[4] In this study, twelve cases were reported to have experienced pain as one of the first symptoms, following the standard disease history described in the literature. Many of the case reports noted symptoms at the time of examination without a timeline of when symptoms appeared, so it cannot be speculated whether these patients followed the standard progression of the disease. It is noted that not all patients experience every phase of herpes zoster, and phases may be experienced out of order.[2] The pain and altered sensation did tend to correspond to the dermatome(s) in which the rash appeared, which follows the description of herpes zoster in the literature.[4]

All of the patients in this study developed the characteristic vesicular rash associated with herpes zoster. This rash usually presents unilaterally and does not cross the midline.[4] This was seen in fifteen patients who developed the rash on the lower limb affected with muscle weakness. Three patients developed the rash over thoracic dermatomes, all of which were severely immunocompromised and presented with bilateral limb weakness or paralysis. This may imply that a thoracic rash associated with lower limb motor involvement is more likely to affect both limbs, and occurs mainly in very severe cases.

In this review, more patients experienced symptoms in the right foot than left. Affected myotomes were between L2 and S1, with L4 and L5 most commonly involved. This differs from a previous study performed by Molloy and Goodwill, which reported equal frequency of right and left limb involvement, and L3 and L4 dermatomes most commonly affected.[24] In the current review, ten patients developed the rash prior to lower leg paresis, five patients developed the rash after lower leg paresis, and four case studies did not provide the order of these symptoms. This differs from the Molloy and Goodwill study, in which no patients developed motor weakness before the rash.[24] This implies that the rash more commonly occurs before the onset of weakness, but the rash may appear after weakness develops. This presentation delays diagnosis, which may impact treatment outcome.

The most useful information required for the diagnosis of herpes zoster is patient history, including details of pain, rash, and possible immunosuppression.[4] Neurological and electrophysiological exams are useful to characterize motor deficits in the patients and determine if it follows the pattern of a herpes zoster outbreak.[12] Imaging studies can rule out stenosis or nerve compression as the cause of weakness, and may also show enhanced ganglia and nerve roots affected by herpes zoster.[10,6] Blood and cerebral spinal fluid tests can directly test for VZV DNA or antibodies in order to support the diagnosis of herpes zoster as well as to rule out other infectious agents which could be responsible for the disease symptoms.[23] In this study, all cases were evaluated using multiple tests in order to confirm herpes

zoster as the diagnosis except one, which based the diagnosis on clinical findings alone. In all cases, the disease course and results of further testing appeared to support the diagnosis of herpes zoster as the cause of foot drop.

There are multiple treatment plans for patients suffering motor loss due to herpes zoster. Antiviral medications are used to prevent viral replication in order to reduce severity of disease and increase rate of healing.[7] It has been observed that axonal damage is less severe in patients who received antiviral therapy.[8] In this study, patients treated with antivirals alone continued to have motor loss. More patients saw improvement of muscle weakness when treated with antivirals and physical therapy as opposed to antivirals alone. Though antivirals may improve pain and vesicle healing, this study implies that physical therapy is an important component to regain muscle function.[4]

Pain management is based on the individual case and may include analgesics, corticosteroids, or neural blockades.[7] The two patients treated with steroid therapy saw no improvement of muscle function, implying that reduction of inflammation did not improve motor nerve healing in these cases. Two patients were treated with low voltage electrostimulation to prevent atrophy along with other treatments, one of which saw improvement. There is not enough data to speculate whether this treatment is truly beneficial to prevent motor loss. A foot orthosis may also be beneficial to assist the patient in gait.[13]

CONCLUSION

Herpes zoster is often diagnosed based on clinical findings.[10] When motor paresis is involved, excluding other causes of disease with laboratory tests can be used to support the diagnosis of herpes zoster.[11] Electrophysiologic studies are useful as diagnostic tests, but also may indicate prognosis.[23] This is because recovery may be based on the extent of axonal damage and ability to regenerate.[17] The live attenuated vaccine is used to prevent or decrease severity of herpes zoster and associated complications.[7] It also may be useful in preventing recurrence, which may be especially important in patients who experienced severe symptoms. Early diagnosis and treatment may result in a better outcome for the patient, so clinicians should be aware of this phenomenon and the variable presentations of herpes zoster motor paresis.[10] Much of the literature describing herpes zoster motor paresis is outdated or based on data with a small sample size. The current population would benefit from epidemiologic studies utilizing hospital records in order to characterize this disease, prevalence, and the most successful treatment options.

AUTHORS' CONTRIBUTIONS

All authors participated equally in conception of the research topic, literature review, and extraction of data. LK drafted the introduction, SS drafted the methods, results, and conclusion, AS drafted the discussion. All authors reviewed and approved the final submission.

STATEMENT OF COMPETING INTERESTS

The authors declare that they have no competing interest.

---

*All figures were reprinted with permission from the citied sources. Copyright clearance ID 3553370614879 granted on January 20, 2016, and written consent from the Editor of Revista Brasileira de Neurology granted on December 18, 2015. All special Rights holder Terms and Conditions upheld.

REFERENCES

1. Grahn A, Studahl M. Varicella-zoster virus infections of the central nervous system – Prognosis, diagnostics and treatment. *J Infect.* 2015;71(3): 281-293. doi: 10.1016/j.jinf.2015.06.004. [doi].
2. Gabutti G, Valente N, Sulcaj N, Stefanati A. Evaluation of efficacy and effectiveness of live attenuated zoster vaccine. *J Prev Med Hyg.* 2014;55(4): 130-136.
3. Claflin B, Thomas M, Wilson AJ. Polyradiculopathy and herpes zoster. *Proc (Bayl Univ Med Cent)*. 2009;22(3): 223-225.
4. Van Wijck AJM, Wallace M, Mekhail N, van Kleef M. 17. Herpes Zoster and Post-Herpetic Neuralgia. *Pain Pract*. 2011;11(1): 88-97. doi: 10.1111/j.1533-2500.2010.00428.x. [doi].
5. Seward JF, Marin M, Vázquez M. Varicella Vaccine Effectiveness in the US Vaccination Program: A Review. *J Infect Dis*. 2008;197(Supplement 2): S82-S89. doi: 10.1086/522145. [doi].
6. Nagel MA, Gilden D. Neurological complications of varicella zoster virus reactivation. *Curr Opin Neurol*. 2014;27(3): 356-360. doi: 10.1097/WCO.0000000000000092. [doi].
7. Jeon YH. Herpes Zoster and Postherpetic Neuralgia: Practical Consideration for Prevention and Treatment. *Korean J Pain*. 2015;28(3): 177-184. doi: 10.3344/kjp.2015.28.3.177. [doi].
8. Mondelli M, Romano C, Rossi S, Cioni R. Herpes zoster of the head and limbs: electroneuromyographic and clinical findings in 158 consecutive cases. *Arch Phys Med Rehabil*. 2002;83(9): 1215-1221. doi: 10.1053/apmr.2002.33989. [doi].
9. Stewart JD. Foot drop: where, why and what to do? *Pract Neurol*. 2008;8: 158-169. doi: 10.1136/jnnp.2008.149393. [doi].
10. Sprenger De Rover WB, Alazzawi S, Hallam PJ, Hutchinson R, Di Mascio L. Herpes Zoster Virus: An Unusual but Potentially Treatable Cause of Sciatica and Foot Drop. *Orthopedics*. 2011;34(12): 965-968. doi: 10.3928/01477447-20111021-26. [doi].
11. Amayo EO, Kwasa TO, Otieno CF. Herpes zoster myelitis: report of two cases. *East Afr Med J*. 2002;79(5): 279-280. doi: 10.4314/eamj.v79i5.8870. [doi].
12. Boylu E, Domac FM, Saracoglu M. Common peroneal and tibial nerve paralysis secondary to herpes zoster infection: a case report. *Electromyogr Clin Neurophysiol*. 2010;50(7-8): 322-325.
13. Conliffe TD, Dholakia M, Broyer Z. Herpes Zoster Radiculopathy Treated with Fluoroscopically-Guided Selective Nerve Root Injection. *Pain Physician*. 2009;12(5): 851-853.
14. Gopal KV, Sarvani D, Krishnam RPV, Rao GR, Venkateswarlu K. Herpes zoster motor neuropathy: a clinical and electrophysiology study. *Indian J Dermatol Venereol Leprol*. 2010;76(5): 569-571. doi: 10.4103/0378-6323.69054. [doi].
15. Khan A, Camilleri J. Motor radiculopathy. *BMJ Case Rep*. 2012;9(1). doi: 10.1136/bcr-2012-006246. [doi].
16. Leo AM, Kasper DA, Saxena A. Atypical herpes zoster infection preceded by sciatica and foot drop. *Arch Dermatol*. 2009;145(8): 954-955. doi: 10.1001/archdermatol.2009.168. [doi].
17. Mourgela S, Sakellaropoulos A, Tavouxoglou K. A Case of Recurrent Herpes Zoster Leg Paresis Without Rash. *J Pain Palliat Care Pharmacother*. 2010;24(1): 33-38. doi: 10.3109/15360280903583115. [doi].
18. Nicoli P, Bosa M, Rotolo A, Cilloni D, Saglio G. Herpetic leg paralysis and abdominal ileus in a patient with idiopathic myelofibrosis. *Int J Emerg Med.* 2009;4(1): 65-66. doi: 10.1007/s11739-008-0173-8. [doi].
19. Omidi-Kashani F, Mohammad Ata Sharifi Dalooei S. Impending Discectomy in a Patient with Zoster Induced Sciatica; An Instructive Case Report. *American Journal of Medial Case Reports.* 2014;2(1): 27-29. doi: 10.12691/ajmcr-2-1-9. [doi].

20. Seo DH, Lee SJ, Hyun JK, Kim TU. A Case of Herpes Zoster Peripheral Polyneuropathy Manifested by Foot Drop in Chronic Myeloid Leukemia. *Ann Rehabil Med*. 2012;36(5): 724-728. doi: 10.5535/arm.2012.36.5.724. [doi].
21. Takahama H, Tsukahara N, Hirayama M, Ito S, Sakuramoto C. Isolated double herpes zoster paresis involving the left facial nerve and the right peroneal nerve following disseminated herpes zoster. *J Dermatol*. 2007;34(5): 349-352. doi: 10.1111/j.1346-8138.2007.00286.x. [doi].
22. Vale TC, Leite AF, Dornas de Oliveira L, Gomez RS, Teixeira AL. Zoster Paresis: An Underrecognized Cause of Acute Monoparesis. *Rev Bras Neurol*. 2011;47(4): 31-32.
23. Wendling D, Langlois S, Lohse A, Toussirot E, Michel F. Herpes zoster sciatica with paresis preceding the skin lesions. Three case-reports. *Joint Bone Spine*. 2004;71(6): 588-591. doi: 10.1016/j.jbspin.2003.12.002. [doi].
24. Molloy MG, Goodwill CJ. Herpes zoster and lower motor neurone paresis. *Rheumatol Rehabil*. 1979;18(3):170-173.

The Role of the Windlass Mechanism in the Pathogenesis of Plantar Fasciitis

Djavlon Khakimov, BS, Raymond Morales, BS, Sang Hyub Kim, BA and Diltaj Singh, BS

Abstract

Introduction
One in every ten runners ends up developing plantar fasciitis (PF) in their lifetime due to faulty biomechanics. Although there have been many studies aimed at identifying the causative factors for this condition, only a few studies focused on the "windlass mechanism" as the primary contributor. Hicks et al. described the "windlass mechanism" as irresistible arch-raising mechanism that supinates the foot by stabilizing the medial longitudinal arch (MLA), which is done by dorsiflexion at the metatarsophalangeal joint (MTPJ). During dorsiflexion at the MTPJ, the plantar fascia or plantar aponeurosis (PA) winds around the metatarsal head and reduces the distance between the calcaneus and metatarsals, thus tensing up the fascial band and raising the MLA upward. Inefficient "windlass mechanism" is associated with the development of PF. This paper examines the role of the "windlass mechanism" as a causative agent in PF and how biomechanical principles can be used to treat this condition.

Study design: Systematic review of literature

Methods
A comprehensive literature search was conducted utilizing the online search engine of PubMed to find articles that contained the MeSH terms "plantar fasciitis" and "windlass mechanism". When these MeSH terms were combined with the Boolean operator "AND", the search yielded a total of 29 results. Ten articles were selected based on the inclusion criteria relevant to the contribution of the "windlass mechanism" to the development of PF and the biomechanical approach to treat PF. The search excluded studies involving the "windlass mechanism" not related to the foot and studies that did not focus on the biomechanical causes of PF. A manual search yielded 4 additional publications for a total review of 14 articles.

Results
Fourteen articles were obtained that focused on the biomechanical aspects and etiology of PF in order to attempt to treat this condition based on purely biomechanical principles.

Conclusion
The biomechanical approach has been shown to be very effective in the rehabilitation of PF because this approach addresses the specific factors that cause the pathology of the PA. Due to the repetitive high stress load experienced by the medial slip of the PA, the proximal attachment of the fascia on the calcaneus pulls the periosteum, creating microtrauma. Because the medial fascicular slip receives the greatest load during the action of the "windlass mechanism", rehabilitation therapy should be aimed at alleviating this stress to prevent further damage.

Key Words: Plantar Fasciitis (PF), Plantar Aponeurosis (PA), Medial Longitudinal Arch (MLA), Metatarsophalangeal Joint (MTPJ), Subtalar Joint (STJ), "Windlass Mechanism"

Level of Evidence: 4

INTRODUCTION

Plantar fasciitis (PF) is a common pathology encountered in everyday podiatric practices. In order to properly treat PF, a clinician must be well versed in his knowledge of the biomechanical causes of PF.[1] There are many potential etiologies of PF, however, the "windlass mechanism" has not been investigated extensively in the literature as the primary causative agent of PF.

Lemelle et al. characterized PF as inflammation and pain due to a simple strain or tear compromising the plantar fascia or plantar aponeurosis (PA) at the medial calcaneal tubercle insertion. PF can lead to the development of heel spurs (both painful and non-painful) and, more significantly, point tenderness at the insertion.[2] One of the more common complaints revealed by patients is pain after long periods of non-weight bearing due to fluid build-up overnight.[3] Clinically, PF can present as either a unilateral or bilateral issue with the latter being associated with systemic diseases.[2] All of these symptoms coincide with the PA function of force absorption at the midtarsal joint and stabilization of the medial longitudinal arch (MLA).[2]

The intrinsic plantar muscles and the superficial PA make up the net effect of hindfoot biomechanics at the calcaneal insertion. Pathology to these two structures influences the occurance of PF.[4] As described by Moore et al., the PA is situated anatomically from its proximal end at the medial calcaneal tubercle and is distally divided into five fascicles that blend into the fibrous digital sheaths that cover up the distal ends of the flexor tendons. The PA at the distal end is further reinforced by merging with the superficial transverse metatarsal ligament, which is apropos with the biomechanical concept of the "windlass mechanism".[5] The static nature of the PA is what strictly constitutes the windlass effect as coined by Hicks et al.[6]

Hicks et al. describes the windlass effect as purely mechanical in nature and as irresistible arch-raising mechanism that supinates the foot by stabilizing the MLA. This is done by dorsiflexion of the toes which pulls the PA distally, thus tensing up the band and raising the arch upward.[4] Increased PA stiffness resulting from passive metatarsophalangeal joint (MTPJ) dorsiflexion can help convert the foot into a rigid lever, which assists with propulsion at the toe-off phase of gait.[7] Furthermore, the PA functions as a tie-beam that effectively dissipates the tensile forces while maintaining arch integrity.[8] Few studies have examined the "windlass mechanism" as the primary contributory agent in PF. Understanding of biomechanics of the "windlass mechanism" can illuminate alternative treatment options for PF.

METHODS

An extensive literature search was performed utilizing the PubMed database, which focused on finding articles that included the MeSH terms "plantar fasciitis" and "windlass mechanism". Combining these MeSH terms with the Boolean operator "AND" yielded 29 results. The following inclusion criteria were used to narrow down the search: the contribution of the "windlass mechanism" to the development of PF and the biomechanical approach to treat PF. The exclusion criteria were as follows: studies involving the "windlass mechanism" not related to the foot, studies that did not focus on the biomechanical cause of PF, and articles published prior to 1995. Overall, the electronic search yielded 10 relevant articles that met the specific requirements. In addition, 4 more publications were selected via a manual search to yield a total of 14 articles for the final literature review.

Study:	Methods:	Results:
Caravaggi et al.	Inverse kinematics analysis on three healthy volunteers.	Tension loads by greatest to least: medial slip (27%), central slip (19%), lateral slip (15%). The “windlass mechanism” contributes to the maximum elongation and tension of PA at the push-off phase.
Bolga and Malone	Review of literature of the “windlass mechanism” model as a way to provide effective treatment modalities for PF.	Excessive forefoot varus can lead to increased stress on the PA due to pronation compensation by the STJ. A 6° wedge was placed under the lateral aspect of the forefoot to control overpronation.
Kappel-Bargas et al.	10 male and 10 female subjects with a mean age of 29 years and without any structural abnormalities were used to record the 1st MTPJ dorsiflexion and MLA movement of the right foot. Rearfoot movement was also recorded for the subjects as they walked.	The subjects were divided into two groups (immediate onset vs. delayed onset) based on early elevation of the MLA or late elevation of the MLA. Additionally, the immediate onset group had a lower heel strike angle (2.2°) and maximum rearfoot eversion (5.7°) when compared to the delayed onset group (3.8° and 7.8° respectively).
Stolwijk et al.	3D motion analysis on 18 males and 16 females with a mean age of 44 years and without any lower extremity abnormalities.	Walking at a slow speed correlated with the maximum MLA angle (17°), walking at a preferred speed correlated with the lowest MLA angle (14.8°), and walking at a fast speed gave an intermediate MLA angle (15.7°).
Lin et al.	5 male and 5 female healthy volunteers with a mean age of 25.2 years were given a “standard shoe (SS)”, “rocker sole shoe (RSS)”, “flat insole (FI)”, and “carbon fiber insole (CFI)” and instructed to wear different combinations of shoe and insole designs while walking on a treadmill at a speed of 1.4 m/s.	The lowest MLA angle (143.3°) was observed while barefoot walking and the largest MLA angle was observed with the shoe and insole combination of “RSS+FI”.

Table 1. Article Summaries

RESULTS

In order to demonstrate how much tension is experienced by the PA during the stance phase of gait, Caravaggi et al. performed an inverse kinematics analysis on three healthy volunteers, which yielded the following results: the greatest tension load was experienced by the medial slip (27%), followed by the central slips (19%), while the lateral slip underwent the least amount of tension (15%).[9] Furthermore, it was observed

that the length of the PA did not change from heel strike until approximately 30% of stance phase. From 30% of stance phase to midstance phase, the PA started elongating. A rapid increase in elongation was observed from midstance until approximately 80% of stance, where elongation peaked. The maximum elongation and tension at the push-off phase was due to the "windlass mechanism". Fuller et al. reported similar results stating that the medial slip underwent the greatest tension due to the high load amount on the 1st metatarsal head and hallux during the push-off phase.[10]

According to Bolgla and Malone, structural deformity such as an excessive forefoot varus, which is described as an inversion of the forefoot larger than 8° compared to the rearfoot, can lead to further stress on the PA due to pronation compensation by the subtalar joint (STJ). In order to control overpronation, a 6° wedge was placed under the lateral aspect of the forefoot, which reduced the tension on PA.[1] In addition, underpronation, as seen in a high-arched foot, can decrease the efficiency of the PA because of its inability to counteract upward ground reaction forces. It was demonstrated that the plantarflexed 1st ray seen in a high-arched foot applies more tension on the PA due to exaggerated "winding" underneath the 1st metatarsal head.[1]

In a study involving the effect of dorsiflexion of the 1st MTPJ on the MLA, Kappel-Bargas et al. found inconsistencies in the functioning of the "windlass mechanism" in various individuals.[11] Ten female and ten male subjects having no structural abnormalities with the mean age of 29 years were recruited. The results showed that MLA elevation occurred early, with an average of 4.1° of 1st MTPJ dorsiflexion, in 9 subjects (immediate onset group, $p<0.05$). In contrast, 11 subjects (delayed onset group, $p<0.05$) were found to have a late elevation of the MLA, with an average of 20.4° of 1st MTPJ dorsiflexion. Moreover, the immediate onset group demonstrated lower heel strike angle (2.2°) and maximum rearfoot eversion (5.7°), compared to delayed onset group (3.8° and 7.8°, respectively). These results could have important implications on the etiology of PF based on an individual's foot type.[11]

Stolwijk et al. conducted a novel study on the effects of the "windlass mechanism" on the MLA, which considered the variables of foot lengthening and walking speed. Stolwijk et al. utilized a 3D motion analysis system to study the lengthening of the foot and the range of motion of the MLA in 34 volunteers (18 males and 16 females) with a mean age of 44 years and without lower extremity abnormalities.[12] Foot lengthening was determined as the maximal foot length minus the length at heel strike, and foot shortening was determined as the length at heel strike minus the minimal length at stance. The results showed that, even though the foot length remained constant from heel strike to toe strike, the lengthening of the foot occurred after toe strike reached its maximum degree at about 50% of stance. Following heel off, the foot shortened with a quick shortening just prior to toe off. The following walking speed conditions were employed: slow speed at a mean of 1m/s, preferred speed at a mean of 1.39m/s, and fast speed at a mean of 1.78m/s. [12] Foot shortening increased as the speed increased with the following values: 6.1mm, 6.9mm and 7.8mm, respectively. On the other hand, the foot lengthening decreased with the following values: 5.8mm, 5.4mm and 5.1mm, respectively. [12] The maximum MLA was observed to be highest (17°) when walking at slow speed and lowest (14.8°) when walking at preferred speed. At fast speed, the maximum MLA angle was 15.7°, which was a slight increase from the angle observed at preferred speed. These results suggest that foot lengthening and walking speed can have additional influence on the PA and the efficiency of the "windlass mechanism".[12]

Lin et al. studied the effects of various shoe and insole designs on the "windlass mechanism" during ambulation.[13] Ten (5 male and 5 female) healthy volunteers with a mean age of 25.2 years old were offered "standard shoe (SS)", "rocker sole shoe (RSS)", "flat insole (FI)", and "carbon fiber insole (CFI)". SS was designed with a rocker angle of less than 10° only at the toe level, while RSS was designed with a rocker angle of 20° only at the toe level. The rocker angle was considered to be the angle between the ground and the line connecting the rocker-axis to the anterior end of the shoe sole. [13] The rocker-axis was situated at approximately the level of metatarsal heads. The subjects were instructed to wear different combinations of shoe and insole designs while walking on the treadmill at a speed of 1.4 m/s. The largest 1st MTPJ dorsiflexion angle, with the mean of 48.0°, was observed with barefoot walking, followed by "SS+FI" and "SS+CFI", which yielded 28.2° and 24.1° respectively. On the other hand, "RSS+FI" and "RSS+CFI" demonstrated the smallest 1st MTPJ dorsiflexion angles of 12.4° and 13.9° respectively. The smallest MLA angle (143.3°) was observed with barefoot walking, thus increasing the medial foot arch. The largest MLA angle was observed with "RSS +FI", which helps to decrease the medial foot arch and relieve extra tension exerted on the PA by decreasing the windlass effect. These results indicate that the "windlass mechanism" can be effectively manipulated by means of biomechanical principles.[13]

DISCUSSION

PA and the "windlass mechanism"

Caravaggi et al. noted significant findings during the early and late stance phases. In the early stance phase prior to a heel strike, the PA experienced tension significantly above the rest. Tension may result from muscular forces at the ankle prior to a contact, which are generated mostly by the simultaneous actions of the ankle dorsiflexors and toe extensors to prevent foot-slap. The maximum tension in the PA was recorded during the late stance phase, in which the "windlass mechanism" was in full effect. This "windlass mechanism" is specifically the dorsiflexion or extension of the toes at the MTPJ with simultaneous raise of the foot's arch, and concurrent stiffening of the PA by pulling on the heel from the cascade of inversion at the STJ and locking of the midtarsal joint. At the push-off, the maximum total tension at the PA was recorded as 1.5BW (body weight). The greatest tension load experienced at the medial slip accentuates the relationship between the PA and the "windlass mechanism" throughout the stance phase. Overall, Caravaggi et al. illustrated the importance of the PA, especially in regards to its relationship with the "windlass mechanism" during the late stance phase. However, this study included only three subjects examined barefoot; thus, these findings may not be applicable to patients with comorbidities and abnormal PA. Even so, results infer many implications for future studies. Fuller et al. also demonstrated that when a load is placed on the 1st ray, the medial slip of the PA experienced the most forces. Consequently, forces placed on the 1st metatarsal head and hallux translated into greater tension in the medial slip of the PA, which may cause pain at the PA itself or the medial tubercle of the calcaneus (the origin of the PA), and possibly form a heel spur at this location. Unlike Caravaggi et al., which examined the motion of the foot in vacuo, Fuller et al. proposed possible treatments for PF associated with the "windlass mechanism", such as reducing medial slip force by placing weight on the lateral slip. Similarly, Bolgla and Malone further examined treatment of PF based on the "windlass mechanism" model.

Overpronation and underpronation leading to PA pathology

Another biomechanical etiology includes forefoot varus resulting from compensatory excessive pronation of STJ during gait, which increases the level of stress applied to the PA as well as to adjacent soft tissue structures. However, excessive pronation does not always lead to lower extremity problems; rather, it is the continuous accumulation of minor trauma and stress over a period of time that ultimately triggers irreversible pathology. Generally, with overpronation, the MLA is low and there is excessive foot mobility. Consequently, much of the plantarflexor and invertor muscles are recruited extensively to limit the excess motion of pronation. For example, the tibialis posterior muscle controls pronation by eccentric lengthening, which reduces the tension applied to the PA during weight acceptance, but it is easily fatigued and weakened. On the other hand, a high-arched foot (pes cavus) coupled with underpronation can also impact the PA in the opposite manner. As described by Bolgla and Malone, a higher-arched foot lacks the mobility needed to assist in absorbing ground reaction forces. Consequently, its inability to dissipate the forces from heel strike to midstance increases the load applied to the PA, "much like a stretch on a bowstring." Thus, overpronation or underpronation generated at any part of the stance phase ultimately affects the "windlass mechanism" during the late stance phase of the gait cycle. For instance, excessive pronation during midstance over a period of time stressed the PA and inhibited efficient use of the "windlass mechanism" for propulsion. Furthermore, pes cavus with restricted pronation limited the foot's ability to dissipate force during midstance, thereby increasing tension applied to the PA itself as well as its insertion on the calcaneus.

MLA, foot lengthening, and walking speed

Kappel-Bargas et al. studied rearfoot motion during walking in regards to the "windlass mechanism", in addition to examining the relationship between the MLA and the amount of 1st MTPJ dorsiflexion. They found that the MLA increases following dorsiflexion of the 1st MTPJ. This is explained by the inversion of the STJ, which stabilizes the joint in conjunction with the "windlass mechanism" in order to lift the foot off of the ground. Although the rising of the MLA follows dorsiflexion of the toes, there were discrepancies among subjects regarding the time that it took for the MLA to rise. Most importantly, they observed that rearfoot eversion was correlated with an ineffective "windlass mechanism". Similar to concepts explained by Bolgla and Malone, prolonged overpronation (or eversion) during the stance phase weakened the ability of the midfoot to stabilize effectively and culminated in the development of greater tension in the midtarsal intersegmental ligaments. Stolwijk et al. described the "windlass mechanism" as a way to increase the MLA and shorten the foot at late stance as the PA tightens at toe off due to dorsiflexion of the MTPJ. The MLA increased to maximum value at approximately 80% of the stance phase, and then decreased to toe off to allow the PA to tighten for dorsiflexion of the MTPJ. The findings indicated that between 50 to 80% of the stance phase, the MLA increased while the foot length showed a slight decrease. Moreover, pace of walking speed further altered values of the MLA and foot lengthening. For example, in the fast walking speed, the foot elongated less after heel strike and shortened more during push off, allowing for a more rigid structure enforced through the "windlass mechanism" for effective propulsion and force absorption.[12]

Rehabilitation programs

Bolgla and Malone recommend rehabilitation programs for abnormalities associated with PF. Many times, excessive pronation results from muscle weakness, heel-cord tightness, and structural foot deformities. Over a long period of time, overpronation will eventually lead to the weakness of tibialis posterior and PA elongation. As the tibialis posterior

weakens, it is less able to tolerate ground reaction forces during the contact phase. Moreover, PA elongation will affect the stability of the "windlass mechanism" during the propulsion phase. Thus, one purpose of rehabilitation is to improve tibialis posterior strength by ankle inversion using elastic bands, side-lying ankle inversion using ankle weights, and single-leg-stance balance activities with a neutral foot position. To enhance ankle plantarflexion strength, heel raises with the foot in a toed-in position and arch raises with the foot in a weight-bearing position are suggested. [1] In cases of abnormalities resulting from underpronation, in which PF is rigid and unable to dissipate forces, Bolgla and Malone recommend exercises to improve flexibility of extrinsic and intrinsic muscles involved in supination and plantarflexion of the foot. Stretching exercises of the gastrocnemius and soleus muscles has been proven to be effective in enhancing Achilles tendon flexibility, which reduces the tension applied to the PA.

Treatment modalities in the form of shoe and insole designs

Lastly, appropriate shoe and insole designs can be utilized to decrease the windlass effect.[13] The RSS and SS with CFI or FI successfully inhibited the windlass effect by decreasing the 1st MTPJ dorsiflexion angle. The best effects were seen with RSS, which was efficient in reducing the peak tensile forces and stress experienced by the PA during the propulsion phase. It is important to keep in mind that the material used to construct the rocker outsole was firm enough to counteract the bending moment during propulsion. The CFI can assist with counteracting the bending moment by contributing to the rigidity of the shoe outsole. In order to absorb a large amount of energy exerted on the foot by the ground, Kogler et al. suggests the use of viscoelastic materials in the construction of orthotic insoles for PF.[14] Coincidentally, the CFI and FI used in the study by Lin et al. were made from polyurethane and ethylene-vinyl acetate, both of which have significant viscoelasticity. Further studies are needed to determine the long-term effects of these types of shoe designs in the treatment of PF.

CONCLUSION

This literature review suggests that the excessive chronic windlass effect contributes to the development of microtrauma at the medial calcaneal tubercle due to exaggerated pull by the PA. The medial slip of the PA experiences repetitive high stress loads during the action of the "windlass mechanism" as the attachment of the PA on the calcaneus pulls the periosteum. Given that the medial slip of the PA receives most of the tension, the therapy should be aimed at redirecting the forces towards the lateral slip. By shifting the force to the lateral side of the foot, it indirectly reduces the pressure placed on the medial side. Tension in the PA can be reduced by the application of forefoot valgus wedges. PF associated with overpronation can be treated by enhancing the strength of the tibialis posterior, while the treatment modality for PF caused by underpronation includes exercises aimed at improving Achilles tendon flexibility. Furthermore, increased supination moment applied to the STJ can alleviate pressure on the medial slip. This can be achieved through many sources, including orthosis or a low-dye strapping that strengthens the supination especially during the heel off. Since the classic symptom of PF is heel pain with the first steps in the morning, application of night splints can help to reduce the PA shortening caused by plantarflexed position of the foot during sleeping hours. Night splints can keep the foot in a somewhat dorsiflexed position. Other conservative treatments such as modification of shoe and insole designs are utilized to minimize the windlass effect, primarily by reducing the 1st MTPJ dorsiflexion angle and decreasing tensile stress at the PA during the late stance phase. These findings can aid clinicians in identifying

specific biomechanical etiologies of PF associated with inefficient "windlass mechanism" and choosing appropriate treatment options.

AUTHORS' CONTRIBUTION

Four authors contributed equally to the production of this article. All conceived the topic, performed initial literature reviews, evaluated abstracts, and authored the introduction, results, discussion and conclusion. All authors drafted, read, reviewed, and agreed upon the final manuscript.

STATEMENTS OF COMPETING INTERESTS

The authors declare that they have no competing interests.

REFERENCES

1. Bolgla LA, Malone TR. Plantar fasciitis and the windlass mechanism: a biomechanical link to clinical practice. *J Athl Train*. 2004; 39(1): 77-82.
2. LeMelle DP, Kisilewicz P, Janis LR. Chronic plantar fascial inflammation and fibrosis. *Clin Podiatr Med Surg.* 1990 April; 7(2): 385-389.
3. Bergmann JN. History and mechanical control of heel spur pain. *Clinical Podiatry Med Surg.* 1990 April; 7(2): 243-259.
4. Nuber GW. Biomechanics of the foot and ankle during gait. *Clinics in Sports Medicine.* 1988; 7(1): 1-13.
5. Moore, K. L., & Dalley, A. F. *Clinically oriented anatomy*. Philadelphia: Lippincott Williams & Wilkins. 1999; 6th ed.: 610–611.
6. Hicks JH. The mechanics of the foot, II: The plantar aponeurosis and the arch. *J Anat.* 1954; 88: 25–30.
7. Garcia CA, Hoffman SL, Hastings MK, Klaesner JW, Mueller MJ. Effect of metatarsal phalangeal joint extension on plantar soft tissue stiffness and thickness. *The Foot.* 2008; 18: 61-67.
8. Aquino A, Payne C. Function of the Plantar Fascia. *The Foot. 1999;* 9: 73-78.
9. Caravaggi, P, Pataky,T, Goulermas, JY, Savage, R and Crompton, RH . A Dynamic Model of the Windlass Mechanism of the Foot: Evidence for Early Stance Phase Preloading of the Plantar Aponeurosis. *J. exp. Biol*. 2009; 212L: 2491-2499.
10. Fuller, EA. The windlass mechanism of the foot. A mechanical model to explain pathology. *J. Am. Podiatr. Med. Assoc.* 2000; 90: 35 -46.
11. Kappel-Bargas A, Woolf RD, Cornwall MW, McPoil TG. The windlass mechanism during normal walking and passive first metatarsalphalangeal joint extension. *Clin Biomech (Bristol, Avon)*. 1998; 13: 190-194.
12. Stolwijk NM, Koenraadt KLM, Louwerens JWK, Grim D, Duysens J, Keijsers NLW. Foot lengthening and shortening during gait: A parameter to investigate foot function. *Gait & Posture*. 2013.
13. Lin SC, Chen C.PC, Tang SFT, Wong AMK, Hsieh JH, Chen WP. (2013) Changes in windlass effect in response to different shoe and insole designs during walking. *Gait & Posture.* 2013; 37: 235-241.
14. Kogler GF, Solomonidis SE, Paul JP. Biomechanics of longitudinal arch support mechanisms in foot orthoses and their effect on plantar aponeurosis strain. *Clin Biomech (Bristol, Avon).* 1996; 11: 243-252

A Literature Review on the Contributing Factors of Second Metatarsal Stress Fractures in Ballet Dancers

Pooja Shah, BA, Maya Robinson, BS, Suganthi Kandasamy, MPH, BA

Abstract

Introduction:
Overuse stress fractures are a frequent occurrence in ballet dancers, often due to excessive plantarflexion in the "en pointe" ballet position. More specifically, ballet dancers exhibit an increased frequency of stress fractures in the 2nd metatarsal as compared to adjacent metatarsals. The purpose of this paper is to review factors contributing to stress fractures in ballet dancers and determine whether changes can be made to decrease the possibility of developing a metatarsal stress fracture.

Study Design: Systematic Review of the Literature

Methods:
A search was performed on PubMed and Google Scholar with keywords (ballet, dance, dancer, stress fracture, metatarsal fracture, second metatarsal, overuse, pointe). The inclusion criteria were limited to studies done on current or previous ballet dancers and fractures of the metatarsals. We also included one broader systematic review of studies conducted on dancers that analyzed various factors contributing to one's likelihood to develop overuse dance injuries. Exclusion criteria consisted of studies about non-dancers and types of injuries unrelated to overuse in ballet dancers. After we obtained full text articles from various journals, we read and analyzed them by their subject size, selection criteria and if applicable, treatment options.

Results:
Based on the various articles that were obtained, it was determined that multiple factors contribute to the development of second metatarsal stress fractures in ballet dancers. There was no gender predisposition; however, the incidence of stress fractures can be correlated to nutrition, menses in females, and duration of ballet dancing. The length of the second metatarsal in relation to the first metatarsal was measured; however, the difference in length was found to be insignificant when relating it to the cause of the stress fracture. It is believed that because of the nature of the "en pointe" and "demi pointe" ballet positions, ballet dancers make themselves more susceptible to second metatarsal stress fractures as compared to other types of athletes.

Conclusion:
Stress fractures are the most common injury in both male and female ballet dancers. However, there is no main identifiable cause. Since most stress fractures are multifactorial, it becomes difficult to prevent these stress fractures from occurring so frequently in ballet dancers. However, modifications to nutrition and diet may help to minimize the incidence and frequency of overuse stress fractures. Furthermore, early identification of risk factors, such as lax ligaments, irregular menses, and chronic overuse, can allow us to make necessary modifications to control and minimize the risk of developing a stress fracture.

Key words: ballet, dance, dancer, stress fracture, metatarsal fracture, second metatarsal, overuse, pointe

Level of Evidence: 4

INTRODUCTION

Ballet dancing is a very rigorous form of dance that involves a significant amount of physical activity, placing strain on the joints of the lower extremity. Classical ballet dancers that have extensive hours of practice on a daily basis are prone to overuse injuries.[1] It has been reported that about half of all sports injuries are due to overuse, whether it be soft tissue, bone, or both. Of these overuse injuries, the most common ones involve the leg, followed by the foot and ankle.[2] Common ballet positions include en pointe and demi pointe, which require full weight-bearing plantarflexion of the foot. In the demi or "half" pointe position, the forefoot bears full body weight rather than the entire foot plantigrade. During the transition from the demi pointe to the "en pointe" position, dancers undergo increased forefoot stress, having to bear their body weight on the tips of their toes, resulting in "forced maximum weightbearing plantarflexion" at the ankle joint.[3,4] This excessive talocrural plantarflexion can cause significant stress on the anatomical structures nearby, including the trabecular system of the bones.[5] More specifically, it is believed that the en pointe position results in the distal leg and rearfoot operating as one long lever, with weight and forces becoming concentrated at the tarsometatarsal joints. These changes place a greater stress on the Lisfranc's joint, which, in a plantigrade foot, serves to lock the 2nd metatarsal between the 3 cuneiform bones. This increased stress in the demi and en pointe positions makes the second metatarsal base more susceptible to fracture.[5]

Fig 1. *The en pointe position.*[4]

While this excessive plantarflexion can lead to overuse injuries in ballet dancers, there are certainly risk factors that will enhance the likelihood of these injuries, unrelated to the dance technique itself. These factors may include diet and nutrition, female menses, floor type, tarsometatarsal ligamentous integrity, and osteoporosis. All of these factors may compromise bone quality, making the metatarsal bones more susceptible to fracture.

Stress fractures are defined as a partial or full interruption of the bony cortex, occurring due to repetitive stress to normal cortical bone.[7] Within the specific group of classical ballet dancers, the most common stress fracture occurs at the base of the second metatarsal.[7] Stress fractures are seen in association with many other conditions or lifestyle factors as well. For example, Morton's foot, a condition in which the length of the second metatarsal is longer than the average, may be related to the cause of stress fractures. This may be in part due to the increased forces applied to the second metatarsal.[8]

Nutritional factors, as well as hormonal influences, may also predispose one to stress fractures. It was observed, when comparing a group of dancers vs. non-dancers, that the dancers were found to have low fat intake, low calorie consumption, and food avoidance in their diets, paired with high amounts of caffeine intake. With this health obsession comes a higher incidence of

eating disorders such as anorexia and bulimia.[9] There is a significant association between eating disorders and irregular menses, leading to hormonal changes and a relative estrogen deficiency. This ultimately leads to a decrease in bone density. For females in particular, the "female triad" of amenorrhea, osteoporosis and an eating disorder posed a considerable risk for developing a metatarsal stress fracture .[2]

In this paper, a literature review of different factors contributing to stress fractures of the second metatarsal are evaluated and compared across various sources. The subjects that are under research are ballet dancers. High risk factors that are specific to dancers are also being reviewed in this paper.

METHODS

All authors performed detailed keyword literature searches on the PubMed and Google Scholar online databases to identify appropriate articles related to overuse-related metatarsal stress fractures identified in ballet dancers. Keywords included "ballet", "dance", "dancer", "metatarsal fracture", "stress fracture", "second metatarsal" and "overuse". We also used the Boolean operators "AND" and "OR" so as not to limit our results to papers that did not include all keywords. PubMed yielded 63 results, which we reduced to 12 articles based on our inclusion and exclusion criteria (Figure 2). Articles that did not highlight the ballet dancer's pointe position, or address the prevalence of overuse stress fractures in ballet were eliminated.

Inclusion Criteria	-Ballet Dancer -Second Metatarsal Stress Fracture -Overuse -Pointe
Exclusion Criteria	-Non-dancer -Ankle Injuries -Non English Articles

Fig 2. *Inclusion and Exclusion Criteria*

RESULTS

Upon analyzing our sources, it was found that stress fractures are multifactorial. However, the most contributing factor was the overuse of the "over-pointe" position.[2, 6-8, 10-14] Other articles demonstrated the influence of nutritional deficiency and resultant amenorrhea on the development of metatarsal stress fractures. The theory of a long second metatarsal as a possible risk factor was found to be correlated to this type of injury, but lacked specific statistical support that would establish it as a definitive cause. [5, 7, 8, 12]

The results are portrayed in Figure 3.

DISCUSSION

Overuse

A large contributing factor to metatarsal stress fractures among classical ballet dancers is overuse. The repetitive loading of a dancer'sfull body weight upon the ankle and foot creates significant stress on the joints and ligaments of the midfoot and forefoot, specifically at the tarsometatarsal joints. This excessive loading is exhibited by the extreme talocrural plantarflexion demonstrated in the pointe position. Ballet dancers are often required to hold this position and repeat it for several hours of the day, thereby creating a chronic source of pressure applied to the lesser metatarsals of the foot. More specific to the prevalence of a stress fracture in the second metatarsal is the unique anatomy of the Lisfranc's joint, making it more susceptible to stress. The second metatarsal articulates with all three of the cuneiform bones. The medial and the lateral cuneiforms together lock the base of the second metatarsal in its place, giving the second metatarsal limited mobility as compared to the adjacent tarsometatarsal joints. Therefore, when repeated stress is

	Nutritional Deficits (Low Calorie Diet)	Amenorrhea	Longer Second Metatarsal	Overuse from "Over-Pointe"
Albisetti et al	x	x		x
Russell et al	x			x
Micheli et al			x	
Muscolo et al	x	x	x	x
Davidson et al			x	x
Frusztajer et al	x	x		
Elias et al				x
Kadel et al				x
Chuckpaiwong et al			x	x
Queen et al				x
Stretanski et al	x			x
Freeman et al	x			

Fig 3. *Contributing factors of Second Metatarsal Stress Fractures*

applied, this bone is unable to adjust to the increased weight applied, and over time, these forces result in the breakdown of the trabecular bone of the second metatarsal base.[5]

Diet and Nutrition

One of the major factors that can cause low bone density and osteoporosis is poor nutrition. Ballet dancers with restricted caloric intake have been shown to exhibit decreased skeletal bone mass. This low bone density can lead to osteoporosis and diminished calcium within bones, leading to a greater risk of stress fractures during dance. Furthermore, a low calorie diet and weight loss often results in amenorrhea, which has also been identified in many ballet dancers presenting with overuse metatarsal stress fractures. Amenorrhea is due to the decrease in gonadotropin releasing hormone (GnRH), which subsequently decreases follicular stimulating hormone (FSH) and luteinizing hormone (LH) from the pituitary gland. This overall decrease will suppress the ovaries from producing estrogen and progesterone, leading to abnormal menses. Amenorrhea associated with female athletes is commonly referred to as secondary amenorrhea. Secondary amenorrhea can lead to a decrease in estrogen levels, which subsequently will lead to a loss of bone mass.[15]

In a study done by Frusztajer et al., the low calorie diet observed by dancers was seen to have less than 85% of the recommended

dietary allowance. They were not consuming any of the high fat dairy products such as whole milk, eggs, cheese, and butter. On the contrary, the consumption of low calorie products such as diet sodas, coffee, and skim milk were very high. A high consumption of saccharin was observed as well. In the group of dancers with stress fractures, the protein, carbohydrate, and fat consumption was lower than that of non-dancers. The average caloric intake of the non-dancer group was 1672.2 kcal/day. For the dancer group with no stress fracture, their average was 1431.6 kcal/day, and the dancers with stress fractures had an average caloric intake of 1139.1 kcal/day. Most of the dancers with the stress fractures were classified as underweight or had a history of an eating disorder of anorexia or bulimia.[2]

In addition to a low calorie diet, the intake of caffeine has been associated with osteoporosis and low bone mass. High caffeine consumption can be detrimental due to its impact on calcium, increasing the amount of calcium removed in the urine and resulting in less calcium in the body and in the bones. Women drinking large amounts of coffee have been shown to have an increased risk and incidence of stress fractures.[9]

Tarsometatarsal Ligaments

The significance of dorsal, interosseous, and plantar tarsometatarsal ligaments is another important factor in stabilizing the foot in plantarflexion when in the pointe stance, as compared to the en pointe shoe itself. Kadel utilized 11 cadaveric feet with second metatarsal base fractures. These feet were inserted into a loading frame. Researchers then incrementally increased the force applied, and modified each trial by cutting either the dorsal, interosseous, plantar, or all tarsometatarsal ligaments prior to loading. They determined that no individual ligament served as the primary stabilizer of the Lisfranc joint complex. However, when all of the tarsometatarsal ligaments were transected, this led to "complete collapse and diastasis, subluxation, and dislocation of the first and second metatarsocuneiform region."[11]

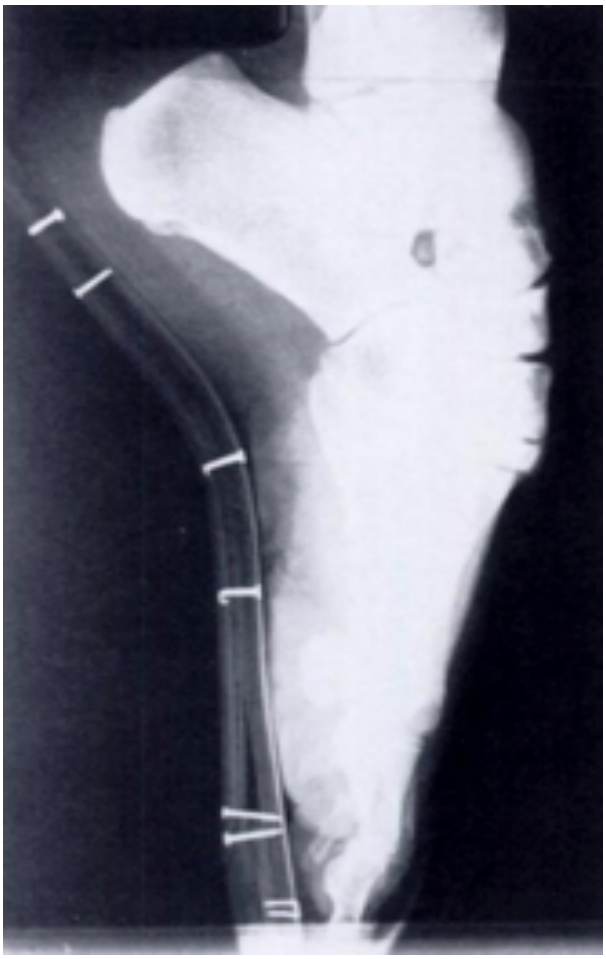

Fig 4. *Extreme plantarflexion at the ankle that occurs during the "en pointe" position*

Fig 5. *Oblique 2nd metatarsal stress fracture involving the 2nd tarsometarsal*

In Figure 5, the black arrow points to the fracture involving the second tarsometatarsal joint.

Morton's foot

Davidson et al. evaluated fifty female classical dancers based on the length of their second metatarsal in relation to their first metatarsal. Of these fifty, eleven subjects presented with a stress fracture, some of which were on both feet. In ballet, a longer second toe can increase the force through the second metatarsal in the en pointe position; however, it cannot be concluded that a second metatarsal stress fracture is a direct result of a shorter first ray.[8] In the demi and en pointe positions of ballet, the first and second metatarsals bear the most weight on the proximal and plantar surfaces, especially that of the second metatarsal. This is believed to predispose the dancers to stress injury.

Morton's foot could influence a person's gait or posture and should be addressed with appropriate treatment such as shoe modifications, padding, or insoles. Of the fifty dancers that were evaluated, none were classified as having Morton's foot. Davidson demonstrated that the absence of Morton's foot in a large population of ballet dancers did not affect the rate of stress fractures, suggesting minimal association between the two. These findings add to the body of evidence that disputes the current belief that a longer second metatarsal is a key risk factor for stress fracture.

CONCLUSION

Although stress fractures are very common, there are no current findings to attribute a definite main cause of these fractures. Ballet dancers that are constantly in the en pointe and demi pointe position, have feet that are placed in an overly plantarflexed position. This position puts stress on all of the anatomical structures of the foot, especially the second metatarsal. There is no sufficient data to support the idea that a longer second metatarsal, also known as Morton's foot, contributes to a higher risk of stress fractures. The most likely factor contributing to these stress fractures is due to overuse.

Furthermore, the rigorous lifestyle of these ballet dancers requires them to also abide by a strict diet. With the low fat and low calorie diet, it is believed that these dancers make themselves further susceptible to these fractures. Additionally, a physical assessment of ballet dancers requires consideration of noncompliant tendencies due to the hectic

lifestyle and work related demands. When injured, dancers are likely to disregard recovery time, giving practice time precedence. As a physician, it is important to inform patients who are ballet dancers of stretching exercises, different physical therapy modalities, and other conservative treatments. In the en point position, the pointe shoe and tarsometatarsal ligaments are important to Lisfranc joint stability, hence it is crucial for clinicians to select a pointe shoe with adequate support to help limit a ballet dancer's susceptibility to a stress fracture in the second metatarsal. The pointe shoes should be strong enough to support the dancers, while still allowing the dancers to execute their movements with grace. Ballet dancers prefer conservative measures as opposed to surgical treatments because of the potentially shorter recovery time and impairment on range of motion in the area of injury. An extended recovery time can also be daunting for a ballet dancer, not only financially but also psychologically.[16] Understanding that the fear of career loss may lead to patient conflict, the physician should use every encounter to reinforce the necessity of adherence to the treatment plan with positive considerations for future outcomes.

One of the major limitations was the lack of research focused specifically on ballet dancers and second metatarsal stress fractures. While we were able to identify several case reports and case studies, most of the research available covered a broader spectrum, whether it be different types of lower extremity fractures or simply athletic fractures in general, nonspecific to ballet and dancing "en pointe." For example, there are several studies that discuss the prevalence of stress fractures in female athletes on restricted diets, delayed menarche, and low bone density. Further research regarding this specific subset of people of ballet dancers needs to be done.

Given the limited findings in the literature regarding the association between diet and stress fractures in ballet dancers, it could be suggested that future studies focus on this area. It may be useful to employ serum markers for malnourishment, such as albumin, at the time of injury. Such a study would allow for easy quantification and inferential analysis to determine if a correlation exists between the two conditions. Studies conducted to compare the overall albumin level of a ballet dancer to a non-dancer of the same age, sex and weight can also be used to see the detrimental effects of a limited diet. Although, stress fractures among ballet dancers are so common there is still much that needs to be discovered regarding a specific etiology that makes this population so prone to these injuries.

AUTHORS' CONTRIBUTION

Four authors contributed equally to the production of this article. All conceived the topic, performed initial literature reviews, evaluated abstracts, and authored the introduction, results, discussion and conclusion. All authors drafted, read, reviewed, and agreed upon the final manuscript.

STATEMENTS OF COMPETING INTERESTS

The authors declare that they have no competing interests.

REFERENCES

1. Harrington T, Crichton KJ, Anderson IF. Overuse ballet injury of the base of the second metatarsal. A diagnostic problem. *Am J Sports Med.* 1993 Jul-Aug;21(4):591-8.
2. Albisetti W, Perugia D, De Bartolomeo O, Tagliabue L, Camerucci E, Calori GM. Stress fractures of the base of the metatarsal bones in young trainee ballet dancers. *Int Orthop.* 2010;34(1):51-5.
3. Sobrino FJ, de la Cuadra C, Guillen P. Overuse Injuries in Professional Ballet: Injury-Based Difference Among Ballet Disciplines. Orthopaedic Journal of Sports Medicine. 2015;3(6).
4. Russell JA. Breaking pointe: Foot and ankle injuries in dance. http://lermagazine.com/cover_story/breaking-pointe-foot-and-ankle-injuries-in-dance 2012. Available at: http://lermagazine.com/cover_story/breaking-pointe-foot-and-ankle-injuries-in-dance. Accessed January 24, 2016.
5. Micheli LJ, Sohn RS, Solomon R. Stress fractures of the second metatarsal involving Lisfranc's joint in ballet dancers. *J Bone Joint Surg. [Am]* 1985;67:1372–5.
6. Russell JA. Preventing dance injuries: current perspectives. *Open Access J Sports Med.* 2013;4:199-210.
7. Musculo L, Migues A, Slullitel G, Costa-Paz M. Stress Fracture Nonunion at the Base of the Second Metatarsal in a Ballet Dancer. *Am J Sports Med.* 2004;32(6):1535-7
8. Davidson G, Pizzari T, Mayes S. The Influence of Second Toe and Metatarsal Length on Stress Fractures at the Base of the Second Metatarsal in Classical Dancers. *Foot Ankle Int.* 2007; 28(10):1082-6.
9. Frusztajer NT, Dhuper S, Warren MP, Brooks-Gunn J, Fox RP. Nutrition and the incidence of stress fractures in ballet dancers. *Am J Clin Nutr.* 1990;51:779-83.
10. Elias I, Zoga AC, Raikin SM, et al. Bone stress injury of the ankle in professional ballet dancers seen on MRI. *BMC Musculoskeletal Disorders* 2008, 9:39.
11. Kadel N, Boenisch M, Teitz C, Trepman E. Stability of Lisfranc joints in ballet pointe position. *Foot Ankle Int.* 2005;26(5):394–400.
12. Chuckpaiwong B, Cook C, Pietrobon R, Nunley JA. Second metatarsal stress fracture in sport: comparative risk factors between proximal and non-proximal locations. *Br J Sports Med.* 2007;41(8):510-4.
13. Queen RM, Abbey AN, Chuckpaiwong B, Nunley JA. Plantar Loading Comparisons Between Women With a History of Second Metatarsal Stress Fractures and Normal Controls. *Am J Sports Med.* 2009;37:390-5.
14. Stretanski MF, Weber GJ. Medical and rehabilitation issues in classical ballet: Literature review. *Am J Phys Med Rehabil.* 2002;81:383–391.
15. Michelle A. Laframboise P. The female athlete triad: a case series and narrative overview. *The Journal of the Canadian Chiropractic Association*. 2013;57(4):316. Available at: http://www.ncbi.nlm.nih.gov/pmc/articles/PMC3845471/.
16. Ojofeitimi S, Bronner S, Becica L. Conservative Management of Second Metatarsophalangeal Joint Instability in a Professional Dancer: A Case Report. *J Orthop Sports Phys Ther Journal of Orthopaedic & Sports Physical Therapy* 2016;46(2):114–123.
17. Freeman D, Randall DB. Stress Fracture of the Foot Secondary to Osteoporosis: An Atypical Presentation. *J Am Pod Med Assoc.* 2001;91:99-101.

A Systematic Review of Plantar Calcaneonavicular Ligament Reconstruction Techniques And Its Role In Maintaining The Medial Longitudinal Arch

Gireesh Reddy, BS, Ammar Al Rubaiay, BA, Ibn Ansari, BS

Abstract

Introduction
Adult acquired flatfoot deformity is often a secondary consequence to a spring ligament insufficiency. The spring ligament (SL) provides static support to the medial longitudinal arch (MLA). Direct suturing of a complete SL tear is generally not adequate and a reconstruction of the ligament is required. Although several techniques for SL reconstruction are mentioned in the literature, no single technique is validated. The purpose of this systematic review is to analyze various SL reconstruction techniques and their efficacy in maintaining the MLA.

Study Design: Systematic Literature Review

Methods
A PubMed and Cochrane database search of calcaneonavicular ligament, spring ligament, reconstruction or repair was performed using the “and /or” operators and resulted in 30 papers. Three separate investigators performed a careful review of 30 abstracts and eliminated 20 papers that did not fit the inclusion criteria. After careful analysis of the remaining ten papers, a total of five papers were selected for this systematic review.

Results
The use of autogenous Flexor Hallucis Longus (FHL) tendon to reconstruct the SL was described in one study and the results showed an improvement in the AOFAS score in addition to improved clinical and radiographic results.[4] Two separate papers described SL reconstruction using peroneus longus (PL) tendon, however, one of the studies was cadaveric. Three variations of SL reconstruction using the PL tendon graft were demonstrated in the cadaveric study.[2] The superomedial and plantar approaches demonstrated correction of talonavicular adduction, but lacked any significant improvement in subtalar eversion. The only study with long-term results was with peroneus longus autograft in patients with an average follow up of 8.9 years.[9] In this study, significant improvements were found in the AOFAS ankle-hindfoot score, the postoperative FAOS pain scale, the AP first tarsometatarsal angle, talonavicular coverage angle, lateral calcaneal pitch, and lateral talonavicular angle.[9] Two studies used FiberTape augmentation; however one study used remnants of the SL from the navicular and suspended them to the medial malleolus using FiberTape while the other study used primary anatomic repair method for the SL and a secondary internal fixation augmentation technique.[1] Short-term results showed an improvement in foot position after SL repair greater than what would be expected with medializing calcaneal osteotomy and flexor tendon transfer alone.[1]

Conclusion
Of the various techniques described in literature, FHL and PL tendon transfers have demonstrated to provide adequate stability of the MLA and are a viable option in SL reconstruction surgery. Although the PL tendon procedure demonstrated adequate long-term results, no one particular technique has shown consistent clinical results. Considerable variability in modalities used in assessing the grade of spring ligament tear and maintenance of MLA post reconstruction have made it difficult to compare the results across different studies. Future clinical studies with consistent patient selection, long-term followup, and control groups are necessary to provide a single viable and reliable method for reconstruction of the SL.

Key Words: Spring Ligament, Calcaneonavicular ligament, Tear, Reconstruction, Repair.

Level of Evidence: 3A

INTRODUCTION

Bone structures, muscles, and ligaments are the three main components that maintain the medial longitudinal arch (MLA) of the foot. Although the role of osseous structures and muscles is well studied, the role of ligaments is often underplayed. The spring ligament (SL) is one of the most important ligaments in the foot as it links the midfoot with the hindfoot.[4] The SL is a thick broad fibrous band that begins on the sustentaculum tali and connects to the plantar surface of the navicular.[6]

The SL complex has two distinct anatomical regions: superomedial and inferior fibers.[2] The superomedial fibers originate from the superomedial aspect of the sustentaculum tali and the anterior facet of the calcaneus and insert broadly on the medial aspect of the navicular.[4] The inferior fibers course from the anterior aspect of the sustentaculum tali to the inferior surface of the navicular. Together, the entire SL complex provides the "sling like" support function and prevents excessive plantarflexion/adduction of the talar head.[4] Some studies have also reported a third portion of the SL, termed the third ligament.[6] The third ligament originates between the anterior and middle facets of the calcaneus and inserts onto the navicular tuberosity.[6]

While the SL provides the main static support of the MLA, the posterior tibial (PT) tendon primarily provides the dynamic support of the medial arch.[12] The SL plays an important role in supporting the head of the talus and in-turn bears a significant percentage of the body weight. An insufficiency of the SL caused by excessive stress or a tear in the ligament can lead to a collapse of the MLA and result in an acquired flatfoot deformity. Williams et al. proved with high level of statistical significance, a strong association between SL abnormality and flatfoot deformity.[10] Williams et al. also demonstrated that MRI-defined abnormalities of the SL complex are of at least equal importance to PT dysfunction for the presence of radiographic flatfoot deformity.[10]

In the presence of a partial SL tear, it is common practice to directly suture the SL.[9] However, directly suturing the ligament is not adequate in the case of a complete tear and a reconstruction of the ligament is necessary. Although several techniques for SL reconstruction are noted in literature, no one technique has demonstrated consistent results.[4] The purpose of this systematic literature review is to describe various SL reconstruction techniques and to analyze their efficacy and complications in maintaining the MLA.

METHODS

A systematic review of literature was conducted using both PubMed and Cochrane databases. A search of calcaneonavicular ligament, spring ligament, reconstruction or repair was performed using the "and / or" operators. This primary search of databases resulted in a total of thirty papers from the PubMed database and zero papers from the Cochrane database. Three separate investigators performed a careful review of thirty abstracts and eliminated twenty papers that did not fit the inclusion criteria. The inclusion criteria included papers that dealt primarily with the spring ligament, plantar calcaneonavicular ligament, spring ligament tear, and spring ligament complex reconstruction; along with papers published

Fig 1. Summary of Search Results

after the year 2000, and papers written only in the English language. The exclusion criteria for this systematic review included non-English language papers and papers published before the year 2000. After careful analysis of the remaining ten papers, a total of five papers were selected for this systematic review as they provided novel techniques to repair a torn SL.

RESULTS

After a systematic selection process of literature using the PubMed and Cochrane databases, five articles fit the inclusion/exclusion criteria. Of the five articles, four articles were clinical, while one article by Choi et al., was cadaveric.

In the clinical study by Lee et al., the use of an autogenous Flexor Hallucis Longus (FHL) tendon to reconstruct SL was described. After a medial displacement calcaneal osteotomy, to augment the SL, distal FHL tendon was incised at insertion.[4] Drill holes were made through the medial cuneiform and navicular.[4] The tendon was passed through the medial cuneiform and then through the navicular and finally medial to lateral through the sustentaculum tali.[4] While adducting the transverse tarsal joints and inverting the subtalar joint, the tendon transfer was tensioned.

In another paper, by Choi et al., three variations of SL reconstruction using the PL tendon were described in a cadaveric study. In the first variation, labeled the Plantar Reconstruction, the PL tendon was pulled out through the medial incision while preserving its insertion.[2] A hole directed transversely and posteriorly was drilled through the sustentaculum tali and the PL tendon was pulled medial to lateral through the calcaneus.[2] A cancellous screw and washer was inserted in the lateral wall of the calcaneus and while manually maintaining the tension of the tendon, it was sewn onto itself. The second technique was labeled as Superomedial Reconstruction.[2] This procedure was similar to the plantar reconstruction; however, after harvesting the PL tendon, a superior-inferior hole was drilled through the navicular. The final technique described was labeled as a Combined Superomedial/Plantar Reconstruction.[2] For this technique an additional 6 mm drill hole

Article	Type of Reconstruction	Approach
Lee et al.	Autogenous FHL tendon	- Medial incision along the course of FHL tendon - Medial incision along the 1st MTPJ
Choi et al.*	PL tendon from same cadaver	- Lateral incision from the lateral malleolus to the base of the fifth metatarsal - Medial incision one centimeter distal to the first metatarsocuneiform joint and extended proximally
Williams et al.	Autogenous PL tendon	- Medial incision along the course of PT tendon - Lateral incision over the distal fibula - Lateral incision from the base of the fifth metatarsal towards the cuboid tunnel
Palmanovich et al.	Primary repair with reconstruction using FiberTape	- Medial incision along the course of PT tendon to its insertion on the navicular
Acevedo et al.	Primary repair with reconstruction using FiberTape	- Medial incision along the course of PT tendon to its insertion on the navicular

Table 1. *Types of reconstruction and the surgical incisional approaches for each of the studies discussed. *Choi et al. was the only cadaveric study discussed*

was made posterior to the existing calcaneal drill hole.

Williams et al. also used a PL autograft, similar to the one described by Choi et al., however, they described a novel surgical procedure in clinical subjects. In this technique, two bony tunnels were used to fixate the tendons.[9] The distal tunnel was made in the navicular while the proximal drill hole was selected based on the type of talonavicular deformity present. In cases where significant plantar sag was found at the talonavicular joint, a calcaneal hole was utilized.[9] Comparatively, in cases that had significant abduction through the talonavicular joint, a tibial hole was utilized. The PL tendon was extracted through a longitudinal incision over the fibula and the proximal end of the PL was tenodesed to the peroneus brevis.[9] The tendon was left attached to the base of the first metatarsal and delivered through the medial incision. Grafts were passed through the navicular drill hole and then through the calcaneal or tibial hole and screws were used as posts to tie down the graft sutures.[9]

The paper by Palmanovich et al. described another method of reconstructing a torn SL.[5] In this case, the remnants of the SL were augmented from the navicular to the sustentaculum tali and suspended to the medial malleolus using FiberTape.[5] The procedure had a tunnel drilled through the navicular bone in addition to a second tunnel drilled through the sustentaculum tali.[5] The SL was directly sutured using Ethibond to strengthen the remnant of the ligament. The ligament was then reconstructed using FiberTape in a figure-of-eight pattern passing through the navicular bone tunnel vertically, and then passing through the sustentaculum tali tunnel horizontally.[5] The final step involved anchoring the remnants of the FiberTape to the medial malleolus under tension with a SwiveLock.[5]

Acevedo et al. also presented a primary anatomic repair method for the SL and a secondary internal fixation augmentation technique using FiberTape along with reconstruction of the diseased PT tendon via FDL transfer.[1] In this technique, after performing the osseous procedures, the SL was anatomically repaired and the internal augmentation technique was performed. The inferomedial and superomedial bands of the SL were recreated using a FiberTape construct with SwiveLock anchors. In cases where the SL had been ruptured, the tear was completed and advanced under maximal tension. In cases where the ligament was stretched, a longitudinal incision in the superior and inferior bands was created and advanced using #2 fiberwire sutures through the midsubstance in a pants-over-vest fashion. A single tunnel in the navicular was used to fixate the transferred FHL tendon and both FiberTape limbs.[1] This method allowed maximum tension of the anatomic repair through the support of the FiberTape construct.[1]

DISCUSSION

Spring ligament tear

Although several techniques for SL augmentation are described in this systematic review, variability is noted in the methods for assessing SL tears and in the extent of SL attenuation. In the paper by Lee et al., SL reconstruction was performed for patients with either a MRI confirmed or a SL dysfunction defined as talar head adduction and plantarflexion as seen on weight-bearing X-rays. Choi et al. used cadaveric foot-ankle specimens with a deformity model of 5-15 degrees talonavicular abduction. The deformity models were created by sectioning the medial talonavicular joint capsule, the superomedial fibers of the SL, and the interosseous ligament. In the article by Williams et al., after a lateral column lengthening and a medializing calcaneal osteotomy, the decision to perform the SL reconstruction procedure was made intraoperatively if persistent talonavicular abduction or talonavicular sag were noted. In the study done by Palmanovich et al., determination of a SL tear was performed clinically by abducting the foot. Upon abduction, if the head of the talus is exposed, one was deemed to have a complete tear. If the head of the talus was mildly protruded, a SL attenuation was present. Due to the lack of consistency in the methods for evaluating and grading SL attenuation, it is difficult to compare various studies assessing SL reconstruction methods. In a study by Gazdag and Cracchiolo et al., a grading scale for SL pathology associated with PT tendon dysfunction was described.[3] A grade 1 tear was described as either longitudinal tear within the midsubstance or partial tears at the ligament's insertion on the sustentaculum tali or the navicular.[3] The ligament does not appear lax. A grade 2 tear was described as a loose ligament that appears stretched, with or without visible tears in the mid-substance or the insertion site.[3] A grade 3 tear was a complete rupture of the ligament.[3]

Co-morbidities

In addition to the extent of SL tear, age, obesity, and other medical conditions play a significant role in selecting the treatment for SL tears. In patients with isolated SL rupture due to physical traumatic injuries, conservative treatment can be sufficient. Tryfonidis et al. reported that in six patients

Article	Method of Diagnosis	Diagnostic Criteria
Lee et al.	MRI and X-rays	- MRI-confirmed SL tear - X-rays : talar head adduction and plantarflexion
Choi et al.*	Cadaveric study	- Deformity models were created by sectioning the medial talonavicular joint capsule, the superomedial fibers of the SL, and the interosseous ligament
Williams et al.	Intraoperative	- Persistent talonavicular abduction or talonavicular sag after bony procedures
Palmanovich et al.	Intraoperative	- Complete tear : exposed talar head with foot abduction. - Attenuation : mild protrusion of the talar head during foot abduction
Acevedo et al.	Clinical and Radiographic	- Not mentioned

Table 2. *Methods of SL tear diagnosis used in the articles discussed and the specific diagnostic criteria each article used to determine the need for SL reconstruction*

where comorbidities and weight were not a factor, early conservative intervention through the use of foot orthoses proved to be sufficient for relieving symptoms of pain.[7] On the other hand, in the article by Williams et al., thirteen patients with a mean age of 63.5 years failed to respond to conservative treatment and required surgical reconstruction of the ligament. In cases where comorbidities and obesity were significant factors, patients were more likely to undergo more extensive surgical procedures. For example, in a case report by Weerts et al., soft tissue procedures and conservative therapies were not used in a 43 year old diabetic male with a BMI of 34.1.[8] Instead, surgical intervention for this patient included a talonavicular arthrodesis with a gastrocnemius slide instead of a SL reconstruction.[8] The timing of treatment also plays a big role in preventing the need for surgical intervention. Tryfonidis et al. reported a case of a 43 year old woman, with rheumatoid arthritis and bilaterally ruptured SL, where conservative treatment alone was sufficient due to early intervention.[7] All the various papers included in this systematic reviews failed to standardize or consider the duration of symptoms, weight, age, other medical conditions, and timing of treatment intervention while analyzing the data.

Short term results

In the study by Lee et al,, the AOFAS score improved significantly from a short term assessment at approximately 8.2 months.[4] Additionally, clinical and radiographic results improved significantly. In the study by Choi et al., the superomedial approach and plantar approach demonstrated relative improvements at the talonavicular joint through correction of talonavicular adduction. However, there was not any significant improvement in subtalar eversion following the superomedial approach and the plantar

approach. Acevedo et al. anecdotally reported that the improvement in foot position after SL repair has been greater than what would be expected with medializing calcaneal osteotomy and flexor tendon transfer alone.[1] The authors also reported results of radiographic correction of talonavicular uncoverage and medial column sag as well as improved clinical alignment.[1]

Long-term results

Williams et al. was the only study included in this systematic review that provided long term results with an average follow-up of 8.9 years post-surgery. At the end of the follow up period, the authors reported a number of significant findings. The AOFAS ankle-hindfoot score increased significantly by 47.2 points. [9] The postoperative FAOS average pain scale was 83.7. The AP first tarsometatarsal angle, talonavicular coverage angle, lateral calcaneal pitch, and lateral talonavicular angle improved significantly and were within normal ranges postoperatively.[9] The mean hindfoot alignment measured 2.7 degrees of valgus.[9] Some of the complications from surgery included pain upon palpation of the SL and pain over the sinus tarsi, which was experienced by a few patients.

Follow-up

The postoperative management is an important factor in the long term success of the surgical procedures. All the studies recommended immobilization in a solid below knee cast followed by a course of physical therapy. On average, the recommended non-weightbearing follow-up time was 9 months followed by physical therapy. Both Williams et al. and Acevedo et al. recommended that each patient stayed non-weightbearing for 12 weeks in a cast, followed by physical therapy. On the other hand Palmanovich et al. and Lee et al. recommended a shorter 6 week period of immobilization.

SL Reconstruction procedural theory

Lee et al. used the FHL tendon for SL reconstruction due to its similarity of origin and function with the PT tendon. Both, FHL and PT muscles originate from the deep posterior compartment and function to plantarflex the ankle.[4] The FHL graft provides maximum static support of the arch and dynamically stabilizes the midfoot.[4] The Combined Superomedial/Plantar technique using the PL was another valid technique as it anatomically replicates the plantar and superomedial fibers of the SL complex. This technique is mechanically effective as it reinforces the medial aspect of the talonavicular joint and blocks the talar head from plantarflexion and adduction. The success of SL reconstruction in establishing the MLA was measured clinically using the post-op FAOS pain score and talar head adduction. Radiographically the AP first tarsometatarsal angle, talonavicular coverage angle, medial column sag, lateral calcaneal pitch were among the measurement modalities used to determine the post reconstruction maintenance of MLA. Due to the variability in reconstruction techniques and post reconstruction evaluation of MLA, quantitative analysis between studies is not possible.

CONCLUSION

The anatomical reconstruction of the SL is of utmost importance for the continued maintenance of MLA. Of the various techniques described in literature, FHL and

PL tendon transfers have demonstrated to provide adequate stability of MLA and are reliable options in SL reconstruction surgery. Considerable variability in modalities used in assessing the grade of spring ligament tear and maintenance of MLA post reconstruction have made it difficult to compare the results across the different studies. Lack of control groups, inconsistency in grading methods for SL tears and MLA maintenance, and small sample sizes make it difficult to compare the efficacy of each of these procedures. Different methods of spring ligament augmentation can provide efficacious results depending on the extent of the SL tear, comorbidities present and the adjunct procedures performed. Although the PL tendon procedure demonstrated adequate long term results, no one particular technique has shown consistent clinical results. In patients where comorbidities and weight were not a factor, early conservative intervention proved to be sufficient for relieving symptoms of pain.[7] Future clinical studies with consistent patient selection, long term follow-up and control groups are necessary to provide a viable and reliable method for reconstruction of SL.

AUTHORS' CONTRIBUTIONS

GR, AA, and IA equally contributed towards the design of the study and evaluated the available articles.

STATEMENT OF COMPETING INTERESTS

The authors declare that they have no competing interest associated with this manuscript.

REFRENCES

1. Acevedo J, Vora A. Anatomical Reconstruction of the Spring Ligament Complex: "Internal Brace" Augmentation. *Foot & Ankle Specialist/* 2013; *6*(6): 441-445.
2. Choi KJ. Anatomical reconstruction of the spring ligament using peroneus longus tendon graft. *Foot Ankle Int.* 2003; *24*: 430-436.
3. Gazdag AR, Cracchiolo A. Rupture of the tibial tendon: Evaluation of injury of the spring ligament and clinical assessment of tendon transfer and ligament repair. *J Bone Joint Surg Am. 1997; 79*: 671-681.
4. Lee W., Yi Y. Spring Ligament Reconstruction Using the Autogenous Flexor Hallucis Longus Tendon. *Orthopedics.* 2014*; 37*(7): 467-471.
5. Palmanovich E, Shabat S, Brin YS, Feldman V, Kish B, Nyska M. Anatomic Reconstruction Technique for a Plantar Calcaneonavicular (Spring) Ligament Tear. *The Journal of Foot and Ankle Surgery.* 2015; *54*(6): 1124-1126.
6. Taniguchi A. Anatomy of the spring ligament. *The Journal of Bone & Joint Surgery. 2003; 85*(11): 2174-2178.
7. Tryfonidis M, Jackson W, Mansour R, Cooke P, Teh J, Ostlere S, Sharp R. Acquired adult flat foot due to isolated plantar calcaneonavicular (spring) ligament insufficiency with a normal tibialis posterior tendon. *Foot and Ankle Surgery.* 2008; *14*(2): 89-95.
8. Weerts B, Warmerdam PE, Faber FW. Isolated Spring Ligament Rupture Causing Acute Flatfoot Deformity: Case Report. *Foot Ankle Int Foot & Ankle International.* 2012; *33*(2): 148-150.
9.Williams BR, Ellis SJ, Deyer TW, Pavlov H, Deland JT. Reconstruction of the Spring Ligament Using a Peroneus Longus Autograft Tendon Transfer. *Foot & Ankle International.* 2010; *31*(7): 567-577.
10. Williams G, Widnall J, Evans P, Platt S. Could Failure of the Spring Ligament Complex Be the Driving Force behind the Development of the Adult Flatfoot Deformity? *The Journal of Foot and Ankle Surgery.* 2014; *53*(2): 152-155.

The Apert Foot: Anatomy and Management

James H. Chung, BS and Hye Jin Yoo, BS

Abstract

Introduction
Apert syndrome, or acrocephalosyndactyly type 1, is a rare and complex congenital condition that is characterized by the premature fusion of the skull's coronal sutures and complex anomalies of the hands and feet. The majority of the literature pertaining to Apert syndrome has concentrated on the upper limb and craniofacial malformations, with scant regard to the foot defects. Although the care of the Apert foot is not essential for life, it is a critical component in the current multidisciplinary management strategy to achieving optimal function, social normalization, and quality of life. Therefore, the goal of this study is to investigate the podiatric manifestations of Apert syndrome and its current management options.

Study Design: Qualitative systematic review of the literature

Methods
A literature search of PubMed was conducted utilizing the key words "Apert" in the title, "and" as the Boolean operator, and "foot" in all fields. This search yielded 16 articles. An additional search was performed on ScienceDirect employing the same search terms and Boolean operator and yielded 31 articles when the topic selected was "Apert syndrome." Articles pertaining to the podiatric manifestations of Apert syndrome and its management were included in the study. Articles published prior to 1990 were excluded from the study. After careful analysis of the articles yielded, 7 articles were selected for this literature review. The reference lists of the selected articles were investigated to further increase the authors' knowledge of the topic at hand.

Results
The anatomical features are predictable when progressive changes in osseous and soft tissue follow a consistent pattern of syndactylization. The conservative management is composed of callus debridement and orthotics with accommodative shoe gear. The surgical treatment includes functional osteotomies and desyndactylization in 2 stages. There are many different procedures of functional osteotomies and arthrodesis to correct the specific deformities: distraction osteogenesis for brachymetatarsia and medial angulation of hallux, oblique/basal metatarsal osteotomies for painful callus, resection of first and second ray with reconstruction for hallux, and fifth metatarsal osteotomy or arthrodesis for supination deformity.

Conclusion
Regardless of the obvious anatomical features, the evaluation must include a radiographic examination to detect any additional abnormalities. The current treatment requires a multidisciplinary approach as the individual with Apert syndrome needs different parts of systematic care. The podiatric treatment is focused on improving the functional outcome by early surgical intervention. Further research on desyndactylization is warranted to determine its benefits.

Key Words Apert syndrome, acrocephalosyndactyly type 1, Apert foot

Level of Evidence: 4

INTRODUCTION

Apert syndrome, or acrocephalosyndactyly type 1, is an uncommon and complex congenital condition first described by French pediatrician Eugene Apert in 1906.[1,2] It is a rare variant of craniosynostosis that is not only characterized by the premature fusion of the skull's coronal sutures, but also by complex anomalies of the hands and feet.[3] This distinguishes Apert syndrome from other forms of acrocephalosyndactyly as the condition displays syndactyly in addition to cranial elongation.[3] Although Apert syndrome is rare, it is the most severe and the most common of the craniosynostoses with estimated incidences varying from 1 in 65,000 to 1 in 160,000 live births.[4,5,6,7,8] It occurs with equal frequency in males and females and is linked to increased paternal age when inherited in an autosomal dominant manner.[7,8,9] It can also be caused by a *de novo* mutation in the male gamete by a missense substitution of the fibroblast growth factor receptor-2 (FGFR2) gene at two specific amino acid positions (Ser252Trp and Pro253Arg) on chromosome 10q.[8,10] The diagnosis of Apert syndrome is most often at birth.[4]

The majority of the literature regarding Apert syndrome has concentrated on the upper limb and craniofacial malformations, with little attention to the foot defects. As the treatment of the upper limb and craniofacial defects has improved, the life expectancy for these patients has increased leading to increased demands on the feet in Apert syndrome patients.[4,8] Although the care of the Apert foot is not essential for life, it is a critical component in the current multidisciplinary management strategy to achieving optimal function, social normalization, and quality of life.[4,8] Thus, the purpose of this literature review is to recognize the consistent podiatric manifestations of Apert syndrome and investigate its current management options.

METHODS

A literature search of PubMed was conducted utilizing the key words "Apert" in the title, "and" as the Boolean operator, and "foot" in all fields. This search yielded 16 articles. An additional search was performed on ScienceDirect employing the same search terms and Boolean operator and yielded 31 articles when the topic "Apert syndrome" was selected. Articles pertaining to the podiatric manifestations of Apert syndrome and its management were included in the study. Articles published prior to 1990 were excluded from the study. After careful analysis of the articles yielded, 7 articles were selected for this literature review. The reference lists of the selected articles were investigated to further increase the authors' knowledge of the topic at hand.

RESULTS

The Apert Foot

The literature suggests that the podiatric deformity in Apert syndrome is one that is characteristic and predictable in a progressive and consistent pattern and commonly bilateral and symmetric (Figure 1).[1,11] The osseous changes associated with the first ray are particularly significant when recognizing the Apert foot. Mah et al. first reported the proximal phalanx of the hallux as having a delta-shaped appearance, with the base oriented laterally and the apex medially.[1] This delta phalanx contributes to the progressive medial deviation of the hallux (Figures 2 and 3). The first metatarsal displays either a single or bifid base proximally, but always a single metatarsal head distally.[1] As the child ages, the hallux will appear progressively shorter due to osseous fusion of the delta phalanx and distal phalanx at the level of the proximal interphalangeal joint (PIPJ).[1,4] Shortening of the hallux commonly occurs in a varus and dorsiflexed position.[11] These anatomical defects of the great toe lead to the classical

Fig 1. Dorsal view of the Apert foot (Photograph courtesy of Dr. Barbara Resseque, DPM)

first ray insufficiency seen in patients with Apert syndrome.

At birth, skeletal structures demonstrate clear segmentation of ossification centers, but progressive joint fusions are observed in the Apert foot with increasing age.[1,3] Based on the literature, there is not any single pattern or rate of fusion but it is certain that the Apert foot will demonstrate fusions that are progressive in nature.[4] Synostosis usually begins in the hindfoot and progresses to involve the midfoot and metatarsal shafts as the child ages, eventually involving fusion of all of the interphalangeal joints.[1,12] This results in a more rigid foot with less range of motion. A former study by Mah et al. found an absence of the distal phalanx in all of the lesser toes, while a more current study by Anderson et al. reported an absence of the middle phalanx in all lesser toes due to the fusion of the interphalangeal joints.[1,12] In regard to fusion of the hindfoot and midfoot, it seems to be universally accepted that the talonavicular joint is spared and unaffected.[1,4,13] Although the talonavicular joint does not seem to be involved in fusion, it is still reported to exhibit no clinical motion.[1] The progressive hindfoot and midfoot fusions tend to place the foot in a supinated position, although the Apert foot can be in a pronated position less frequently .[1,3,4] In the literature reviewed, there was only one case of Apert syndrome in which there was an additional metatarsal bone in each foot.[4,14]

Type 1	Type 2	Type 3
Fusion of digits 2-4 with digit 1 and 5 separate	Fusion of digits 2-5 with digit 1 separate Variant: partial plantar syndactyly of digit 5	Fusion of all digits, 1-5

Table 1. Classification of syndactylism in the Apert foot by Blauth and von Torne and Cohen and Kreiborg

Upton established a radiographic distinction between two basic foot patterns in patients with Apert syndrome: type I and type II.[3,15] Type I feet are less symptomatic and described as having cuneiform bones that are well segmented from the first metatarsal at birth. The proximal phalanx of the hallux is abnormal, leading to an abnormally large distal phalanx that deviates medially. With growth, the hallux becomes relatively shorter, but sufficient length is maintained by a relatively normal first metatarsal. Type II feet have more clinical symptoms and display a short first metatarsal with a bifid origin proximally from multiple cuneiforms and a single metatarsal head distally. The first metatarsal is commonly coalesced with the navicular, and also forms a complete or partial side-to-side synostosis with the second metatarsal. The delta phalanx may also fuse side-to-side with the second ray. As a result, growth of the first ray is more restricted than in type I feet and there is a higher degree of medial deviation of the hallux. [3,15]

As mentioned previously, the major characteristic that clinically distinguishes Apert syndrome from other forms of acrocephalosyndactyly is syndactyly of the digits. [3,4] Syndactyly is always present in the Apert foot.[4] The literature provides a classification of three distinct patterns of syndactylism by Blauth and von Torne, and Cohen and Kreiborg: type I, type II, and type III (Table 1).[3,13,16] Type I feet have fusion of digits 2-4, with the digits 1 and 5 being separate. Type II feet consists of fusion of digits 2-5, with digit 1 separate in a varus and dorsiflexed attitude. A variation of type II displays separation of digit 5, but only on the plantar aspect. Type III feet involve fusion of all digits.[3,13,16] However, Wylie cautions that this classification system is not all-encompassing as syndactyly is highly variable and may be expressed in other ways.[4]

The Apert foot demonstrates associated nail and soft tissue changes. The normal development of the nail plate is disrupted due to syndactyly of the digits.[17] Mah et al. describes the nail of the hallux as vertically oriented, irregular, and brittle, while the lesser toenails are curled in a plantarward fashion.[1] The toenails may be syndactylized or completely separate.[1,4] The nails of the Apert foot may also be short, display an absence of lunulae, and exhibit micronychia.[17] A change in weight bearing pattern due to altered foot biomechanics will generate painful hyperkeratotic lesions in characteristic locations. In a more mobile and pronated Apert foot, a callus will develop under the second metatarsal head.[18] In the more classical rigid and supinated Apert foot, a callus develops along the lateral border of the foot and under the fifth and third metatarsal heads.[1,18]

Management

Treatment options for the Apert foot include both conservative and surgical methods. Conservative methods consist of the debridement of painful callosities and nails, the use of foot orthoses and accommodative shoe wear.[1,3,11] Mah et al. advocate that foot orthoses be the minimum standard of care for the Apert foot and should be used in all

Fig 2. Plantar view of the Apert foot revealing the hyperkeratotic lesions (Photograph courtesy of Dr. Barbara Resseque, DPM)

patients as they help to redistribute weight-bearing pressures over areas of hyperkeratoses.[1] The literature suggests that complications with foot wear due to the great toenail is a universal finding among patients with Apert syndrome.[4,12] Therefore the great toenail should be carefully scrutinized to prevent paronychial infections on the medial border of the nail secondary to ingrowth or tight footwear.[1] Soaking of the toenail before debridement, avulsion of the nail, and ablation of the nail matrix are suggested solutions.[1,4,11]

Historically, only patients who remained symptomatic after failed conservative methods were considered for surgery, but according to the current literature there is now a trend towards earlier surgery in patients with Apert syndrome.[2,4,12] Surgical procedures include syndactyly release, metatarsal osteotomies, midfoot osteotomies, phalangeal osteotomies, triple arthrodesis, and distraction osteogenesis.[1,4,19] Fearon proposed a two phase approach (early phase and late phase) to the treatment of the Apert foot in a manner that maximizes the final results while minimizing the total number of operations.[2] The early phase is a two-stage syndactyly release of all 10 fingers and toes with the first stage performed at 9 to 12 months and the second stage performed 3 months later.[2] The late phase is initiated when the child is between the ages of 9 and 12 and consists of functional osteotomies of the metatarsals and midfoot.[2] To address a hallux deformity in which it is of sufficient length, an osteotomy of the proximal phalanx is performed along with resection of the intermetatarsal bony bridge and basal metatarsal osteotomy.[3,11] If the hallux is shortened, resection of the first or second ray with reconstruction is performed. An alternative procedure to this is a medial capsulotomy of the first metatarsophalangeal joint with resection of any bony or cartilaginous piece.[16] Mah et al. reported two cases of triple arthrodesis to address severe

Fig 3. (a) AP radiograph of the Apert foot demonstrating the bifid base of the first metatarsal. **(b)** Medial oblique view. (Radiographs courtesy of Dr. Barbara Resseque, DPM)

supination deformity.[1] A recent study by Calis et al. utilizes distraction osteogenesis technique to correct the brachymetatarsia of the first metatarsal and medial angulation of the hallux.[19] After a latency period of 5 days, the distraction is initiated at a rate of 0.5 mm/d and the distractors are removed once the desired length and correction are achieved.[19] Management of the patient with Apert syndrome calls for a multidisciplinary approach to simplify therapy for the patient while decreasing their operative burden.[4,8]

DISCUSSION

Anatomical features

Several clinical symptoms may be observed due to the anatomical features of the Apert foot. First, there is alteration of the biomechanics of foot function. With continuing fusion of the bones of the hindfoot and midfoot until maturity, the foot becomes more rigid and supinated. This change is associated with decreased shock absorbing capabilities..[1,4] With the rigid supination deformity and shortened first ray, the normal push-off over the medial side of the foot during the gait cycle will be prevented.[1] Additionally, the midfoot fusions cause a decreased range of motion at the ankle joint. The rigid deformity of the condition does not allow the normal weight transfer between the ankle, hindfoot, and forefoot. Wylie asserted that although Apert syndrome is most commonly associated with the more supinated foot, there can also be a pronated foot type associated with this syndrome. The pronated foot type may be problematic as it results in a more mobile foot, placing more stress under the second and third metatarsals than would occur in the normal or more supinated foot.[4] This anatomical pathology may eventually lead to cortical hypertrophy of the affected metatarsals and complicate the management.

Due to the altered biomechanics of the Apert foot, characteristic hyperkeratotic lesions develop (Figure 2). The shortened first metatarsal becomes less functional. As a result, forces are transferred to the second

Life period	Surgical treatment
Within two years	Emergencies Cranioplasty Cleft Palate Correction Hand surgery
Growth period	Middle third correction (Orbital region) Strabismus Correction Hand and Foot Surgery Orthodontic Treatment
End of growth	Inferior Third Correction (Orbital region) Individualized Surgery Ancillary Techniques

Table 2. Surgical timing in Apert syndrome[8]

metatarsal which causes the development of a pathological callus called a transfer callus.[3,4] Gait analysis of the supinated foot type indicates increased weight bearing forces on the lateral aspect of the foot, developing plantar callosity under the fifth ray.[1] Therefore, altered foot mechanics leading to altered weight bearing patterns produce painful calluses in these patients.

A prominent concern associated with the Apert foot deformity is footwear problems. Hallux varus with a widened distal phalanx, along with a broad and short first metatarsal proximally fused to the second metatarsal, cause difficulty with shoe gear. Ill-fitting shoes may cause tightness on the medial border of the hallux, which may result in a paronychia infection. Mah et al. reported that one patient ultimately had an amputation of the great toe due to complications from this problem.[1]

Radiographs

Wylie highlights the importance of radiographic examination. Wylie suggests that even in the presence of the outward clinical appearance of the Apert foot, radiographic examination should be performed to detect any undocumented features in order to properly address all deformities.[1,4] Anderson et al. supports this notion based on the finding of additional metatarsal bones in a case study of Apert syndrome.[14]

Management

In the past three decades, conservative treatment with orthotic therapy has been the main focus of the management of the Apert foot.[4] The goal of the treatment is to

effectively redistribute weight as well as reduce pain over the hyperkeratotic lesions with proper shoe gear, orthotics, and management of abnormal nails.[12] However, Wylie states that this conservative treatment should be considered a minimum standard of care, not a primary management. With more in-depth understanding of the syndrome and advanced surgical techniques, there is a shift towards more aggressive surgical management. The goal of surgical management is to provide functional improvement with earlier foot surgery. In cases of recurrent paronychias, total nail avulsion with ablation of the nail matrix is indicated. Osteotomies at the midfoot level are becoming more popular in hopes of providing a more permanent relief of the problems due to plantar callosities.[11] Currently, there is controversy regarding the benefits of desyndactylization of all toes since syndactyly release is not the current standard of care. Fearon states that with his 2-stage method of syndactyly release the patient will not gain functional benefit, but will gain psychological benefits by improving the patient's own body image. Thus, Fearon believes aggressive syndactyly release of all toes helps to normalize the patient's quality of life.[2] However, opponents of Fearon state that the decision to perform aggressive surgical interventions such as desyndactylization should be based solely on functional improvement, rather than cosmetic improvement.[12] With desyndactylization, more studies are required to investigate the functional and cosmetic benefits along with the appropriate timing of the operation.

Many authors uniformly recommend taking a multidisciplinary approach in managing Apert syndrome: respiratory, cerebral, maxilla-mandibular, dental, ophthalmic, and orthopedic.[2,8,15] Fadda et al. suggest that treatment timing is crucial in managing Apert syndrome, not only due to the complexity of the syndrome, but also due to the reduced intellectual capacity associated with the varying degrees of mental and developmental delays present in this syndrome. Thus, Fadda et al. recommend a treatment algorithm in accordance with the patient's age. According to Table 2, hand and foot surgery is performed during the "growth period." The "growth period" ranges from ages 2 to 12, but Fadda et al. recommend hand and foot surgery once the patient is 4-5 years of age. This is slightly different than Fearon, who believes 9-12 years of age is the optimum time for functional osteotomies of the metatarsals and midfoot.

CONCLUSION

Apert syndrome is a complex congenital condition consisting of a rare variant of craniosynostosis with distinguished syndactylization. With greater understanding of the condition, the improvements to the management of craniofacial and upper limb malformations have increased the life expectancy of these patients. Naturally as these patients live longer, the demands on their feet will also increase. The clinical symptoms resulting from the characteristic anatomical features of the Apert foot are pain, rigidity of the foot due to fusion, callus formation, and shoe gear problems. Thorough evaluation of these patients should include radiographic examination to detect any additional abnormalities. Currently there is no established minimum standard of care for the Apert foot, although it is widely accepted that foot orthotics be used by all patients. The current trend in the treatment of the Apert foot is early surgical intervention to improve the functional outcome. Surgical procedures include syndactyly release, metatarsal osteotomies, midfoot osteotomies, phalangeal osteotomies, triple arthrodesis, and distraction osteogenesis. However, more investigations are needed to determine the efficacy of conservative and surgical treatment of the Apert foot. The benefits of desyndactylization and its place in the current treatment algorithm in the multidisciplinary approach must be further examined as well.

Future studies can help establish a minimum standard of care clinicians can utilize to guide their treatment plan for the feet in Apert syndrome.

AUTHORS' CONTRIBUTIONS

The authors (JC and HY) equally contributed to the construction of this manuscript. The authors would also like to thank Dr. Barbara Resseque, DPM for contributing clinical photographs and radiographs.

STATEMENTS OF COMPETING INTERESTS

The authors (JC and HY) declare no competing interests in relation to this manuscript.

REFERENCES

1. Mah J, Kasser J, Upton J. The Foot in Apert Syndrome. *Clin Plastic Surg.* 1991;18: 391-97.
2. Fearon JA. Treatment of the Hands and Feet in Apert Syndrome: An Evolution in Management. *Plast Reconstruc Surg.* 2003; 1-12.
3. Carranza-Bencano A, Gomez-Arroyo JA, Fernandez-Torres JJ, Corral FM. Foot Deformities Associated with Apert Syndrome. *J Podiatr Med Med Assoc.* 2000; 90: 322-4.
4. Wylie GH. Anatomy and Management of the Foot in Apert Syndrome: A Review of the Literature. *Foot*. 2006; 16: 98-102.
5. Czeizel AE, Elek C, Susanszky E. Birth Prevalence Study of Apert Syndrome. *Am J Med Genetics*. 1993; 45: 392.
6. Cohen MM, Kreiborg S. The Central Nervous System in the Apert Syndrome. *Am J Med Genetics.* 1990; 35: 36-45.
7. Tolarova MM, Harris JA, Ordway DE, Vargervik K. Birth Prevalence, Mutation Rate, Sex Ratio, parents' Age, and Ethnicity of Apert Syndrome. *Am J Med Genetics*. 1997; 72: 394.
8. Fadda MT, Ierardo Gaetano, Ladniak B, Giorgio GD, Caporlingua A, Raponi I, Silvestri A. Treatment Timing and Multidisciplinary Approach in Apert Syndrome. *Ann Stomatologi*a. 2015; 6: 58-63.
9. Erickson JD, Cohen MM. A Study of Paternal Age Effects on the Occurrence of Fresh Mutations for the Apert Syndrome. *Ann Hum Genetic*s. 1974; 38: 89.
10. Ciurea AV, Toader C. Genetics of Craniosynostosis: Review of the Literature. *J Med Life*. 2009; 2: 5-17.
11. Grayhack JJ, Wedge JH. Anatomy and Management of the Leg and Foot in Apert Syndrome. *Clin Plast Surg*. 1991; 18: 399-405.
12. Anderson PJ, Hall CM, Evans RD, Hayward RD, Jones BM. The feet in Apert's Syndrome. *J Paediatr Orthopaed*. 1999; 19: 504-7.
13. Cohen MM, Kreiborg S. Hands and Feet in Apert Syndrome. *Am J Med Genetics*. 1995; 57: 82-96.
14. Anderson PJ, Smith PJ, Jones BM, Hayward RD. Additional Metatarsal Bones in Apert's Syndrome. *Foot.* 1996; 6: 37-8.
15. Upton J. Treatment of the hands and feet in Apert Syndrome: Discussion: An evolution in Management. *Plast Reconstruct Surg.* 2003; 112: 13-9.
16. Blauth W, von Torne O. Apert's Foot. *Z Orthop*. 1978; 116: 1.
17. Rogers M. Nail Manifestations of some Important Genetic Disorders in Children. *Dermatol Ther*. 2002; 15: 111-20.
18. Mason WH, Wynmore M, Berger E. Foot Deformities in Apert's Syndrome: Review of the Literature and Case Reports. *J Podiatr Med Assoc*. 1990; 80: 540-4.
19. Calis Mert, Ozmur A, Ekin O, Vargel I. Correction of Brachymetatarsia and Media Angulation of the Great Toe of Apert Foot by Distraction Osteogenesis: A Review of 7 Years of Experience. *J Pediatr Orthop*. 2015; 1-7.

A Systematic Review of Mesenchymal and Amniotic Stem Cell Therapy of Achilles Tendinopathies

Sirisha V. Pokala, BS, and Sahar R. Zadeh, BS

Abstract

Introduction: Tendinopathies are considerably common and can cause disabilities and challenges to patients. Due to the high amount of force from the muscle to the bone, tendons can be easily injured. Many different types of injuries to the Achilles tendon result in tendinopathies, such as a tear or a rupture, inflammation, and degeneration due to overuse. The delivery of human cells from amniotic tissue and bone marrow are both innovative treatments for repairing the Achilles tendon. Utilizing these methods may solve the problems that patients with tendinopathy have because stem cells have the potential to proliferate while differentiating into specific tissue lineages. The types of stem cells used to research regeneration of the Achilles tendon include allogenic tenocytes, adult mesenchymal stem cells, embryonic, fetal, and placental stem cells. The purpose of this systematic review is to demonstrate that amniotic treatment and mesenchymal stem cells can be utilized for Achilles tendon injuries.

Methods: For research articles on amniotic stem cell therapy, a search in PubMed and Cochrane of “amniotic” AND “Achilles tendon” OR “Calcaneal tendon” was performed. Out of 14 articles, 3 met the inclusion/exclusion criteria. For research articles on mesenchymal stem cell therapy, 57 articles were found on PubMed and 4 met the inclusion and exclusion criteria. The inclusion criteria was amniotic stem cell therapy, Achilles tendon therapy, Achilles tendon repair, mesenchymal stem cell therapy, papers published after 2010. The exclusion criteria was papers published in a language other than English and review articles.

Results: A Cochrane and PubMed search generated a total of 75 articles, with 7 articles meeting the inclusion and exclusion criteria. The articles on mesenchymal stem cell therapy and amniotic stem cell therapy concluded that both types of treatment, mesenchymal and amniotic stem cell therapy, exhibit promising results in Achilles tendon healing with significant improvement in tendon strength.

Conclusion: The reviewed literature found that amniotic stem cell therapy and mesenchymal stem cell therapy could both be good approaches in healing of the Achilles tendon. Amniotic stem cell therapy is a new approach and although it needs to be researched more in order to confirm results, it shows a promising future in tendinopathy reconstruction.

Keywords: mesenchymal, stem cell therapy, amniotic, Achilles tendon

Level of Evidence: 4

INTRODUCTION

The Achilles tendon, or calcaneal tendon, is the biggest and strongest tendon in the human body. It transfers force from the contraction of the soleus and gastrocnemius muscles to plantarflex the ankle. It is essential in gait and maintaining an upright position while standing. Although the Achilles tendon is important in the biomechanics and locomotion of the lower extremities, its considerable avascularity makes the tendon vulnerable to force-induced injuries[1]. Tendinopathies are common and can cause disabilities and challenges to patients both physically active and inactive.

Many different types of injuries to the Achilles tendon result in tendinopathies, such as a tear, rupture, inflammation, or degeneration due to overuse. Current treatments used to repair and/or alleviate pain for these conditions are NSAIDs, physical therapy, corticosteroids, growth factors and surgery.[2] The newest treatment investigated is the placement or injection of stem cells which proliferate into tenocytes to enhance healing quality and speed.

The use of stem cells has shown to significantly improve biomechanics of tendinopathies in many parts of the body, such as in patellar and digital flexor tendons.[3,4] The treatment has become introduced as a therapy for Achilles tendinopathy in recent research. The types of stem cells used to research regeneration of the Achilles tendon include allogeneic tenocytes, mesenchymal stem cells, embryonic, fetal, and placental stem cells.

Mesenchymal cells are multipotent cells which can be derived from numerous mesenchymal tissues, including bone marrow, tendon, muscle and adipose tissue. Bone marrow mesenchymal stem cells (BMSCs) differentiate into osteocytes, chondrocytes, myocytes and adipocytes.[5] BMSCs do not have MHC-II expression, poor T cell rejection mechanisms, and secrete anti-inflammatory mediator; this makes them ideal for allogeneic procedures.[7]

Amniotic stem cells,also called Amniotic Mesenchymal Stromal cells (AMSc), are derived from umbilical cord blood, amniotic fluid and amnion membrane of placentae. Amniotic stem cells can be sources of different populations of stem cells including mesenchymal, hematopoietic, trophoblastic and, possibly, of more primitive stem cells.[6] AMSc are positive for CD90, CD44, CD105, and negative for CD34, CD14 and CD45.[7] They have low immunogenicity and the ability to induce immuno-tolerance.[7] Amniotic Epithelial Cells (AECs), obtained from the amniotic membrane of horses, can differentiate into bone tissue and tendon tissue, both in vitro and when implanted into live animals.[8] The delivery of amniotic tissue and of bone marrow are both innovative treatments that can be used alone or in combination with other treatments for repairing the Achilles tendon.

In this qualitative review the effectiveness amniotic stem cells and mesenchymal stem cells as alternative treatments for tendinopathies is assessed in terms of healing time and strength of the healed tendon.

METHODS

Two English language literature searches were administered using Pubmed databases. The first search was conducted using the Boolean operators “and” and “or” for the terms “amniotic” AND (“Achilles tendon” OR ”Calcaneal tendon”). This search yielded 115 articles. Inclusion criteria included articles published after 2010, Achilles tendinopathy, Achilles tendon therapy, Achilles tendon repair, amniotic stem cell therapy, in vivo studies, amniotic cell derivatives, and treatments directly injected into tendon. Exclusion criteria included review articles and

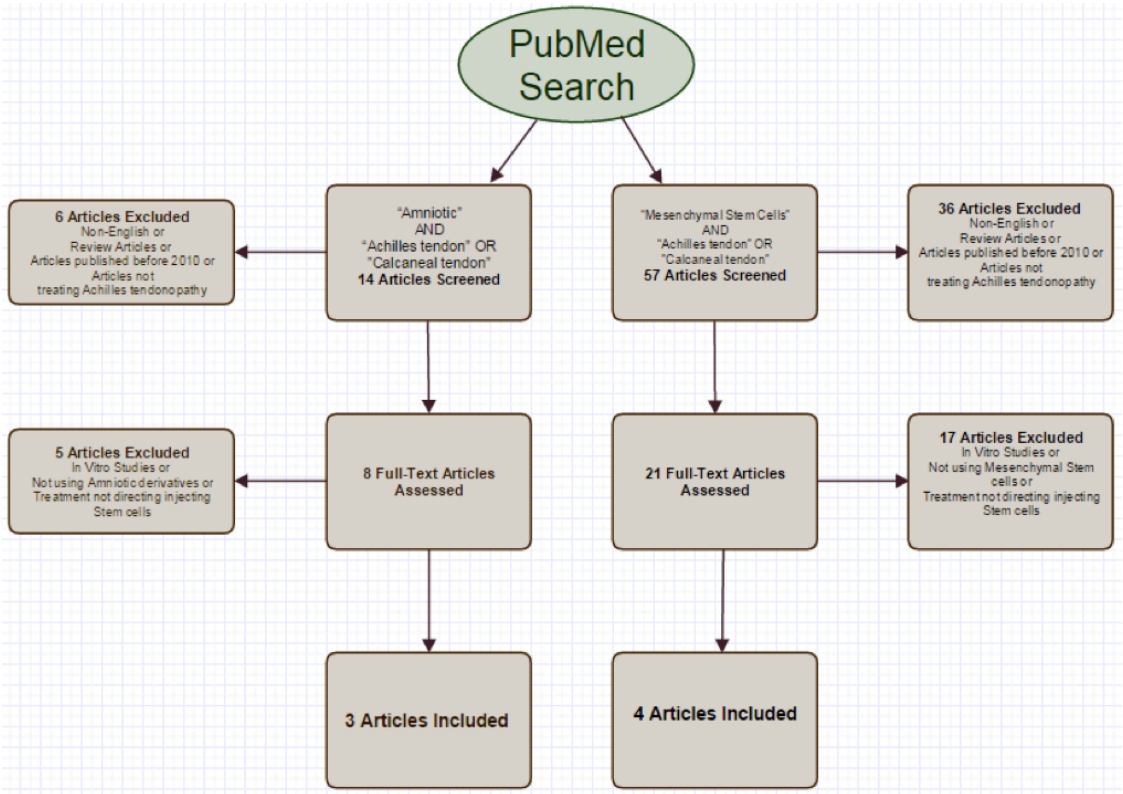

Fig. 1 Methods Flow Chart

articles not in English. After reviewing papers, 11 of the 14 articles were excluded.

The second search was conducted using the Boolean operators "and" and "or" for the terms "Mesenchymal stem cells" AND ("Achilles tendon" OR "Calcaneal tendon"). The search yielded 57 articles. Inclusion criteria included articles published after 2010, and the words Achilles tendinopathy, Achilles tendon therapy, Achilles tendon repair, mesenchymal stem cell therapy, in vivo studies, and treatments directly injected into tendon. Exclusion criteria included review articles and articles not in English. After assessing the articles, 53 out of the 57 were excluded. A total of 7 articles met the inclusion and exclusion criteria.

RESULTS

Of the studies regarding amniotic stem cell treatment of the Achilles tendon, three studies pertained to the direct injection of amniotic cells into the Achilles tendon. A study conducted to treat Achilles tendonosis with allogenic amniotic tissue included patients with long standing Achilles pain that persisted despite many different types of therapy, such as physical therapy and orthotics.[9] The fourty-four patients chosen had an MRI that confirmed lack of rupture. 1 mL of PalinGen SportFlow, a human allograft, and 1 mL of 1% lidocaine were drawn into a syringe. For all the patients, 0.5 mL of amniotic fluid was deposited along the medial side of the paratenon. The rest was deposited along the posterolateral aspect of the Achilles tendon. Afterwards, patients were instructed to stretch every half hour and wear stable shoes. The visual analog scale was used to measure pain in the patients. Before the allograft was injected, patients had an average pain scale of 8.2 out of 10, indicating severe pain. Six weeks after the operation, the average pain score was reduced to 4.7 out of 10. By twelve weeks after the operation, the average pain score was 2.3 out of 10. The post-procedure pain

Table 1: Significant Variables of Amniotic Stem Cell Studies

Study	Statistically Significant Variables
Werber et al[9]	Pain Scale was reduced, ($p < 0.001$)
Kueckelhaus et al[10]	Breaking strength, ultimate tensile strength, yield strength, and Young's modulus ($p < 0.05$)
Philip et al[11]	Cross-sectional tendon area

Table 2: Significant Variables of Mesenchymal Stem Cell Studies

Study	Statistically Significant Variables
Al-ani et al[12]	None
Vieira et al[13]	Structural organization ($p < 0.05$)
Schon et al[14]	Collagen Synthesis ($p < 0.05$)
Machova et al[15]	Histology Score, higher cellularity ($p < 0.05$)

reduction from the allograft operation was significant ($p < 0.001$).[9]

In another study conducted on rats to determine the effect of amniotic-derived cellular cytokine solution on the Achilles tendon, the right hind limbs of 104 rats were used.[10] The Achilles tendons of the rats were injected with either 0.9% sodium chloride solution or amniotic-derived cellular cytokine solution in the proximal and distal ends. After the operation, rats were housed for one week for the immobilization of the right hind limb. They were then euthanized and their Achilles tendons were dissected. Mechanical testing was then utilized with the Blue Hill 2 software and a 100-N load cell to compare breaking strength (maximum force), stiffness (force required per unit displacement), tensile strain (change in length over initial length of tendon), ultimate tensile strength (maximum force per unit area), yield strength (maximum stress in the elastic portion), and Young's modulus (resistance to elastic deformation) between the control group and the experimental group. Significant findings after two weeks were found in breaking strength, ultimate tensile strength, yield strength, and Young's modulus. All of these findings were higher in the experimental group than in the control group. Stiffness exhibited no significance between the two groups. Although breaking strength and ultimate tensile strength were significantly higher in the experimental group after week two, by week eight the strength of the control group was significantly higher.[10]

A similar study divided 126 rats into three groups in order to compare the effects of amnion-derived multipotent progenitor (AMP) cells to the effects of amniotic-derived cellular cytokine solution (ACCS).[11] The Achilles tendons of the rats were dissected and injected with either 100 microliters of AMP, ACCS, or saline solution. Rats were

immobilized then euthanized and the Achilles tendons were taken out for mechanical testing. Mechanical testing was then performed with Blue Hill 2 software and a 100-N load cell to compare ultimate tensile strength, Young's modulus, yield strength, breaking strength, and stiffness. The AMP cell treated Achilles tendon displayed a significantly higher Young's modulus ($p < 0.005$) and yield strength ($p < 0.05$) compared to the ACCS and saline groups. Breaking strength, stiffness, and ultimate tensile strength exhibited no significant findings between the three groups. Cross-sectional area of the Achilles tendons was also taken in each group. The cross-sectional areas of AMP treated tendons ($p < 0.01$) and ACCS treated tendons ($p < 0.05$) were significantly higher than the saline treated tendons, indicating the tendons became thicker due to amniotic treatment.[11]

Of the studies regarding mesenchymal stem cell treatment of the Achilles tendon, four studies focused on the direct deposition of mesenchymal cells into the injured Achilles tendon. One study used the transplantation of tendon-derived stem cells (TDSCs) and bone marrow mesenchymal stem cells (BMSCs) to study the treatment of ruptured Achilles tendons in rats.[12] Seventy-two Sprague-Dawley (SD) male rats weighing 200g obtained from the Daping Hospital's animal experimental center were used for these Achilles tendon healing experiments. The rats were divided into three groups of 24: TDSC, BMSC and non-treated groups. The rats were then anesthetized, and a segment from the middle part of the Achilles tendon was cut. Clinical sutures were used to suture the incision and iodine was directly applied. After that, the donor TDSCs (1x 10^6/0.1 mL DMEM) or BMSCs (1 x 10^6/0.1 mL DMEM) was injected around the Achilles tendon of each rat in the TDSC and BMSC group accordingly. Macroscopic, histological and biomechanical evaluations were conducted at three time points in week 1, week 2, and week 4 after incision for a total of three evaluations. Macroscopic assessment at week 4 revealed that the TDSC group displayed a complete Achilles tendon with a normal appearance in the posterior-anterior and lateral views. Meanwhile the BMSC group showed obvious connective tissue group, and the non-treated group showed no tissue growth at all. The histological study of the healing Achilles tendon at week 4 displayed that both TDSCs and BMSCs treated tendons exhibited more ECM deposition and obvious longitudinal fibrous tissue than the non-treated tendons. Treated tendons exhibited greater number of spindle-shaped cells aligned to the longitudinal axis of the tendon. The cells of the non-treated group showed little organization and higher vascularization. The biomechanical strength of the repaired Achilles tendon in the study groups was tested by the ultimate failure load method. It was noted that at week 4, the ultimate failure load of the TDSCs group showed a higher value than that of the BMSCs group and the non-treated group. However there was no statically obvious difference between TDSCs and BMSCs groups. And at week 4 after the incision, the ultimate failure load of TDSCs and BMSCs reached nearly that of a healthy Achilles tendon. Statistical analysis was performed with one-way ANOVA, followed by LSD test for comparison between two groups. A P value of <0.05 was considered significant.[12]

Another study measured the therapeutic potential of mesenchymal stem cells (MSCs) from adipose tissue to treat Achilles tendon injuries in rabbits.[13] Thirty adult male New Zealand rabbits with an average of 2.5kg were divided into six groups. A cross section of the Achilles tendon (CSAT) was conducted for rabbits in Groups 1 and 2, followed by a layered suture, local dressing and preparation of a long leg plaster cast. For Groups 3 and 4 a CSAT was conducted, which was followed by a suture, a layered suture, local dressing, and preparation of a long leg plaster cast. A CSAT was conducted for rabbits in group 5 and 6, followed by the

transplantation of MSCs, a layered suture, local dressing, and preparation of a long leg plaster cast. All groups were euthanized for the collection of biological materials at 14 and 28 days after tendon rupture. The evaluation of inflammatory process decreased from the first to second time point of assessment within the CSAT and CSAT + MSC groups. Likewise, a greater trend towards an increased structural organization was observed for the CSAT + MSC groups, indicating that the MSC transplant had a significantly positive effect on healing. The Mann-Whitney test was used to compare the mean scores in each group between time points. The Kruskal-Wallis test was used for the comparison between groups at the assessed time points. The level of significance adopted was $P < 0.05$.[13]

One study measured the efficacy of a composite surgical mesh for the delivery of mesenchymal stem cells (MSCs) in tendon repair in rats.[14] A total of thirty Sprague-Dawley rats, male with body weight of 250-300g, were used for this experiment. An incision was made, and the tendon was completely severed at the Achilles tendon-gastrocnemius/soleus junction. In regards to the repair methods, the rats were divided into three experimental groups: Group 1) repair using the composite surgical mesh loaded with MSCs Group 2) repair using the composite surgical mesh, without loading of MSCs or Group 3) repair using suture only. The histology of tendon repair was evaluated based on collagen organization, vascularity, and cellularity according to a modified tendon histological scoring system. At day 6, there was more organized and parallel extracellular matrix deposited in Group 1 than in Group 2. Compared to Group 2 and 3, by day 14, the more cells in Group 1 aligned in accordance with the orientation of the tendon. Immunohistochemistry for types I and III collagen was also performed on the sections of repaired tendons that were collected at days 6 and 14 after incision. Type III collagen stain of the finer fibers found in repaired tendons was detected in Group 1 tendons. In other words, the staining ratio of type III collagen over type I collagen, was the highest in Group 1, indicating that there was a significance in healing of the mesenchymal stem cell repair. The histological scores of tendon healing and subcategories at days 6 and 14 were evaluated using two-way ANOVA. $P < 0.005$ was set as statistically significant.[14]

The next study measured the safety and reparative potential of implanted human mesenchymal stromal cells (hMSCs) in collagenase Achilles tendon injuries in rats.[15] Tendon injury was induced by the application of collagenase to the middle part of the Achilles tendon of eighty-one rats weighing 400-440g each. The collagenase produces a chemical deterioration of the tendon tissue. Then the rats were randomly divided into two groups. Group 1 had hMSCs implanted into the center of the tendon 3 days after tendon deterioration. In comparison, group 2 received saline injections in the same regime as the hMSC group. Macroscopic, histological and immunohistochemical evaluations were performed on each tendon before and after the hMSC/saline injection. Six weeks after tendon injury, the wounds were observed to be filled with connective tissue in both groups. The hMSC-treated group achieved a significantly higher histology score than Group 2, which indicates a lower cellularity, denser tissue matrix, better vascularity and better organization of collagen fibers. Motor performances of the rats were also examined using the Basso-Beattie-Bresnahan test. In regards to motor performance, there was no statistically significant difference between the two groups. It should be noted that statistically significant differences for this study were evaluated by nonparametric methods.[15]

DISCUSSION

Currently, the treatment of the Achilles tendon by injecting mesenchymal cells directly into the tendon is more common than the use of amniotic stem cells because amniotic stem cell treatment is a novel treatment.[1] Based on the articles reviewed, amniotic stem cell derivatives could be helpful as treatment for Achilles tendon injuries. Both treatments involve the deposition of amniotic or mesenchymal cells into an injured tendon. Statistical significance was found in both types of treatment in different tests regarding the strength of the tendons before and after the procedure. More research needs to be done in order to statistically compare the two different types of treatment. Both treatments should be considered in the case of an injured patient as they would allow for the rebuilding of the injured Achilles tendon, currently compensated for with orthotics or pain medication.

The studies regarding amniotic allograft and cytokine solution exhibited a statistically significant increase in yield strength. Some factors such as breaking strength and stiffness were not statistically significant. The mesenchymal treatment studies displayed an increase in biomechanical strength in the experimental group compared to the control group. In order to decisively compare the two treatment groups, the measure factors should be the same, along with the procedure itself. A true comparison can be made when the groups involved are a control group, an amniotic allograft treatment group, and a mesenchymal cell treatment group. The measurements of yield strength, breaking strength, and stiffness must be measured on the same grounds with the same software. This comparison will ultimately aid in choosing the best treatment for patients with Achilles tendon injuries.

CONCLUSION

The reviewed literature found both mesenchymal stem cell treatment and amniotic stem cell treatment could be useful in the therapy of Achilles tendinopathies, however more research must be done in order to make a statistical comparison between the two types of therapy. Both treatments showed promising use of stem cells overall for the various type of tendinopathies, including tears and inflammation. Healing time, strength and the alleviation of pain were all improved significantly, with little to no side effects.

Only a few studies have been done about treatment using amniotic stem cells. In the future more studies should be done to study the mechanism of action and side effects of using amniotic stem cell therapy in both Achilles tendinitis and ruptures. Though much more research has been done to observe the healing effects of mesenchymal stem cells as compared to amniotic stem cells, additional research needs to be done on the ideal way to deliver the therapy to the site of pathology. Some research has been done on genetic activation of various stem cells to help accelerate the healing action of the treatment.

Achilles tendon injuries are very common in podiatric patients and are often dealt with by using orthotics, physical therapy, and pain medication. Amniotic and mesenchymal stem cell therapies are medical advances that could allow for a full recovery of the Achilles tendon. In the future, tendinitis ruptures, and other types of Achilles tendon injuries could be solved by injecting stem cells into the tendon, allowing patients to live an easier and more active lifestyle.

AUTHORS' CONTRIBUTIONS

SVP conceived the research design and SRZ performed the database search. SVP and SRZ contributed equally to the literature review and editing of the manuscript.

STATEMENT OF COMPETING INTERESTS

The authors declare that there are no competing interests associated with this manuscript.

REFERENCES

1. Saini SS, Reb CW, Chapter M, Daniel JN. Achilles Tendon Disorders. *J Am Osteopath Assoc* 2015;115(11):670-676. doi: 10.7556/jaoa.2015.138.
2. Andres BM, Murrell GAC. Treatment of Tendinopathy: What Works, What Does Not, and What is on the Horizon. *Clinical Orthopaedics and Related Research*. 2008;466(7):1539-1554. doi:10.1007/s11999-008-0260-1.
3. Smith, RKW. Mesenchymal stem cell therapy for equine tendinopathy. *Disability and Rehabilitation.*:1752–1758.
4. Hani A. Awad, David L. Butler, Gregory P. Boivin, Frost N.L. Smith, Prasanna Malaviya, Barbara Huibregtse, and Arnold I. Caplan. *Tissue Engineering*. June 1999, 5(3): 267-277. doi:10.1089/ten.1999.5.267.
5. Wan C, He Q, McCaigue M, Marsh D, Li G. Nonadherent cell population of human marrow culture is a complementary source of mesenchymal stem cells (MSCs). *Journal of Orthopaedic Research*. 2006; 24 (1): 21–8.
6. Fauza D. Amniotic fluid and placental stem cells. *Best Pract Res Clin Obstet Gynaecol* 2004;18:877–891
7. Muttini A, Salini V, Valbonetti L, Abate M. Stem cell therapy of tendinopathies: suggestions from veterinary medicine. *Muscles, Ligaments and Tendons Journal*. 2012;2(3):187-192.
8. Mattioli M, Gloria A, Turriani M, et al. Stemness characteristics and osteogenic potential of sheep amniotic epithelial cells. *Cell Biol Int*. 2012;36(1):7–19
9. Werber B. Amniotic Tissues for the Treatment of Chronic Plantar Fasciosis and Achilles Tendinosis. *Journal of Sports Medicine*. 2015;2015:219896. doi: 10.1155/2015/219896.
10. Kueckelhaus M, Philip J, Kamel RA, et al. Sustained Release of Amnion-Derived Cellular Cytokine Solution Facilitates Achilles Tendon Healing in Rats. *Eplasty*. 2014;14:e29.
11. Philip J, Hackl F, Canseco JA, et al. Amnion-Derived Multipotent Progenitor Cells Improve Achilles Tendon Repair in Rats. *Eplasty*. 2013;13:e31.
12. Al-ani Mohanad Kh, Xu K, Sun Y, Pan L, Xu Z, Yang L. Study of Bone Marrow Mesenchymal and Tendon-Derived Stem Cells Transplantation on the Regenerating Effect of Achilles Tendon Ruptures in Rats. *Stem Cells International*. 2015;2015:984146. doi:10.1155/2015/984146.
13. Vieira M, Oliveira R, Eça L, et al. Therapeutic potential of mesenchymal stem cells to treat Achilles tendon injuries. *Genetics and Molecular Research Genet. Mol. Res*. 2014;13(4):10434–10449. doi:DOI: 10.4238.
14. Schon LC, Gill N, Thorpe M, et al. Efficacy of a mesenchymal stem cell loaded surgical mesh for tendon repair in rats. *Journal of Translational Medicine*. 2014;12:110. doi:10.1186/1479-5876-12-110.
15. Machova Urdzikova L, Sedlacek R, Suchy T, et al. Human multipotent mesenchymal stem cells improve healing after collagenase tendon injury in the rat. *BioMedical Engineering OnLine*. 2014;13:42. doi:10.1186/1475-925X-13-42.

A Comparative Review of Minimally Invasive Surgical Treatment Options for Intra-articular Calcaneal Fractures

Danielle Dubois, BS, Mark Rotenstein, BS and Nicholas Salerno, BS

ABSTRACT

Introduction
Calcaneal fractures are among the most common tarsal fractures. They often occur as a result of high impact trauma, such as a fall from a ladder or a motor vehicle accident. Intra-articular fractures comprise about 75% of all calcaneal fractures in the adult population. In the past, open reduction and internal fixation had been the surgical treatment of choice for most, if not all intra-articular calcaneal fractures. However, new minimally invasive techniques are being utilized more frequently and their outcomes are just beginning to be evaluated. The aim of this paper will be to evaluate and compare the various surgical treatment options of intra-articular calcaneal fractures, with a focus on minimally invasive techniques.

Study design: Qualitative Systematic Review of the Literature

Methods
A literature search was conducted via Pubmed and Google Scholar with search terms 'Calcaneal Fracture,' 'Calcaneus fracture' and 'intra-articular calcaneal fracture'. The Pubmed database search returned 159 results. Of those 159 results, 24 articles were selected for further review. The articles were selected for further review based on relevancy to the topic of intra-articular calcaneal fractures, the surgical techniques to reduce them, and the outcomes of the surgeries. Exclusion criteria included articles on extra-articular calcaneal fractures, case studies, case series, and articles without a focus on surgical techniques and outcomes. Google Scholar database returned about 14,000 results. Out of those, 42 articles were chosen for further review based on the relevant inclusion and exclusion criteria.

Results
The authors reviewed various techniques for reduction of intra-articular calcaneal fractures, comparing traditional approaches such as extensive lateral and the use of plates and screws, with newer techniques such as balloon-assisted augmentation with calcium phosphate cement, percutaneous fixation with k-wires, arthroscopic approaches, the Brixian bridge approach, and the endobutton technique. The methods were evaluated based on the post-op wound and infection rates, healing times, surgical outcomes, and patient satisfaction. The authors found that while traditional extensile lateral approaches using plates and screws have good results and patient satisfaction rates (average AOFAS score 85, wound complication rate 9%), newer minimally invasive techniques have similar results with a shorter recovery time and lower infection rates (average AOFAS score 90, wound complication rate 3%).

Conclusion
The objective of this paper was to explore the various surgical treatments for intra-articular calcaneal fractures and their outcomes. The authors found that newer, minimally invasive techniques have comparable and relatively favorable outcomes compared to more traditional ORIF methods, with less post-op infection rates, and higher rates of patient satisfaction. While some studies have shown favorable data for newer techniques, no significant conclusion can be reached as to which technique is the gold standard. Minimally invasive techniques show much promise, and as the approach evolves, these newer techniques may be considered as a viable surgical option in the future for the treatment of intra-articular calcaneal fractures.

Key Words: Intra-articular calcaneal fracture, calcaneal fracture, surgical reduction of intra-articular calcaneal fracture

Level of evidence: 4

INTRODUCTION

The surgical treatment of calcaneal fractures has been evolving for over a century, and is an area of great interest to podiatrists and orthopedic surgeons. According to Potter, et al Calcaneal fractures constitute up to 2% of all osseous fractures, and the majority of all tarsal bone fractures.[1] We pay particularly close attention to intra-articular calcaneal fractures (involving the subtalar joint), which make up 75% of all calcaneal fractures in the adult population. These types of fractures often occur as a result of high impact trauma, such as falling from a ladder, and may lead to long term sequelae and debilitating pain in patients. These abrupt changes in shearing forces and compression cause various types of fractures, which are subcategorized into various classification systems. With complicated injuries, prompt surgical intervention is often warranted to salvage neurovascular structures and articular congruity, to promote functional movement and limit residual problems.

The Sanders classification system, which is based on coronal CT scans, is the most commonly used fracture classification system used to identify intra articular calcaneal fractures. Calcaneal fractures are broken down into five different types based on the number of intra articular fracture lines found on CT imaging, which are then subcategorized with the letters A, B, and C based on their fracture line location in the posterior facet. Letter A represents a fracture through the lateral aspect of the posterior facet, B is through the center, and C is through the medial aspect of the facet. Sanders type I includes all intra articular fractures that have less than 2mm of displacement, regardless of the number of fracture lines and location. Type II involves one primary fracture line through the posterior facet, type III involves two fracture lines, and type IV involves three or more fracture lines with more than 2mm of displacement found. This classification system allows for differentiation of intra-articular calcaneal fractures and is a key factor in choosing the appropriate surgical treatment option as well as predicting patient outcomes. Outcomes are predicted to be progressively worse with each increase in classification number.[2] Two important radiography angles, *Bohler's Angle* (angle of the highest points of the posterior tuberosity, posterior, and anterior articular facets respectively) and *Critical Angle of Gissane* (angle of the superior calcaneal articular surface) are utilized in assessing the severity of displaced intra-articular calcaneal fractures and the success of their surgical outcomes.[3,4] A fall from high surfaces or other forms of axial loading are the most common cause of calcaneal fractures. In these injuries the lateral process of the talus is forced downward and breaks through the posterior articular facet, thus reducing the Bohler's angle.[5] There is a significant correlation between preoperative Bohler's angle and the injury severity of the intra calcaneal fractures, however the postoperative Bohler's angle we found to have the most correlation with the functional recovery of the patient.[6] Restoring Bohler's angle back to a normal range of 25-40 degrees is one of the main surgical goals in reducing a calcaneal fracture.[7] The critical angle of Gissane is also used to help determine the presence of a calcaneal fracture, which is likely if the angle is over 145 degrees. While not every patient is an ideal surgical candidate for treatment of intra-articular calcaneal fractures, studies have shown that outcomes are more beneficial with surgery than closed reduction and non-operative means.[8] Traditional methods, namely open reduction and internal fixation (ORIF) using a lateral approach, have been associated with favorable outcomes.[8] More recently implemented, minimally invasive surgical techniques have been utilized in intra-articular calcaneal fractures to much success. These various techniques involve miniscule incisions, balloon kyphoplasty with injection of various cements, bone graft applications, and the use of percutaneous k-

wires. The aim of this paper will be to evaluate the various surgical treatment options of intra-articular calcaneal fractures, with a focus on post-op wound and infection rates, healing times, surgical outcomes, and patient satisfaction.

METHODS

A literature search was conducted via Pubmed and Google Scholar databases with. Search terms included "Calcaneal Fracture," "Calcaneus fracture" and "intra-articular calcaneal fracture". The inclusion criteria for both searches included articles that discussed surgical treatment options for intra-articular calcaneal fractures. Exclusion criteria included articles in which the main topic was not intra-articular calcaneal fractures, articles not written in the English language, articles not available in full text, case studies and case-series. The search employed the Boolean operators "or" and "and" for the terms "Intra-articular Calcaneal Fractures" AND "Surgical Treatment" OR "Conservative Treatment" OR "Minimally Invasive Surgery". The Pubmed database search returned 159 results. Of those 159 results, 24 articles were selected for further review based on the relevancy of the abstract summary, and inclusion/exclusion criteria. Google Scholar database returned about 14,100 results, which was narrowed down to 251 results with the inclusion of key words 'surgical treatment' and 'intra-articular calcaneal fracture surgery'. Out of those, 38 articles were chosen for further review based on the relevant inclusion and exclusion criteria and abstract summary. In total, 42 articles were chosen for further review.

RESULTS

Surgical Intervention

Traditionally, intra-articular fractures were either treated by closed non-operative conservative methods, or by open reduction and internal fixation using a lateral approach. Himanshu performed a prospective, comparative study where patients with displaced intra-articular fractures were separated into two treatment groups (operative and conservative). The functional outcomes were scored using the Crighton-Nebraska scoring, which is a functional scale based out of 100 possible points used to evaluate post calcaneal fracture patients. This score system is determined by pain both at rest and during activity, activity levels, range of motion available, and the average time for a patient to return to work. Outcomes were also based off of heel varus angle and Bohler's angle at the end of the 12 months. Open reduction with internal fixation using calcaneal plates proved to have better functional outcomes than conservative, non-surgical reduction.[9] While the one study does not definitively support ORIF over closed reduction in all instances, this supports the idea that most intra-articular fractures benefit from some sort of surgical intervention, as long as the patient is a candidate for surgery.

ORIF with compression plates

The first surgical attempt to reduce a displaced fractured calcaneus via open reduction took place in 1882, and the first open reduction and internal fixation utilizing a lateral approach was performed by Morestin in 1903.[10,11,12] Plate osteosynthesis with the utilization of a lateral approach is currently the gold standard for the surgical management of calcaneal fractures.[13] In a retrospective study by Rak et al., the use of locking compression plates has improved ORIF by increasing functional results, limiting bone graft indications, and shortening the recovery period, with 72% of patients achieving good or excellent results.[14] In a study by Kienast et al., 66 patients out of 136 were completely pain free following an extended lateral approach with internal fixation locking plates.[15]

The purpose of fixed angle locking plates is to reduce the fracture and establish a uniform

stiffness during range of motion. However, despite the use of locking compression plates, inadequate stiffness and destabilization can still cause osteosynthesis failure. A study by Rausch et al. showed that cement augmented screw specimens displayed a significant advantage over locking plates with respect to stiffness and range of motion and have comparable results during load failure.[13] In addition to fracture movement, other complications include complications in wound healing, post-traumatic arthritis of the local joints, and osteitis of the calcaneus. Further surgical procedures, such as a calcanectomy or lower limb amputation, are required to address these complications.[16] Following an open reduction internal fixation with metallic implants, post-op pain and tenderness is often noted at the surgical site. Hardware removal may be required in situations where chronic pain is present. In a study by Brown, 31% of patients who had undergone ORIF had pain over the lateral fracture hardware, and 23% had their hardware removed or desired removal.[14] In light of these complications, recent reports of treating fractures with bioabsorbable screws have shown favorable results.[15] In a study by Zhang et al., 55 out of 58 patients demonstrated signs of bone union at about three to four months postoperatively without any complications.[21] These results had an AOFAS score of 87, which was better than the Potter et al. AOFAS score of 65.4, which managed patients with plates.[1]

Arthroscopic Approach

Due to the risk of inaccurate posterior facet restoration when using a closed reduction technique, subtalar arthroscopy utilizing a percutaneous stab incision has been implemented. Arthroscopy is often used as a modality to properly visualize the articular surfaces being reduced, and can be used intra operatively to achieve 2D or 3D fluoroscopic imaging to assess the quality of joint reduction. This method has been used in both open and closed reduction procedures A study by Rammelt et al. investigated the use of percutaneously inserting a 6.5mm Schanz screw centrally into the main portion of the fragmentation parallel to the superior border of the calcaneal body.[19] Utilizing a standard anterolateral or posterolateral portal based on the anatomy of the fracture, the quality of the posterior facet reduction was visualized through a small 2.7 mm, 30 degree ankle arthroscope. The fragment was mobilized into the correct position via leverage from a T-handle under fluoroscopy guidance. Out of 24 patients who had undergone this procedure, none developed wound edge necrosis, hematomas or infections. No postoperative complications were seen, most notably any complications attributed to subtalar arthroscopy. The AOFAS mean score of the 24 patients was recorded as 92 at the final follow-up. All patients exhibited stable plantigrade feet, no step offs were seen in the subtalar joint, and no patients required a secondary subtalar fusion. Radiographic parameters were close to normal at follow up when compared to the uninjured side during weightbearing radiographs. Bohler's angle improved from an average of 12 degrees preoperatively to 25 degrees on the injured side, with no noticeable varus or valgus malalignments observed.

In another study, the outcomes of the 24 patients who had undergone reduction via arthroscopy were compared to 18 previous patients at the same institution that were treated with open reduction and internal fixation via an extended lateral approach.[14] No major differences in the functional outcomes were observed with the average AOFAS score was 92 for the arthroscopic percutaneous approach versus 88 in the open reduction approach. The results were comparable anatomically as well, as the average Bohler's angle was 25 degrees following the percutaneous method and 26 degrees via open reduction with plate fixation, and hindfoot motion in the coronal

plane was recorded at 42 degrees in percutaneous reduction and 34 in open reduction. A significant difference was, however, noted in the time it took patients to return to work, as the patients who had undergone the percutaneous reduction took an average of 11 weeks to return to work while those who had undergone open reduction took 16 weeks.

Percutaneous reduction using K wires

Reduction of calcaneal fractures using percutaneous Steinmann pins was first introduced by Westhues and implemented by Essex Lopresti.[11] The pin or spike is placed laterally and parallel to the impacted fracture and the fracture is reduced by lifting upward on the pin until proper positioning is achieved.[22]Modifications of this procedure are currently in use in repositioning displaced intra articular fractures. K-wires or Steinmann pins are positioned posterior-superiorly to assist in fracture reduction, followed by various reduction techniques such as lateral to medial screws, or stabilization through plating. The advantage of this technique is that there are no large incisions, due to the fact that the pins are inserted percutaneously, and the distraction and reduction of the fracture occurs through an arthroscopic approach. Out of 210 fracture repairs reported by Wang et al., the technique involved using a small oblique 2cm incision 2 cm distal to the tip of the fibular, with the use of an intraoperative fluoroscopy to ensure proper anatomical positioning. Four of these patients developed medial plantar nerve injuries, two patients developed tibial nerve injuries, and six patients developed sural nerve injuries. Furthermore, all patients improved following anatomical plate and compression bolt removal and/or neurolysis. [22] A study by Schepers et al, used a percutaneous later approach using an external distractor putting force on 3mm Kirschner wires, which were inserted on both sides of the foot between the calcaneus tuberosity and talar neck, and the cuboid and talus. A 10% risk of injury to the lateral dorsal cutaneous nerve was reported in this study with most cases improving spontaneously. [23] Rammelt et al. investigated the use of percutaneous reduction used the sanders classification system to exclude extra articular and non displaced intra articular fractures (Sanders type I). The study performed percutaneous reduction using a stab incision centrally into the main portion of the fragment parallel to the superior border of the calcaneal body and 6.5mm Schanz screw fixation in 61 patients with type IIA and IIB calcaneal fractures. The average AOFAS score of 92/100 points in patients with Sanders Type II fractures with moderate displacement.[19]

Brixian Bridge Method

The Brixian Bridge method of calcaneal fracture reduction and fixation, named for it's origins in Brescia, Italy, is a technique based off a modification of the Essex- Lopresti method, and uses percutaneously inserted K-wires or Steinmann pins and plaster casting. Fluoroscopy is used to help guide the first K-wire into the subchondral bone of the posterior facet, carefully avoiding entry into the subtalar joint, and is then maneuvered to both lower the calcaneus itself, and raise the depressed posterior facet. Upon adequate correction of the Bohler's angle, a second K-wire is inserted percutaneously into the posterior and inferior aspect of the calcaneus across the talocalcaneal joint until it purchases the talus. A third K-wire is inserted parallel to the second wire for stability. A final K-wire is inserted in a horizontal orientation parallel to the weight bearing surface into the calcaneus or into the cuboid for proper stabilization. A 35 day period of above knee casting, followed by a 35 day period of below knee casting is required to allow for proper osteogenic growth until gradual weight bearing can be allowed.[25]

Endobutton Assisted technique

In a study performed by Kesemenli et al, 18 calcaneal fractures were observed following a closed indirect reduction with Endobutton assisted minimally invasive osteosynthesis. This technique involved a 2.7mm pin drilled laterally to medially through the calcaneus, which is then enlarged with a 5.0mm endobutton drill over the passing pin. The endobutton arrangement is passed perpendicularly laterally to medially through the 5mm tunnel in long axis of the calcaneus via traction strings. Once the endobutton has passed through, the foot is placed into equinus and a closed reduction is performed by applying applying tension on the No. 5 FiberWire sutures. These sutures are passed through the outer holes of the endobutton and then tied.[26] A varus position of the calcaneus can be restored by the use of Kirschner wires or Steinmann pins. The mean preoperative Bohler angle in a study performed by Kesemenli et al was 17.1 degrees, which was corrected to a mean of 20.4 postoperatively, while the average Gissane angle was 116 degrees which was corrected to 117.8 postoperatively. The 6 month postoperative AOFAS was 59.8, however the last follow up demonstrated an increase in the average score to 79.1. No postoperative complications, infections, or wounds were observed. All of the patients returned to work in under a year, and no gait disorders were noted.

Balloon Kyphoplasty and Bone Cements

Balloon kyphoplasty with the injection of bone cement is a procedure most commonly used in recent years to treat vertebral fractures. To reduce the vertebral fracture, the balloon is used to lift the vertebral endplate enough to inject bone cement.[8] The same technique and tools are used when applying this method to calcaneal fractures as they are often joint depression fractures and require careful re-alignment of Bohler's angle and the subtalar joint under fluoroscopy. A preliminary study performed by Labbe et al. investigated the use of balloon kyphoplasty for the treatment of intra-articular displaced calcaneal fractures.[27] Reduction of the fracture is achieved using balloon expansion and injection of resorbable tricalcium phosphate or polymethyl-metacrylate cement without internal fixation. Although the surgery was only performed on six patients, the functional outcomes were beneficial, and no postoperative infections were reported. Jacquot et al. explored the use of balloon kyphoplasty on ten patients with calcaneal fractures.[28] Patients were operated upon in the prone position and reduction was obtained in all cases. Patients were followed up regularly and were examined after a minimal follow up for 36 months. The AOFAS clinical results were rated good or excellent in 81.8% of cases and the physical component of the RAND-36 was 74.6. One patient had a bad clinical result with evidence of subtalar arthritis on the CT scan. All patients had returned to the former professional activities at the same level as before the fracture, except one who had retired but had resumed leisure walking.

A study by Biggi et al. incorporated a calcaneoplasty technique using the balloon reduction and injection of calcium phosphate.[29] All 11 patients (all Sanders type II and III fractures) that received this treatment had bony union in 2-3 months, and 10 out of 11 had good or excellent AFOAS scores. No postoperative infections were reported. Lian et al. assessed the clinical and radiological performance of mineralized collagen as a bone graft substitute in intra articular calcaneal fractures with trabecular defects.[30] 24 pairs of calcaneal fractures were treated with either mineralized collagen or autograft. Patients were monitored at 6 weeks, 12 weeks, 6 months and at 1 year postoperatively. All fractures were healed and there was no significant mean union time difference between the two groups. A total of 29% of patients suffered from harvest site morbidity at 12 months in the autograft group.

In a study by Jacquot et al., percutaneous reduction was achieved by inserting an 11-gauge bone needle into the posterior aspect of the calcaneus, with K wires driven through the needle into the plantar cortex of the fracture. Using these wires as a platform the balloon was inserted to obtain reduce at the fracture site, followed by 4-6mL of poly-methacrylate cement. Patients had little to no post-op pain, with three patients showing signs of subtalar arthritis on CT scan.[28]

In a study by Thordarson et al. the use of osteoconductive calcium phosphate cement in 36 depression type calcaneal fractures was used. The use of calcium phosphate cement (CPC) improves the fracture constructs which will allow for earlier return to weight bearing and an increase in compressive fatigue strength, which proved to be equivalent to cancellous bone.[31] Furthermore, no statistical differences were observed in the clinical outcome in a patient who returned to full weight bearing before or after six weeks postoperatively.

Complications

Extensile lateral approach is the most commonly used approach for operative treatment of intra-articular calcaneal fractures. However, its main drawback is the high wound complication rate.[32,33] Injury of the lateral calcaneal artery at the site of the vertical incision has been noted to be responsible for ischemia and necrosis of the lateral calcaneal flap.[32,33] In a retrospective study by Bakes et al., 47 out of 191 of patients (24.6%) whose calcaneal fractures were treated with an extended lateral ORIF technique, developed a postoperative wound infection, with 11% and 13.6% developing a superficial and deep infection, respectively.[33] Historically, the extensile lateral approach has been considered the gold standard approach for the treatment of displaced intra-articular calcaneal fractures. It provides excellent exposure of the fracture site and allows for anatomical reduction and restoration of the architecture of the calcaneus. However, soft tissue complications involving wound dehiscence and infection have been estimated to occur in as many as one in four patients.[21,33]

A study by Ene et al. compared minimally invasive techniques with the more traditional ORIF approach.[34] Out of 66 patients who were candidates for surgical reduction of intra-articular calcaneal fractures, 29 patients underwent ORIF with plates and screws, while 37 were selected for the minimally invasive procedure (Essex Lopresti with osteosynthesis). Of the ORIF patients, four developed post-op wound infections and two developed skin necrosis, while no post op infections were reported in the minimally invasive group. 20 out of 29 patients who underwent the lateral ORIF procedure, and 30 out of the 37 minimally invasive patients had excellent results. In a systematic review by Schepers, a total of eight case series reporting on 256 patients with 271 calcaneal fractures was identified.[23] An average minor wound complication rate was reported to be 4.1%, and a major wound complication rate was reported to be 0.7%, while the average requirement for a secondary subtalar arthrodesis was rated 4.3%.

Another important thing to consider when performing calcaneal surgery is the possibility of nerve injury and postoperative paresthesia that patients may experience. With the extended lateral approach, although the sural nerve is not directly exposed and is carefully dissected, there is still a high incidence of paresthesias and nerve complications following surgery.[35,36] Wang et al. reported that a significant number of patients with calcaneal fractures develop postoperative paraesthesia and pain along the incisions by the sural nerve.[22] In a 1992 study by Buckley et al., a 29% incidence of postoperative sural nerve lesions were reported after undergoing surgery by the direct lateral approach, and a similar study by Eastwood and Atkins reported that 11 out of 20 cases had sural

nerve dysfunction following surgery, 4 of which were permanent.[35,36] Weber et al., reported that the rate of injuries to the sural nerve was 7.7% in their patients treated via the extensile lateral approach.[37] It is due to these neuronal complications that there has been a search for alternative incision techniques.

An alternative sinus tarsi approach, where the incision line runs from the tip of the lateral malleolus to the calcaneocuboid joint in line with the 4th metatarsal, has been used to minimize injuries to the nerve with a moderate degree of success. Abdelgaid et al., reported one patient out of 24 had a plantar nerve injury, but none developed sural nerve sequelae, and that overall there were less reported nerve injuries with the sinus tarsi approach than with the direct and extensive lateral incisions.[32] In a retrospective cohort study by Je-Hyoung Yeo et al, 4 of 60 patients in the extensile lateral approach complained of sural nerve symptoms, while 2 of 40 patients in the sinus tarsi approach complained of sural nerve symptoms.[38] Weber et al. reported zero nerve injuries in the sinus tarsi approach, compared to the 7.7% in their patients treated with the extended lateral approach.[37] Hospodar et al. found a 75 versus 13 good to excellent result when comparing the sinus tarsi approach and the extended lateral approach using the MFS.[39] Using the AOFAS score, Weber et al. reported on a good to excellent outcome in 84 versus 66 also in favor of the sinus tarsi approach.[37]

DISCUSSION

Surgical Intervention

When treating calcaneal fractures, the most important things to consider are restoration of the articular function and hindfoot morphology of the foot. Non-operative closed reduction techniques are generally associated with changes in joint morphology, leading to sequelae such as arthritis. A study that compared non-operative methods with open reduction and internal fixation with plates reported an average increase in Bohler's angle of 12.66 degrees, with a higher increase in Bohler's angle correlating with a better functional outcome.[9] In addition, a mean increase in heel height of 8mm was reported after the extensive lateral approach.[41] A study by Wang et al concluded that calcium sulfate cement augmented screws provided faster weight bearing time, diminished joint stiffness and increased patient satisfaction.[22] Optimal osteosynthesis is also based on technical practicality, and while fixed angle locking plates offer a significant advantage over conventional plates. In the study by Rausch et al., screw osteosynthesis was theorized to be associated with a biomechanical advantage compared to plating due to the positioning of the screws and augmentation in the area of maximum stress.[13]

Minimally invasive techniques

Even though surgical intervention has been associated with better outcomes than closed reduction in most cases of intra-articular fractures, not every patient is a candidate for traditional open reduction and internal fixation due to the presence of comorbidities like diabetes and peripheral arterial disease. However, newer, minimally invasive techniques have been developed which gives these patients an opportunity for surgical correction of the injury. These revolutionary methods have been shown to be just as effective as the traditional approach in terms of reduction of the fracture and fixation stability, with less incidence of infection and long-term nerve damage.[34] These methods include using arthroscopic approaches, percutaneous k-wire insertion, the Brixian bridge, the Endoscopic button method, and balloon kyphoplasty with injection of various bone cements, all of which provide a way to reduce the fracture, restore proper angles, and maintain the bones in proper alignment following surgery.

Arthroscopic Approaches

Due to the growing interest in minimally invasive surgeries, subtalar arthroscopy is becoming increasingly utilized by foot and ankle surgeons. A study investigating post-operative results after calcaneal fracture reduction found no post-operative complications relating to arthroscopy.[38] Patients who have undergone arthroscopic surgery for calcaneal fractures have shown to have alignment, joint range of motion, and functionality comparable to patients who have undergone traditional ORIF techniques, but return, on average, 5 weeks earlier to work.[42] Although the utilization of arthroscopy requires a significant amount of training and skill on the part of the surgeon, it is increasingly becoming utilized in all areas of surgery, and will continue to prove beneficial for the foot and ankle.

Percutaneous K-wire insertion

K-wire or Steinmann pins are inserted percutaneously as a method to stabilize calcaneal fractures, and can be followed by various reduction techniques such as lateral to medial screws, or stabilization through plating, accomplished arthroscopically. The advantage of this technique is that there are no large incisions, due to the fact that the pins are inserted percutaneously and the distraction and reduction of the fracture occurs through an arthroscopic approach. With a more minimally invasive surgical approach, a study by Arastu et al. reported that the average change in Bohler's angle was 18.7 degrees, and the change in length of the calcaneus was 4.7 mm. Furthermore, there was an extremely low rate of superficial infection, no deep infections, and no nerve damage.[3] This study was performed in patients with several co-morbidities that excluded them from having traditional ORIF surgery, which demonstrates that these types of minimally invasive techniques are suitable for many patients and may even have superior outcomes compared to the traditional approach. Another study by Rammelt, et al performed percutaneous K-wire insertion followed by screw fixation in patients with Sanders Type II fractures with moderate displacement, with the resulting average AOFAS score of 92/100 points.[19] This score correlates to an excellent functional outcome, and furthermore, the patients reported taking less time off work than the patients who had undergone the traditional method.

Brixian Bridge Method

The Brixian Bridge technique, based off of the original Essex-Lopresti method, is a percutaneous intra articular calcaneal reduction approach that utilizes K-wires. This method decreases the risk of soft tissue infection, injury to local neurovascular structures and tendons due to the fact that no open dissection is performed. An article by Massimo Pezzoni et al. advises that this approach should theoretically be the preferred technique in patients who are at increased risk for soft tissue infection and delayed healing times, such as diabetics, patients with peripheral vascular disease, those who are immunocompromised and those who smoke.[25] Furthermore, it is a relatively inexpensive, fast and easy procedure to perform in comparison to ORIF. However, this technique is not advised for calcaneal fractures with severe depression and rotation, which will often require an ORIF with graft. More research needs to be conducted to compare this method with the Essex Lopresti method.

Endobutton Assisted technique

While it warrants further research, the Endobutton minimally invasive technique has been shown to have favorable outcomes in several patient populations. Compared to other open reduction techniques, closed reduction with the Endobutton procedure has a lower learning curve, with a markedly

lessened morbidity. Additional advantages include a relatively early recovery and decreased period of rehabilitation. Furthermore, it can be used in acute edematous soft tissue cases, which can decrease the wait time required for various other surgical techniques.[26] However, in cases of severe traumatic injury, more invasive procedures may be better suited for those patients. Very few studies have been done regarding this technique, and it warrants further investigation.

Balloon kyphoplasty and bone cements

Further expanding on the minimally invasive approach of percutaneous K wires is balloon kyphoplasty and injection of bone cement. Since this is a novel technique, there is minimal literature on the outcomes of this procedure but what has been published is promising. Biggi et al. reported good to excellent results in 10/11 cases, with no incidence of infections or complications.[29] Labbe et al. reported a median score of 87 on the AOFAS scale for the patients undergoing this procedure, which corresponds to an overall good outcome.[27] This is significantly higher than previously reported AOFAS outcome scores for the lateral and extended lateral approach, which have been reported at an average of 77 out of 100.[40] Other case reports also report good to excellent outcomes with minimal complications.[41]

The use of calcium phosphate cement improves the fracture constructs which will allow for earlier return to weight bearing, which was seen in a study by Thordarson et al. A study by Thordarson et al. showed an increase in compressive fatigue strength in an in vitro calcaneal fracture repair when the defect was filled with SRS bone cement, while also showing a compressive strength equivalent to intact cancellous bone.[31] There was also no loss of surgical correction after a 24 months post-op in a study by Bano et al.[41] It has been noted that the bone cement assists in neutralizing any micromotion at the location of the fracture site, allowing for stable osteosynthesis and decreased pain. Bano's study showed an association with a faster rehabilitation, shorter disability and minimal complications. Although these various studies were performed on a limited patient population, they demonstrate good functional outcomes and low infection rates when using the balloon kyphoplasty method. Percutaneous balloon kyphoplasty with injection of bone cement is supported by literature, but more evidence based studies are needed to see how the cement holds up after years of wear and to observe possible subtalar arthritic changes in patients.

Complications

Post-operative wound infections are important to consider for any patient undergoing surgery, but especially important for patients with co-morbidities such as diabetes and smoking, which have been shown to slow healing rates. Backes et al. reported a post-operative wound infection rate of 24.6% when undergoing the traditional ORIF procedure for intra-articular calcaneal fractures in a retrospective 10 year study on 191 patients.[33] The rate of 24.6% is considered high, but is similar to other reports on the ORIF procedure.[33,35] To avoid consequences and reduce wound infection rates, multiple percutaneous and minimally invasive approaches have been developed.[42] These less invasive techniques have reported a much lower complication and infection rate, ranging anywhere from 0-5%.[2,33] A study by Ene, et al determined that the minimally invasive approach was more favorable due to their results with healing time, infection rates and long term outcomes.[34] Since minimally invasive techniques are relatively new, there is little evidence from large cohorts of patients. However, most studies report a low post-operative infection rate, with some reporting no post infections following minimally invasive surgery.

One of the biggest pitfalls of the extended lateral approach to reducing calcaneal fractures is the large L-shaped submalleolar incision, which can expose and subsequently damage the sural nerve. Even though careful anatomic dissection is performed, many patients still report post-operative nerve pain or parasthesias. These post-operative nerve sequelae have even been reported to be as high as 29%.[36] Newer percutaneous approaches bypass this problem by limiting exposure to neurovascular structures. Whether they simply use K-wires as fixation without a direct incision, or utilize a sinus tarsi approach, the risk of damaging a nerve is much lower. Preliminary studies investigating this issue have shown to have very low rates of nerve-related complications, with most around 0-1%.[21] Anatomically, the difference is due to the extended lateral approach incisions laying at both the proximal and distal ends of the sural nerve. Although there have only been a limited number of studies on nerve injury with the minimally invasive percutaneous approach, the results thus far are promising. These minimally invasive techniques to reduce intra-articular calcaneal fractures are a valuable alternative to the traditional ORIF approach, especially when considering damage or post-operative sequelae involving nerves of the lower extremity.

CONCLUSION

Calcaneal fractures account for a significant percentage of all traumatic osseous injuries to the human foot, and in many instances lead to lifelong debilitation. With appropriate pre-op evaluation, surgical intervention of intra-articular calcaneal fractures has been linked to favorable outcomes. Though traditional ORIF methods have led to generally favorable results, more effective ways of performing reduction and fixation of calcaneal fractures have been tested and evaluated as technology and surgical techniques continue to improve. One of the most important differences between traditional and newer surgical techniques is the size of the incision and the level of anatomic dissection that must be performed. Although a large incision offers the benefit of full visualization, drawbacks include a high rate of infection, wound healing complications, and possible nerve damage. By utilizing a small incision over one of the main compartments of the ankle, surgeons are able to achieve a level reduction and fixation of the fracture comparable to the traditional ORIF method.

Novel approaches such as balloon kyphoplasty with injection of various bone cements, percutaneous k-wire reduction and fixation, the Brixian Bridge, and the Endoscopic button technique have been utilized with minimal risk to the patient and favorable outcomes. Minimally invasive techniques offer value especially when considering patients who cannot undergo traditional open-type surgery due to various comorbidities. Since it has been proven that surgically reducing an intra-articular calcaneal fracture produces better outcomes than a closed reduction, minimally invasive techniques gives these patients a chance to retain the best possible joint alignment and function following the injury. However, due to the vast number of novel techniques, and the lack of long-term follow up studies it is difficult to determine which technique will become the next ‘gold standard’.

The major advantage of using a percutaneous or arthroscopic approach is the small incision, which decreases the chance for a major post-op infection or wound, which is especially valuable for a patient with lowered tissue healing capabilities. More specific techniques such as the Brixian Bridge or Endobutton assisted technique have shown good results in studies, but it is unlikely they will become widely accepted due to the specific equipment and training needed to properly perform them. Balloon Kyphoplasty with the injection of bone cement is becoming increasingly popular, as

the cement offers a way to reduce a depression fracture quickly and easily with decreased healing time. However, long term follow up studies are needed to see how the cement holds up over time. Current research supports the use of minimally invasive surgery to reduce and fix calcaneal fractures with favorable outcomes; however, more studies must be performed to investigate the long term outcomes of these various new techniques before they can be adopted as the new gold standard of treatment.

AUTHORS' CONTRIBUTIONS

All authors contributed to the design of the paper, and performed literature searches and inclusion/exclusion criteria. All authors contributed equally in the writing of this report and reviewed the final version for submission.

STATEMENT OF COMPETING INTERESTS

The authors declare that they have no competing interests.

REFERENCES

1. Potter, M. Q., and J. A. Nunley. "Long-Term Functional Outcomes After Operative Treatment for Intra-Articular Fractures of the Calcaneus." The Journal of Bone & Joint Surgery 91.8 (2009): 1854-860. Web.
2. Florin Bica, F. "The Role of Computed Tomography in the Diagnosis and Treatment of Calcaneal Fractures ." Journal of Medicine and Life 7.Spec Iss 3 (2014): 99–102. Print.
3. Arastu, Mateen, Brendan Sheehan, and Richard Buckley. "Minimally Invasive Reduction and Fixation of Displaced Calcaneal Fractures: Surgical Technique and Radiographic Analysis." International Orthopaedics (SICOT) International Orthopaedics 38.3 (2013): 539-45. Web.
4. Rodriguez-Merchan, E. C., and E. Galindo. "Intra-Articular Displaced Fractures of the Calcaneus : Operative vs Non-Operative Treatment." *International Orthopaedics* 23.1 (1999): 63–65. *PMC*. Web. 31 Dec. 2015.
5. Singh, A. K., and K. Vinay. "Surgical Treatment of Displaced Intra-Articular Calcaneal Fractures: Is Bone Grafting Necessary?" *Journal of Orthopaedics and Traumatology : Official Journal of the Italian Society of Orthopaedics and Traumatology* 14.4 (2013): 299–305. *PMC*. Web. 3 May 2016
6. Su, Yanling et al. "Bohler's Angle's Role in Assessing the Injury Severity and Functional Outcome of Internal Fixation for Displaced Intra-Articular Calcaneal Fractures: A Retrospective Study." *BMC Surgery* 13 (2013): 40. *PMC*. Web. 3 May 2016.
7. Wang Q, Chen W, Su Y, Pan J, Zhang Q, Peng A, Wu X, Wang P, Zhang Y. Minimally invasive treatment of calcaneal fracture by percutaneous leverage, anatomical plate, and compression bolts–the clinical evaluation of cohort of 156 patients. J Trauma. 2010;69(6):1515–1522. doi
8. Robinson, Yohan et al. "Kyphoplasty in Osteoporotic Vertebral Compression Fractures - Guidelines and Technical Considerations." Journal of Orthopaedic Surgery and Research 6 (2011): 43. PMC. Web. 29 Dec. 2015.
9. Kulkarni, Himanshu Gurunath et al. "Plating for Intra-Articular Calcaneal Fractures…. Is It an Overkill?" Journal of Clinical Orthopaedics and Trauma 6.3 (2015): 153–159. PMC. Web. 28 Dec. 2015.
10. Clark LG (1855) Fracture of the os calcis. Lancet 65(1651):403–404
11. Essex-Lopresti P (1952) Mechanism, reduction technique and results in fractures of os calcis. Br J Surg 39:395–419
12. Goff C (1938) Fresh fractures of the os calcis. Arch Surg 36:744–765
13. Rausch, Sascha et al. "A Biomechanical Comparison of Fixed Angle Locking Compression Plate Osteosynthesis and Cement Augmented Screw Osteosynthesis in the Management of Intra Articular Calcaneal Fractures." *International Orthopaedics* 38.8 (2014): 1705–1710. *PMC*. Web. 31 Dec. 2015.

14. Rak, Vaclav, Daniel Ira, and Michal Masek. “Operative Treatment of Intra-Articular Calcaneal Fractures with Calcaneal Plates and Its Complications.” Indian Journal of Orthopaedics 43.3 (2009): 271–280. PMC. Web. 29 Dec. 2015.
15. Kienast, B et al. “Early Weight Bearing of Calcaneal Fractures Treated by Intraoperative 3D-Fluoroscopy and Locked-Screw Plate Fixation.” The Open Orthopaedics Journal 3 (2009): 69–74. PMC. Web. 29 Dec. 2015.
16. Folk JW, Starr AJ, Early JS (1999) Early wound complications of operative treatment of calcaneus fractures: analysis of 190 fractures. J Orthop Trauma 13(5):369–372
17. Boberg, J, Downey, M, Nakra, A, Rabjohn, L. McGlamry’s comprehensive textbook of foot and ankle surgery 4e, 2013 Wolters Kluwer Health, Lippincott Williams and Wilkins
18. Ouida LB, Douglas RD, William TO. Incidence of hardware-related pain and its effect on functional outcomes after open reduction and internal fixation of ankle fractures. J Orthop Trauma. 2001;15:271–274. doi: 10.1097/00005131-200105000-00006
19. Rammelt, Stephan et al. “Severity of Injury Predicts Subsequent Function In Surgically displaced Intra-articular Calcaneal Fractures” Clinical Ortapoedics and Related Research. Sept 2013. 471(9): 2885–2898.
20. Bucholz RW, Henry S, Henley MB. Fixation with bioabsorbable screws for the treatment of fractures of the ankle. J Bone Joint Surg Am. 1994;76:319–324.
21. Zhang, Jingwei, Baiping Xiao, and Zhijun Wu. “Surgical Treatment of Calcaneal Fractures with Bioabsorbable Screws.” *International Orthopaedics* 35.4 (2011): 529–533. *PMC*. Web. 31 Dec. 2015.
22. Wang, Qingxian, Wei Chen, Yanling Su, Jinshe Pan, Qi Zhang, Aqin Peng, Xirui Wu, Pengcheng Wang, and Yingze Zhang. “Minimally invasive treatment of Calcaneal Fracture by Percutaneous Leverage, Anatomical Plate, and Compression Bolts--The Clinical Evaluation of Cohort of 156 Patients.” The Journal of Trauma: Injury, Infection, and Critical Care 69.6 (2010): 1515-522. Web.
23. Schepers T, Vogels LMM, Schipper IB, Patka P. Percutaneous reduction and fixation of intraar-ticular calcaneal fractures. Orthop Traumatol. 2008;20:168–175.
24. Schepers, Tim. “The Sinus Tarsi Approach in Displaced Intra-Articular Calcaneal Fractures: A Systematic Review.” International Orthopaedics 35.5 (2011): 697–703. PMC. Web. 28 Dec. 2015.
25. Pezzoni, Massimo, Andrea Emilio Salvi, Mirco Tassi, and Salvatore Bruneo. "A Minimally Invasive Reduction and Synthesis Method for Calcaneal Fractures: The “Brixian Bridge” Technique." The Journal of Foot and Ankle Surgery 48.1 (2009): 85-88. Web.
26. Halil Atmaca, Kaya Memisoglu, Tuncay Baran, and Cumhur Cevdet Kesemenli (*2015*) Treatment of Calcaneal Fractures with Closed Reduction and the Endobutton-Assisted Technique. Journal of the American Podiatric Medical Association: January 2015, Vol. 105, No. 1, pp. 33-41.
27. Labbe, J.l., O. Peres, O. Leclair, R. Goulon, P. Scemama, and F. Jourdel. "Minimally Invasive Treatment of Displaced Intra-articular Calcaneal Fractures Using the Balloon Kyphoplasty Technique: Preliminary Study." Orthopaedics & Traumatology: Surgery & Research 99.7 (2013): 829-36. Web.
28. Jacquot, Frederic et al. “Balloon Reduction and Cement Fixation in Calcaneal Articular Fractures: A Five-Year Experience.” International Orthopaedics 37.5 (2013): 905–910. PMC. Web. 28 Dec. 2015.
29. Biggi, Francesco, Stefano Di Fabio, Corrado D'Antimo, Francesco Isoni, Cosimo Salfi, and Silvia Trevisani. "Percutaneous calcaneoplasty in displaced intraarticular calcaneal fractures. " National Center for Biotechnology Information. U.S. National Library of Medicine, 8 June 2013. Web. 28 Dec. 2015.
30. Lian, Kai et al. “The Mineralized Collagen for the Reconstruction of Intra-Articular Calcaneal Fractures with Trabecular

Defects." Biomatter 3.4 (2013): e27250. PMC. Web. 28 Dec. 2015.
31. Thordarson DB, Bollinger M. SRS Cancellous Bone Cement Augmentation of Calcaneal Fracture Fixation. Foot & Ankle Int. 2005;26:347–352.
32. Abdelgaid, Sherif Mohamed. "Closed Reduction and Percutaneous Cannulated Screws Fixation of Displaced Intra-articular Calcaneus Fractures." Foot and Ankle Surgery 18.3 (2012): 164-79. Web.
33. Backes, Manouk, Tim Schepers, M. Suzan H. Beerekamp, Jan S. K. Luitse, J. Carel Goslings, and Niels W. L. Schep. "Wound Infections following Open Reduction and Internal Fixation of Calcaneal Fractures with an Extended Lateral Approach." International Orthopaedics (SICOT) International Orthopaedics 38.4 (2013): 767-73. Web.
34. Ene, R et al. "Low Complications after Minimally Invasive Fixation of Calcaneus Fracture." Journal of Medicine and Life 6.1 (2013): 80–83. Print.
35. Buckley, Richard E., and Robert N. Meek. "Comparison of Open Versus Closed Reduction of Intraarticular Calcaneal Fractures." *Journal of Orthopaedic Trauma* 6.2 (1992): 216-22. Web.
36. Eastwood, Deborah M., and Roger M. Atkins. "Lateral Approaches to the Heel A Comparison of Two Incisions for the Fixation of Calcaneal Fractures." *The Foot* 2.3 (1992): 143-47. Web.
37. Weber M, Lehmann O, Sagesser D, Krause F. Limited open reduction and internal fixation of displaced intra-articular fractures of the calcaneum. J Bone Joint Surg Br. 2008;90:1608–1616. doi: 10.1302/0301-620X.90B12.20638
38. Yeo, Je-Hyoung, Hyun-Jong Cho, and Keun-Bae Lee. "Comparison of Two Surgical Approaches for Displaced Intra-Articular Calcaneal Fractures: Sinus Tarsi versus Extensile Lateral Approach." BMC Musculoskeletal Disorders 16 (2015): 63. PMC. Web. 29 Dec. 2015.
39. Hospodar P, Guzman C, Johnson P, Uhl R. Treatment of displaced calcaneus fractures using a minimally invasive sinus tarsi approach. Orthopedics. 2008;31:1112. doi: 10.3928/01477447-20081101-08.
40. Jain et al. "Osteosynthesis for Intra-Articular Calcaneal fractures" Journal of Orthopaodic Surgery 2007; 15(2):144-8
41. Bano, Artan et al. "Intra-Articular Calcaneal Fracture: Closed Reduction and Balloon-Assisted Augmentation with Calcium Phosphate Cement." Cases Journal 2 (2009): 9290. PMC. Web. 28 Dec. 2015.
42. Abdelazeem, Ahmed et al. "Management of Displaced Intra-Articular Calcaneal Fractures Using the Limited Open Sinus Tarsi Approach and Fixation by Screws Only Technique." International Orthopaedics 38.3 (2014): 601–606. PMC. Web. 28 Dec. 2015.

The Effects of Foot Orthoses on Achilles Tendinopathy in Runners: A Systematic Review

Maria C. Cifone, BS and Hye Jin Yoo, BS

Abstract

Introduction
Achilles tendinopathy (AT) is one of the most common musculoskeletal disorders in runners. If not treated appropriately in the early stages it can lead runners to become disabled or require surgical intervention. The development of AT is multifactorial and thus remains a challenge to the practitioner when it come to treatment strategies. Foot orthoses are an effective treatment modality for runners with this entity. While various mechanisms for exactly how orthoses manage AT have been proposed (via analysis of biomechanics, kinetic, and kinematic effects), only recently has a specific mechanism been suggested in the literature. The purpose of this literature review is to highlight the mechanisms by which orthoses exert their effect and review the biomechanical, kinetic, and kinematic effects they have on runners with AT. As podiatrists, it is important to understand these mechanisms so one may provide effective treatment and work to prevent Achilles tendinopathy in runners.

Study Design: A Systematic Review of Literature

Methods
An English literature search was conducted on the PubMed database. Three literature searches were conducted independently with the use of the Boolean operator “AND.” Literature searches included: “The effect of foot orthoses on runners” AND “Achilles tendinopathy”; “Achilles tendinopathy” AND “running gait kinetics/kinematics” AND “orthoses” AND “rearfoot control”; and “The effect of orthoses on Achilles tendinopathy in runners” AND “pain reduction.” Inclusion criteria for this study required articles to be within 25 years of publication, only human studies, recreational runners, men and/or women, runners with either achilles tendinitis, tendinosis and/or tenosynovitis, and in the English language. The exclusion criteria included non-runners, animals or cadaveric studies, case reports, and peer-reviewed articles. A total of 15 articles were assessed, and 7 total articles were selected for final review.

Results
A systematic review of the literature resulted in the selection of 7 articles, which met the inclusion and exclusion criteria for this study.

Conclusion
Current literature supports the effectiveness of foot orthotics in preventing and treating AT in runners. Kinematic studies have suggested orthotic intervention specifically reduces Achilles tendon loading in runners who wear foot orthoses. The kinetic reduction in Achilles tendon load suggests how the effect of foot orthoses to both provide symptomatic relief and further prevention of AT in runners.

Key words Achilles tendinopathy, foot orthoses, orthotics, and runners.

Level of evidence: 4

INTRODUCTION

Achilles tendinopathy (AT) is a frequent musculoskeletal injury experienced by runners.[1] One common mechanism of AT injury is from the development of rotational stress to both the tibia and the Achilles tendon when a runner undergoes either excessive or prolonged pronation. However, this is just one of the suggested mechanisms for how injury occurs. AT injury is a multifactorial pathology. Despite the high frequency of AT injuries in runners, many of the mechanisms for how injury occurs have yet to be established in the literature. Thus, better understanding of the biomechanics and etiologies are needed to properly treat the athletes who suffer from AT.[2,3] Foot orthoses are one of the effective conservative treatments for AT and other lower limb injuries as they provide symptomatic relief for runners with AT. The purpose of this paper is to review the biomechanical effects of foot orthoses in managing and/or preventing Achilles tendinopathy.

a. Incidence and morbidity

As previously mentioned, Achilles tendon injuries commonly occur in sporting activities involved with running and/or jumping. A recent study of long-distance runners showed that lower limb injuries account for 9-32.3% of all injuries, and the Achilles injury specifically accounts for 7-9%. This same study suggests that AT generally occurs more often in men than women within the age group of 35-45 years. [4] Most AT injuries are managed conservatively- approximately 25% of AT injuries require surgical intervention in which the frequency of surgery increased with patient age and duration of symptoms in addition to pathological changes in the tendon. Furthermore, 3-5% of patients go onto abandoning sporting activities due to the Achilles injury. [5]

b. Anatomy and function

The Achilles tendon also known as triceps surae is composed of medial and lateral heads of the gastrocnemius and soleus muscles. Its tendon inserts into the upper one third of the posterior calcaneus. During gait, the tendon transmits force from the muscles of gastrocnemius and soleus to the calcaneus. Specifically, soleus is the primary ankle plantarflexor, which gets recruited for concentric plantarflexion late in stance and for limiting dorsiflexion to control anterior movement of the body over the foot during walking and running. [6] On the other hand, gastrocnemius is capable of flexing both at the knee joint and ankle joint as it originates on the posterior surface of the femoral condyles. The triceps surae also plays a role at subtalar joint controlling pronation and supination. A study on cadaveric specimen illustrated that tension of the lateral gastrocnemius caused calcaneal eversion, whereas combined tension of both soleus and gastrocnemius caused a calcaneal inversion. [7] Theoretically, the cross sectional area (CSA) of the tendon is directly related to the stiffness of the tendon. However, studies reported in Mass et. al. show that there is no direct correlation between CSA of the tendon and stiffness. In an *in vivo* study of the CSA of the Achilles tendon, runners generally had a greater CSA compared to non-runners with no difference in the stiffness of the tendon. However, the runners with AT had increased CSA with much less stiffness of the tendon compared to that of healthy runners. The possible explanation is due to the disorganization and degeneration of Achilles tendon and collagen fibers, hyper-vascularization, and increase in extracellular matrix in AT. [8]

c. Pathophysiology

Chronic Achilles injuries result from an inadequate healing response, causing tissue degeneration. A recent *in vitro* study on the effects of different loading levels on tendon stem cell response supports the notion that different stimuli may be responsible for

different forms of degeneration. For instance, the stimuli of small stretches in the Achilles tendon induced differentiation of stem cells into tenocytes whereas the stimuli of larger stretches caused differentiation into adipocytes, chondrocytes, and osteocytes.[9] Thus, this study lends an explanation for mucoid, hyaline, and calcified forms of tendon degeneration. In Achilles tendinopathy, the loss or separation of collagen fibers results in disorganized collagen structure. As a result, it causes the pathological tendon to tolerate less loading and become vulnerable for future injuries.

There are two types of AT, insertional tendinopathy and mid-portion tendinopathy. While the histological characteristics are similar between the two types, the two sites are different in their response to treatments and prognoses. Typically, mid-portion tendinopathy is more common than insertional tendinopathy. In mid-portion tendinopathy, the medial portion of the tendon accounts for most cases and the remaining cases of AT are observed by diffuse tendon changes.[10] In contrast to mid-portion tendinopathy, the insertional tendinopathy is more resistant to conservative treatments and requires more surgical interventions. This may be due to involvement of deep layer of the tendon shown by ultrasonography studies.[10]

d. Risk Factors

There are several extrinsic factors associated with the development of AT in active individuals. For instance, a change in training pattern, such as increased intensity or mileage and/or a reduced frequency of stretching may contribute to developing AT. Also, an individual with a history of Achilles injury has a higher risk of further injury to the tendon. In a clinical setting, inappropriate footwear such as a flexible heel counter can allow for excessive rearfoot pronation. Failure to support the heel causes the foot to rotate quickly from an inverted position to an excessively everted position in midstance, causing a torsional effect on the Achilles tendon. This effect is detrimental and causes most of the pain and tendon degeneration found in affected runners. An intrinsic factor in AT is the lower limb biomechanics of individuals with AT, specifically ones with valgus heels. The other intrinsic factors are tightness and eccentric weakness of the triceps surae. Interestingly, genetics and dyslipidemia have also been suggested to increase the likelihood of developing tendinopathy in runners.[11,12]

e. Running Gait

Running gait greatly differs from normal walking gait.[13] Running gait alters both the kinetic and kinematic parameters which influence various factors (muscle activity, center of pressure, Achilles tendon load, and pain) in runners with AT. Efficiency during running is maintained in two ways. First, through the storage of energy and elastic potential of structures (mainly tendons) and secondly the transfer of energy from one body segment to another.[13] Repetitive cycling of both tendon stretch and recoil is responsible for the many chronic overuse syndromes in runners. The Achilles tendon stretches during the first portion of the stance phase of the gait cycle and recoils to return that energy to runners at the time of push-off. During push-off, the Achilles tendon is exposed to a force of seven times body weight.[14] Despite this large force exerted on the tendon at push-off, the stance phase is actually the most detrimental to the Achilles tendon. During the stance phase, increased rearfoot eversion (excessive pronation) as well as knee flexion during locomotion are reported as “abnormal findings” in the gait cycle.[2] The excessive foot eversion and/or tibial rotation movements during the stance phase can increase the chance of overuse syndromes in runners, which can lead to Achilles tendinopathy.[15]

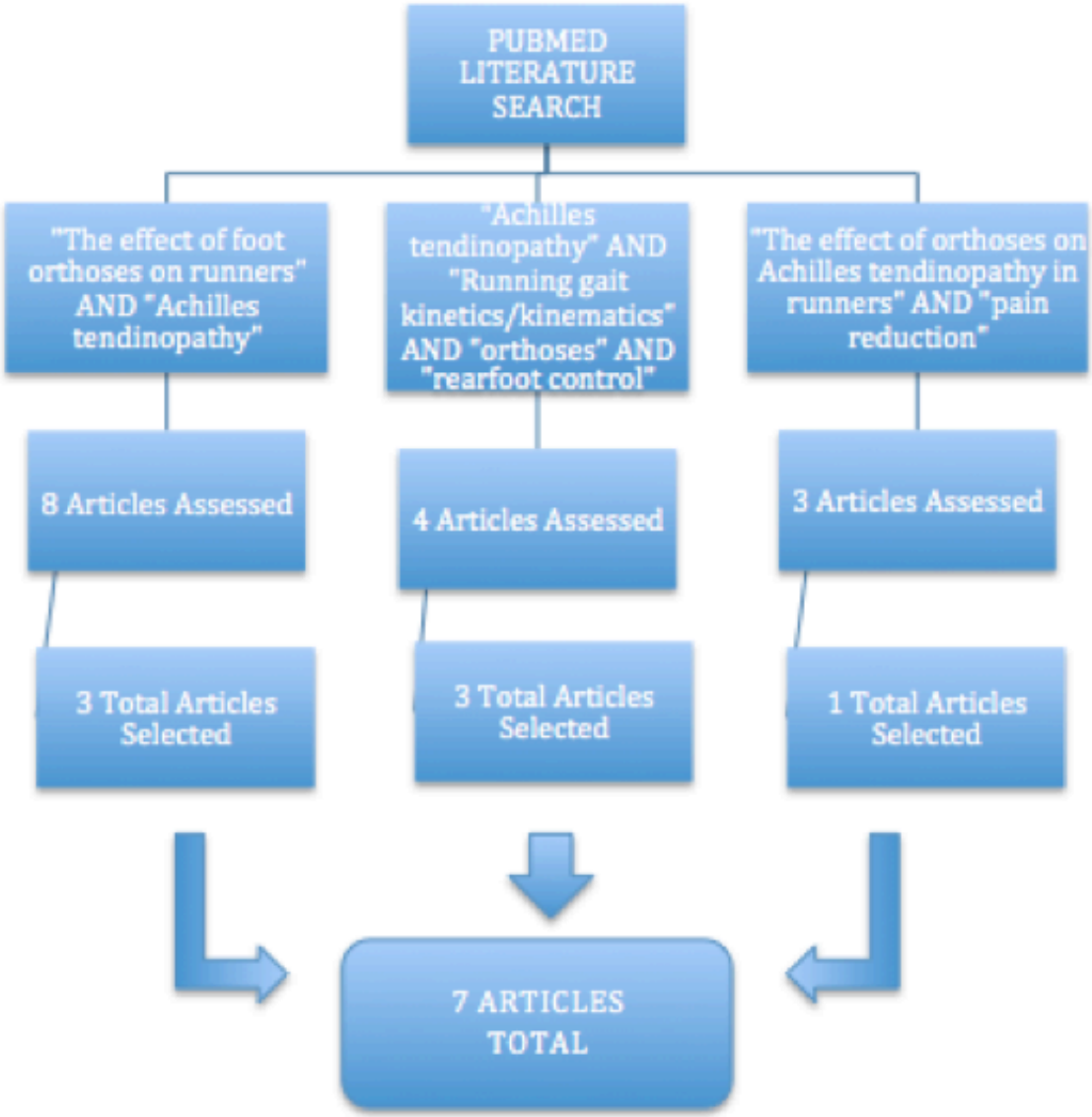

Fig. 1 Literature search conducted on the Pubmed database.

METHODS

An English literature search was conducted on the PubMed database. Three searches were conducted independently. The Boolean operator "AND" was used in the followed literature searches. The first literature search included "The effect of foot orthoses on runners" AND "Achilles tendinopathy." This search provided 8 articles of which 3 were selected for final review. The second search included, "Achilles Tendinopathy" AND "running gait kinetics/kinematics" AND "orthoses" AND "rearfoot control." The results of this second search produced 4 articles of which 3 were chosen for final review. The third search on the PubMed database was "The effect of orthoses on Achilles tendinopathy in runners" AND "pain reduction." This search produced 3 articles, of which 1 was selected for final review. The inclusion criteria for this study required articles to be within 25 years of publication, and could include humans, recreational

runners, men and/or women, runners with either Achilles tendinitis, tendinosis and/or tenosynovitis. Finally, articles selected had to be English journal articles. The exclusion criteria for article selection included non-runners, no animal or cadaveric studies, no case reports, and no peer-reviewed articles. A total of 15 articles were selected for review based on abstract and summary. The methods for this search have been outlined in Figure 1. Finally, a total of 7 articles met the inclusion and exclusion criteria for this study and were selected for final review.

RESULTS

After a thorough literature search 7 articles were selected for the discussion and review. Three articles addressed changes in both gait kinematics and kinetics in runners with AT. Of the three articles only two compared runners affected by AT both with and without orthoses. Two studies were used to address the symptomatic treatment that orthotics can provide runners with AT. Two articles addressed the role of orthotic influence on muscle activity in runners affected with AT. One article addressed the center of pressure on the foot with the use of running orthoses in this running population. Finally, one article reviewed and suggested the mechanism by which orthoses can influence on runners with AT by addressing Achilles tendon loading kinetics.

DISCUSSION

Kinematic Effects of Orthoses

a. Running Gait

Before the negative effects of Achilles tendinopathy in runners can be discussed, the parameters of running gait must be compared to normal walking gait. The normal walking gait cycle includes a double support phase, while runners instead exhibit a "double float phase," or a period where both feet are off the ground.[13] Runners also experience periods of absorption and generation which do not coincide with the timing of initial contact and toe-off, as they do in the normal walking gait cycle.[13] Normally toe-off occurs before 50% of the gait cycle is completed in walking gait, but can occur prematurely in running gait (36-39% of the gait cycle).[13] Runners generally tend to exhibit a forefoot and/or midfoot striking pattern in running gait. These strike patterns differ from the normal rearfoot strike that occurs in walking gait. The forefoot and midfoot strike patterns act to indirectly put more load on the Achilles tendon in runners. This occurs at the initial contact phase of running gait. To be more specific, when runners exhibit forefoot strike running pattern, the eccentric contraction of the gastroc/soleus complex becomes exaggerated (more so than it would at midfoot strike or rearfoot strike) as the heel is lowered to the ground. Therefore, the indirect effect of these strike patterns can have negative effects on the Achilles tendon in runners.

b. Injury Potential in Running Gait

The first half of stance phase in running is the most relevant period of injury occurrence.[13] The Achilles tendon stretches during the first portion of the stance phase of the gait cycle and recoils to return that energy back to the individual at the time of push-off. A total energy turnover in each stance phase of a 70kg man is 100 J when running at 4.5 m/s.[13] Additionally it was estimated that 35 J are stored as strain energy in the heel-cord.[13] As the speed of the runner increases, the initial contact phase progressively changes from hindfoot to forefoot. [15] As the runner moves faster, more of a midfoot or forefoot strike pattern develops which induces a higher incidence of increased rearfoot eversion excursions and eversion velocities during the early stance phase.[16] The cyclical amount of increased eversion over many miles in the runner could induce more strain on the Achilles tendon, leading to injuries. While pronation is necessary for shock absorption

Table 1. Eversion angles with and without orthoses in runners with Achilles tendinopathy [2]

	Orthoses (°)	***No Orthoses (°)***
Heel Strike Angle	- 2.8 ± 4.0	- 4.3 ± 4.3
Maximum Angular Position	19.3 ± 4.5*	16.5 ± 4.0*
Total ROM During Stance	22.0 ± 4.7	20.7 ± 4.7

*Note: *Maximum eversion was the most significant finding in the data collected in this study*

during locomotion especially in runners, the increased rearfoot eversion (excessive pronation) and knee flexion during locomotion could contribute to pathology in the long-run. As a result, runners with AT have been found to have a decreased step length, stride length, and walking speed. [17] Additionally, runners with AT also experience an increased double-limb support phase as compared to healthy runners.[17]

c. Effect of Orthoses on Gait Kinematics in Runners with Achilles tendinopathy

The literature suggests torsional stress (due to increased pronation) on both the tibia and Achilles tendon during the stance phase is one of the main causes for AT in runners. It further suggests that orthotics could decrease this "torsional stress" by reducing two specific parameters responsible for prolonged (or excessive pronation) linked to Achilles tendinopathy, namely ankle dorsiflexion and eversion. [2] A study by Donoghue et al. attempted to address these parameters with the use of custom-molded foot orthoses in 12 runners who suffered from chronic, low-grade Achilles tendinopathy. Each of the orthoses were made from high-density ethylene vinyl acetate and consisted of an arch support and a medial wedge. Both an arch support and medial wedge were implemented to limit and/or reduce ankle dorsiflexion and eversion during the stance phase. Contrary to the proposed mechanism of the orthotic device, the results of this study showed an overall increase in eversion and an insignificant decrease in ankle dorsiflexion. The eversion angle (defined as the segment angle between the rearfoot and the lower leg), indicates inversion-eversion of the rearfoot relative to the lower leg.[2] Table 1 demonstrates the different eversion angles at heel strike, maximum eversion, and range of motion during stance. This study reported that maximum eversion increased in 75% of the individuals and range of motion increased in 42% of the cases.[2]

Collectively on gait analysis (with orthoses), the runners with chronic AT experienced an overall 33% decrease in ankle dorsiflexion maximum and range of motion, while 67% of the data showed no change in these values.[2] The decrease in ankle dorsiflexion was not considered to be a significant decrease, but this effect from the orthotic has implications for deterring mechanisms responsible AT in runners. Ankle dorsiflexion was measured with the ankle dorsiflexion angle. The ankle dorsiflexion angle was defined as the anatomical joint angle between the fibular head, ankle, and fifth metatarsal according to Donoghue et al.[2] Table 2 demonstrates the differences in ankle dorsiflexion for heel strike, maximum ankle dorsiflexion and total range of motion during stance.

Finally, the runners with chronic AT reported an overall decrease in pain while running with the orthoses (despite the increased eversion and decreased dorsiflexion motions induced by the orthoses). While studies prior to Donoghue et al. suggested decreased

Table 2. Ankle dorsiflexion angle with and without orthoses in runners with Achilles tendinopathy[2]

	Orthoses (°)	***No Orthoses (°)***
Heel Strike Angle	2.2 ± 4.4	2.4 ± 5.5
Maximum Angular Position	-20.5 ± 3.7	-21.1 ± 3.3
Total ROM During Stance	22.6 ± 5.6	23.5 ± 5.5

eversion and decreased dorsiflexion were necessary factors for orthotic management of AT, the findings of this study fail to completely support these previous data.[2] Furthermore, this study suggested excessive eversion (alone) is not the primary cause for Achilles tendinopathy in runners.[2] It can be inferred other mechanisms are at play for causing AT, in addition to excessive eversion. This study concluded that gait kinematics related to eversion and ankle dorsiflexion in running could be linked to increased frontal plane motion and decreased sagittal plane motion found in runners with Achilles tendinopathy.

A study by McCrory et al. supported the theory of excessive eversion as the main cause for AT. This counteracts the results reported by Donoghue et al. Despite the fact that McCrory et al. did not assess runners with AT in orthoses, the results reported on kinematic data are comparable to those reported by Donaghue et al. Both studies examined a similar patient population (i.e. runners with AT who demonstrated excessive eversion), as well as the gait kinematics of these individuals. McCrory et al. reported runners with AT exhibited a large calcaneal inversion angle at touch-down during the stance phase and a shorter time to maximum pronation.[18] Table 3 demonstrates the kinematic results reported by McCrory et al. and Donoghue et al. Comparison of these two works indicates that there is no set value for the amount of "abnormal pronation" which correlates to AT development. McCrory et al. suggested excessive pronation is detrimental and leads to development of AT. However, Donoghue et al. used an orthosis which still allowed for pronation (increased eversion) and demonstrated an overall decrease in pain for runners who wore the orthoses. More importantly, implementing effective orthoses poses a challenge since mechanisms for AT injury remain unclear in runners.

Finally, more recent kinematic data provided by Sinclair et al. supported the use of orthoses for reducing Achilles tendon loads in runners with AT. With orthotics, runners experienced increased dorsiflexion moments at the ankle during the stance phase of running gait, resulting in increased lever arm on the Achilles tendon.[19] This leads to an overall decreased tension on the tendon itself and ultimately symptomatic relief for runners suffering from Achilles tendinopathy. It was reported that 11 out of 12 participants exhibited reductions in Achilles tendon parameters as a function of orthotic intervention.[19] Kinematic effects of orthoses from Sinclair et al. and Donoghue et al. are presented in Table 4.

Muscle Activity: Kinetic and Kinematic Parameters induced by Orthoses

The kinematics of the Achilles tendon is important in running gait. Normally, the Achilles tendon dissipates force over time and stores elastic energy during the first half of the stance phase. Then, it returns the 90% of the stored energy during push-off phase,

Table 3. Summary of kinematic effects in stance phase of runners affected by AT without orthotics.

Sinclair 2015	*Donoghue 2008*	*McCrory 1995*
Increased ankle plantarflexion	Increased eversion maximum	Large calcaneal inversion angle at touch-down
Decreased ankle dorsiflexion	Increased ankle dorsiflexion	Shorter time to maximum pronation

Note: The increased eversion maximum is less than the increased eversion maximum (see Table 3).

supporting efficient propulsion.[3] However, if other muscle groups in lower limb have decreased activity, it negatively impacts the Achilles tendon and ultimately alters the kinematics and kinetics of running gait. In addition, as previously mentioned, variations in foot-strike (rearfoot, midfoot, or forefoot) by runners can influence the effect of muscles on the foot, especially at heel contact. This infers that the influence of muscle pull as the foot strikes the ground can play a role in the development of AT in runners.

One study by Azevado et al. reported runners with AT had decreased muscle activity and altered knee kinematics as compared to runners without AT. It was reported that decreased muscle activity of the tibialis anterior (TA), gluteus maximus (GM), and rectus femoris (RF) muscles at different parts of the gait cycle all indirectly produced an increased load on the Achilles tendon in runners, which can cause runners to develop AT.[20] Results of the study demonstrated muscle activity was significantly lower for tibialis anterior at pre-heel strike, and rectus femoris and gluteus maximus at post-heel strike in running gait.[20] Preactivation of the muscles (TA, RF, and GM) at certain parts of the gait cycle all increase the stiffness of the tendon-muscular system to tolerate and absorb impact forces.[20] Therefore, when these muscles fail to "pre-activate" at the designated time for their function in running gait, it's implied that the Achilles tendon is negatively impacted by the remaining forces at heel-strike/shock absorption.[20] Secondly, this study suggested the influence of muscles on knee kinematics in runners with AT had a lower KROM.[20] KROM was defined as the range of motion of knee flexion from heel-strike to midstance.[20] This study found that runners with AT had lower IEMG (integrated electromyographic) activity of the rectus femoris muscle during the stance phase of running.[20] This has a negative impact on the Achilles tendon during the absorptive phase of running because rectus femoris (when weak) fails to reduce strain on the tibia as the knee flexes during the stance phase. When the action of rectus femoris fails (or is diminished), more stress is placed on the Achilles tendon and can promote AT to develop in runners. Overall, it was reported runners with AT have lower muscle activities.[20] Furthermore this study showed that muscle activity and kinematic data could be utilized to distinguish runners with Achilles tendinopathy from uninjured runners.[20] It can be assumed from this study, that if orthoses could be implemented to have an influence on such muscular mechanisms, the management of AT could potentially be achieved.

A study conducted by Wyndow et al. supports the effect of orthoses on muscle activity for managing AT. This study confirmed (via EMG) that individuals with AT are more likely to exhibit premature cessation of soleus muscle activity, while the lateral gastrocnemius stays active for abnormally prolonged periods.[3] Prolonged activation of the lateral gastrocnemius muscle can promote increased pronation beyond

Table 4. Summary of kinematic effects in gait of runners affected by AT with orthotics

Sinclair 2015	***Donoghue 2008***	***McCrory 1995***
Increased ankle dorsiflexion	Increased eversion maximum	N/A
Decreased ankle plantar flexion	Decreased ankle dorsiflexion	N/A
	Knee Flexion	

midstance and ultimately produce negative tension on the Achilles tendon. Overall, this study suggested that runners who wore orthoses (with a varus rearfoot post) demonstrated more symmetrical muscle activation patterns for effective shock absorption, resulting in a more even transfer of force throughout the Achilles tendon.[3]

Kinetic Effects of Orthoses

a. Center of Pressure

Generally in running gait, the center of pressure is focused on the lateral border of the heel during heel strike then moves to the medial aspect of the heel. Afterwards, the center of pressure moves forward to the forefoot, it peaks under the first and second metatarsal heads. However, in runners with AT, the lateral foot rollover pattern reduces the center of pressure at the medial heel in time during contact phase. This causes diminished shock absorption and exerts more stress on the lateral side of the Achilles tendon in AT. Van Ginckel et al. stated that the lateral pattern also causes increased pressure on the medial aspect of midfoot tendon.[21] This shift of pressure encourages increased pronation moment during midstance in runners with AT, resulting in unlocking of the midtarsal joint and increased forefoot mobility. Consequently, the altered biomechanics prevent the foot from acting as a rigid lever during propulsion. This such failure results in a higher active tensile force transferred through the Achilles tendon during propulsion than normal biomechanics does.[21] Chevalier and Chockalingam demonstrated that orthotics correctly direct the center of pressure by re-aligning the altered biomechanics. They prevent excessive pronation of the rearfoot during midstance, which will lock the midtarsal joint.[22] This ultimately decreases the strain on the Achilles tendon during propulsion, providing a symptom of relief in runners with AT.

b. Achilles loading

Another important kinetic factor in AT is Achilles loading. A recent study conducted by Sinclair et al. showed that the peak Achilles tendon load is reduced in the orthotic therapy in contrast to the non-orthotic therapy. Table 5 shows the values corresponding to this finding.[19] The AT is associated with excessive mechanical loading of the tendon, causing intolerable level of loading. Consequently, this initiates collagen and extracellular matrix synthesis and causes degeneration of the tendon.[23] Therefore, decreasing the Achilles tendon load may prevent the occurrence of AT. The orthotics may effectively reduce the Achilles tendon load because the additional midsole cushioning of the orthotic device may increase the dorsiflexion moments at the ankle during stance phase of running. This will provide an increased lever arm on the Achilles tendon, which will reduce tension on the tendon.[19] Therefore, the measurement of Achilles load illustrated the effectiveness of orthotics in runners with AT.

Table 5. Achilles tendon loads as function of orthotic intervention[19]

	No-Orthotic		Orthotic	
	Mean	SD	Mean	SD
Peak plantarflexion moment (N x m x kg)	2.25	0.46	2.18	0.51
Peak Achilles Tendon load (B.W.)	4.84	1.05	4.53	1.05*
Time to peak Achilles Tendon Force (s)	0.13	0.01	0.14	0.01*
Achilles tendon loading rate (B.W.x s-1)	36.58	6.84	32.56	9.52 *

*[a] Note: *= significant difference P < 0.007. [b] Adapted from Sinclair et al, 2014.*

Pain Reduction

Various studies have reported the effectiveness of orthoses on pain reduction in runners who suffer from AT. A study by Mayer et al. found decreased pain in runners with unilateral AT who wore semi-rigid insoles for 4 weeks. More than 50% of the 31 runners in this study reported decreased pain with the use of orthotic intervention alone.[24] Donoghue et al. used high-density ethylene vinyl acetate orthoses which decreased pain in 10 of the 12 runners evaluated in their study. While the use of orthoses has reduced pain in runners with AT, the specific mechanism for this effect has not yet been clearly established in the literature. Some studies indicated the orthoses influence proprioception in the foot, allowing the foot to indirectly "avoid" injury. It is also suggested the orthotic device acts directly on the foot to alter the mechanism of foot function which decreases pain from AT in runners.

CONCLUSION

Achilles tendinopathy is degeneration of tissue due to inadequate tendon healing. Although its occurrence is common in sporting activities such as running, the mechanisms of AT development are not clear. After reviewing the literature it's evident there is not just one mechanism, but many factors which play role in its development of AT. Orthoses are currently one of the most common conservative treatment sought by runners for AT. Many studies support the effectiveness of orthoses for AT, but specifically how the orthosis work is still being examined. In this review, various parameters were analyzed to qualitatively observe the effectiveness of orthotic therapy in Achilles tendinopathy. The parameters studied included kinematic changes in gait, muscle activity, effect on pain, center of pressure, and Achilles loading. These factors uniformly show both the benefits and challenges of orthotic intervention for managing AT. While some studies have shown orthoses reduced pain from AT in runners, the literature is not clear on exactly how orthoses have this effect. Reported data on the reduction of Achilles tendon load (via orthoses) in this review is the most recent data proposing a specific mechanism for the effectiveness of orthoses. The mechanism of

reduced Achilles tendon load could be the link to future studies and more effective orthotic devices for runners with AT. The main limitation of this paper was the use of studies with different types of orthotics, which can cause varying effects on the kinetic and kinematic parameters evaluated. Other limitations include the small sample sizes used in the studies, anatomical variation of the foot of each runner, and different brands of sneakers among runners in each study. Future studies should designate specific foot types and implement treatment in a controlled setting for a substantial period of time. Moreover, further investigation is needed to better understand the etiology of Achilles tendinopathy and to improve the effective parameters of orthoses on the kinetics and kinematics of AT.

AUTHORS' CONTRIBUTION

Maria Cifone and Hye Jin Yoo equally conceived the design of the study, performed the database advanced search and evaluated abstracts. All authors designed figures, read, and approved the rough draft.

STATEMENT OF COMPETING INTERESTS

Maria Cifone and Hye Jin Yoo declare that they have no competing interest.

REFERENCES

1. Van Ginckel A, Thijs Y, Hesar NGZ, Mathieu N, De Clerq D, Roosen P. Intrinsic Gait-Related Risk Factors for Achilles Tendinopathy in Novice Runners: a Prospective Study. *Gait Posture*. 2008; 29: 387-391.
2. Donoghue OA, Harrison AJ, Laxton P, Jones RK. Orthotic Control of Rear Foot and Lower Limb Motion during Running in Participants with Chronic Achilles Tendon Injury. *Sports Biomech.* 2008; 7: 194-205.
3. Wyndow N, Cowan SM, Wrigley TV, Crossley KM. Neuromotor Control of the Lower Limb in Achilles Tendinopathy: Implications for Foot Orthotic Therapy. *Sports Med*. 2010; 40: 715-27.
4. Van Gent RN, Siem D, van Middlekoop M. Incidence and Determinants of Lower Extremity Running Injuries in Long Distance Runners: a Systematic Review. *Br J Sports Med*. 2007; 41: 469-80.
5. Kvist M. Achilles-Tendon Injuries in Athletes. *Sports Med.* 1994; 18: 173-201.
6. Gazendam MGJ, Hof AL. Averaged EMG Profiles in Jogging and Running at Different Speeds. *Gait Posture.* 2007; 25: 604-14.
7. Arndt A, Bruggemann GP, Koebke J. Asymmetrical loading of the Human Triceps Surae: II. Differences in Calcaneal Moments. *Foot Ankle Int*. 1999; 20: 450-5.
8. Maas E, Jonkers I, Peers K, Vanwanseele B. Achilles Tendon Adaptation and Achilles Tendinopathy in Running. *OA Orthop*. 2013;1(3): 25.
9. Zhang J, Wang JH-C. Mechanobiological Response of Tendon Stem Cells: Implications of Tendon Homeostasis and Pathogenesis of Tendinopathy. *J Orthop Res.* 2010; 38: 639-43.
10. Gibbon WW, Cooper R, Radcliffe GS. Distribution of Sonographically Detected Tendon Abnormalities in Patients with a Clinical Diagnosis of Chronic Achilles Tendinosis. *J Clin Ultrasound.* 2000; 28: 61-6.
11. Magra M, Maffulli N. Genetic Aspects of Tendinopathy. *J Sci Med Sport*. 2008; 11: 243-7.
12. Gaida JE, Alfredson L, Kiss ZS. Dyslipidemia in Achilles Tendinopathy is Characteristic of Insulin Resistance. *Med Sci Sports Exerc*. 2009; 41: 1194-7.
13. Novacheck T. The Biomechanics of Running: Review Paper. *Gait and Posture*. 1998; 7: 77-95.
14. Allenmark C. Partial Achilles Tendon Tears. *Clin Sports Med.* 1992; 11: 759-769.
15. Nigg B. The Role of Impact Forces and Foot Pronation: A New Paradigm. *Clin J Sci Med*. 2001; 11: 2-9.

16. McClay I, Manal K. Lower Extremity Kinematic Comparisons between Forefoot and Rearfoot Strikers. *P Am Soc Biomech*. 1995; 211.
17. Kim S, Yu J. Changes of Gait Parameters and Lower Limb Dynamics in Recreational Runners with Achilles Tendinopathy. *J Sports Sci Med.* 2015; 14: 284-289.
18. McCrory J, Martin D, Lowery R, et al. Etiologic Factors Associated with Achilles Tendonitis in Runners. *Med Sci Sports Exerc.* 1999; 31(10): 1374-81.
19. Sinclair J, Isherwood J, Taylor PJ. Effects of Foot Orthoses on Achilles Tendon Load in Recreational Runners. *Clin Biomech.* 2014; 29: 956-8.
20. Azevedo L, Lambert M, Vaughan C. Biomechanical Variables associated with Achilles Tendinopathy in Runners. *Br J Sports Med*. 2009; 43: 288-292.
21. Munteanu S. Barton, C. Lower Limb Biomechanics during Running in Individuals with Achilles Tendinopathy: A Systematic Review. *J Foot Ankle R.* 2011; 4(15).
22. Chevalier TL and Chockalingam N. Foot Orthoses: a review focusing on kinematics. *J Am Podiatr Med Assoc.* 2011; 101(4): 341-8
23. Selvanetti A., Cipolla, M., Puddu, G. Overuse Tendon Injuries: Basic Science and Classification. *Oper Tech Sports Med.* 1997; 5: 110-117.
24. Mayer F, Hirschmuller A, et al. Effects of short-term treatment strategies over 4 weeks in Achilles tendinopathy. *Br J Sports Med*. 2007; 41:e6

Low-Level Laser Therapy in Patients with Diabetic Peripheral Neuropathy: A Systematic Literature Review

Sahar Zadeh, BS, and Daniel J. Stevens, MLS(ASCP)CM

Abstract

Introduction: Low-level laser therapy has been found to decrease diabetic neuropathy and, in turn, improve the healing efficacy of diabetic foot ulcers, the leading cause of lower-limb amputations. Many review articles have been written on the treatment of diabetic foot ulcers using low-level laser therapy, however none have been written focusing on peripheral neuropathy alone. The purpose of this literature review is to examine the effects of low-level laser therapy on diabetic peripheral neuropathy.

Study design: Qualitative Systematic review of Literature

Methods: An English language literature search was conducted using PubMed and Cochrane databases with the keywords “diabetic foot ulcer”, OR “diabetic neuropathy” AND “low-level laser therapy”. Inclusion criteria included: Patients with type 2 diabetes and articles qualitatively evaluating peripheral neuropathy. Qualitative measurement tools include Visual Analog Scale (VAS), Michigan Neuropathy Screening Instrument (MNSI), and Toronto Clinical Scoring System (TCSS). Exclusion criteria included: articles prior to the year 2000 and non-human subjects.

Results: The search yielded a total of 33 articles, 5 of which met all criteria and were selected for review. Of the articles reviewed, four studies concluded significant improvement in peripheral neuropathy outcome, and one study lacked definitive evidence for the effectiveness of low-level laser therapy.

Conclusion: The findings of the literature review suggest that low-level laser therapy can be an effective treatment option for patients with diabetic peripheral neuropathy. Although the majority of the studies selected for review showed significant clinical improvements, more research is needed on different types of lasers and dosage for better reproducibility.

Key Words: Diabetic Peripheral Neuropathy, Low-level laser therapy, Types 2 Diabetes,

Level of Evidence: 4

INTRODUCTION

Diabetes mellitus, a chronic metabolic disorder due to an insufficiency or resistance to insulin, is one of the most common conditions affecting people throughout the world. According to the most recent National Diabetes Statistics Report, in 2012, 9.3% of the population, or 29.1 million Americans, have Diabetes Mellitus.[1] Diabetic sensorimotor polyneuropathy (DSPN) is the most common complication of Type 1 and Type 2 Diabetes Mellitus, leading to functional limitations, pain, and the development of unnoticed foot ulcers. Over 80% of lower limb amputations are a consequence of the infection of foot ulcers or injury.[1] To further emphasize the importance of diabetes related lower-limb amputations, the 5-year mortality rate succeeding amputation is about 39–80%.[1] (Epidemiology of foot ulcers and amputations in the diabetic foot).

Understanding the pathophysiology of Diabetic sensorimotor polyneuropathy is essential to its treatment. Although the mechanism of DSPN is not fully understood, the consensus is that the toxic effects of hyperglycemia play a key role in the disease through multiple mechanisms. The suggested primary route is through hyperactivity of the Polyol pathway causing the depletion of glutathione and ultimately the accumulation of toxic species leading to oxidative stress. Additionally, reactive nitrogen species, specifically peroxynitrite, have an important role in the development of DSPN.[2]

DSPN is often associated with microvascular impairment, which can be further exacerbated by the effects of hyperglycemia. When the microvasculature is altered, peripheral perfusion to nerves is reduced, leading to nerve ischemia. Ischemia can be worsened by increased wall thickness of the basal lamina of the blood vessels supplying peripheral nerves within a neurovascular bundle and also by luminal reduction caused by plasma protein escape leading to edema and a resulting compression of the blood vessels and nerves. Nerve ischemia decreases nerve retraction and regeneration capabilities compared to that of healthy patients. Hyperglycemia has been shown to alter the capacity of Schwann cells and thereby alter myelin sheath formation as well, a possible explanation for decreased nerve conduction velocities so often found in patients with DSPN. An altered microcirculation also contributes to the development of skin ulcers, infections, and gangrene, which can ultimately lead to amputation. The activation of microglial cells after peripheral nerve injury leads to sensorial changes and production of inflammatory mediators such as cytotoxic substances nitric oxide and free radicals.[2]

Patients with DSPN will often present with symptoms of painful burning sensations, cutaneous contact discomfort, or allodynia, deep aching pains, thermal sensation disorders, and abnormal “pins and needles” sensations, or paresthesia. These symptoms often worsen at night, and can result in insomnia, weight loss, anxiety, depression, and overall a poor quality of life. The development of ulcers can affect mobility which can affect patients work and social lives as well.[3,4,5,6]

Most routine therapies for DSPN are directed towards treating symptoms, aimed at relieving pain, and are not centered on the pathophysiological mechanisms. Many different types of pharmacological treatment can be used including narcotic anti-pain relievers, anticonvulsants, phenothiazine, tricyclic antidepressants, opioids and even NSAIDs. However these drugs have been proven to have limited success in relieving painful DSPN and are often accompanied with adverse effects including drowsiness, mood changes, and unsteadiness, which can further interfere with the patient’s daily life. Other therapies, such as topical capsaicin creams, have also proved somewhat

effective, without the systemic adverse effects. Non-pharmaceutical treatments, including low-level laser therapy (LLLT) have yielded generally encouraging therapeutic results in treating pain associated with DSPN, and have high potential to be effective adjunct treatment options.[3,4,5,6]

During an LLLT procedure, the patient is typically oriented in a comfortable prone or supine position, depending on what portion of the foot is to receive the phototherapy. There is usually a fixed distance and angle between the instrument emitting the laser and the area to be treated. A study conducted by Yamani et al. used a fixed position of 30 cm and a scanning angle of 30 ± 15° for 15 minutes at targeted areas. Prior to laser application, targeted areas are typically cleaned with an alcohol based solution in order to dry and minimize light reflection from naturally oily skin. A typical laser emitter is linked to a computer system with specific wavelengths and energy dosages that can be programmed for various uses. During the procedure, both the operator and patient may wear protective glasses to prevent damage from the laser's beam. There is no noticeable heating effect to most LLLT lasers, so the procedures are not painful.[6]

Although the exact mechanism of LLLT is unknown, research findings suggest that it stimulates microcirculation in the affected area, enhances reinnervation of target tissues following injury, increases nerve functional activity, increases the rate of axon growth and myelination, and induces schwann cell proliferation. [3,4,5,6]Many studies have shown the effectiveness of the treatment of diabetic foot ulcers and microcirculatory disorders using LLLT. With this knowledge, one can propose that the combined improvements of tissue and microcirculatory healing will also translate to improvement in nerve function.[3,4,5,6,7] Most recent findings theorize that the proliferation and release of growth factors by different types of cells can be regulated with the use of LLLT. LLLT has shown to stimulate human schwann cell proliferation and NGF gene expression in vitro due to the wavelength (810 nm) emitted.[8] The purpose of this paper is to quantitatively review the literature and analyze the therapeutic effects of LLLT on DSPN.

METHODS

Two independent primary literature searches were conducted using Cochrane and Pubmed databases. The first search was performed on the Cochrane database using the Boolean operators "and" and "or" for the terms ("diabetic foot ulcer", OR "diabetic neuropathy"), AND ("low-level laser therapy" OR "low-intensity laser therapy"). This search provided 4 articles. A second search was performed on the PubMed database using the Boolean operators "and" and "or" for the terms ("diabetic foot ulcer," OR "diabetic neuropathy,") AND ("low-level laser therapy") OR "low-intensity laser therapy." This search provided 29 articles. The total number of articles found using the above mentioned Cochrane and Pubmed searches was 33 articles.

Inclusion criteria comprised articles which included patients with type 2 diabetes, studies using LLLT, also called Low-intensity laser therapy, and articles qualitatively evaluating peripheral neuropathy. Qualitative measurement tools include Visual Analog Scale (VAS), Michigan Neuropathy Screening Instrument (MNSI), and Toronto Clinical Scoring System (TCSS). Exclusion criteria comprised of articles consisting of non-human subjects, patients with Type 1 Diabetes, repeated articles or studies and articles not in English. Articles prior to the year 2000 were also excluded to ascertain all information relevant.

After reviewing the papers for established inclusionary and exclusionary properties, 28

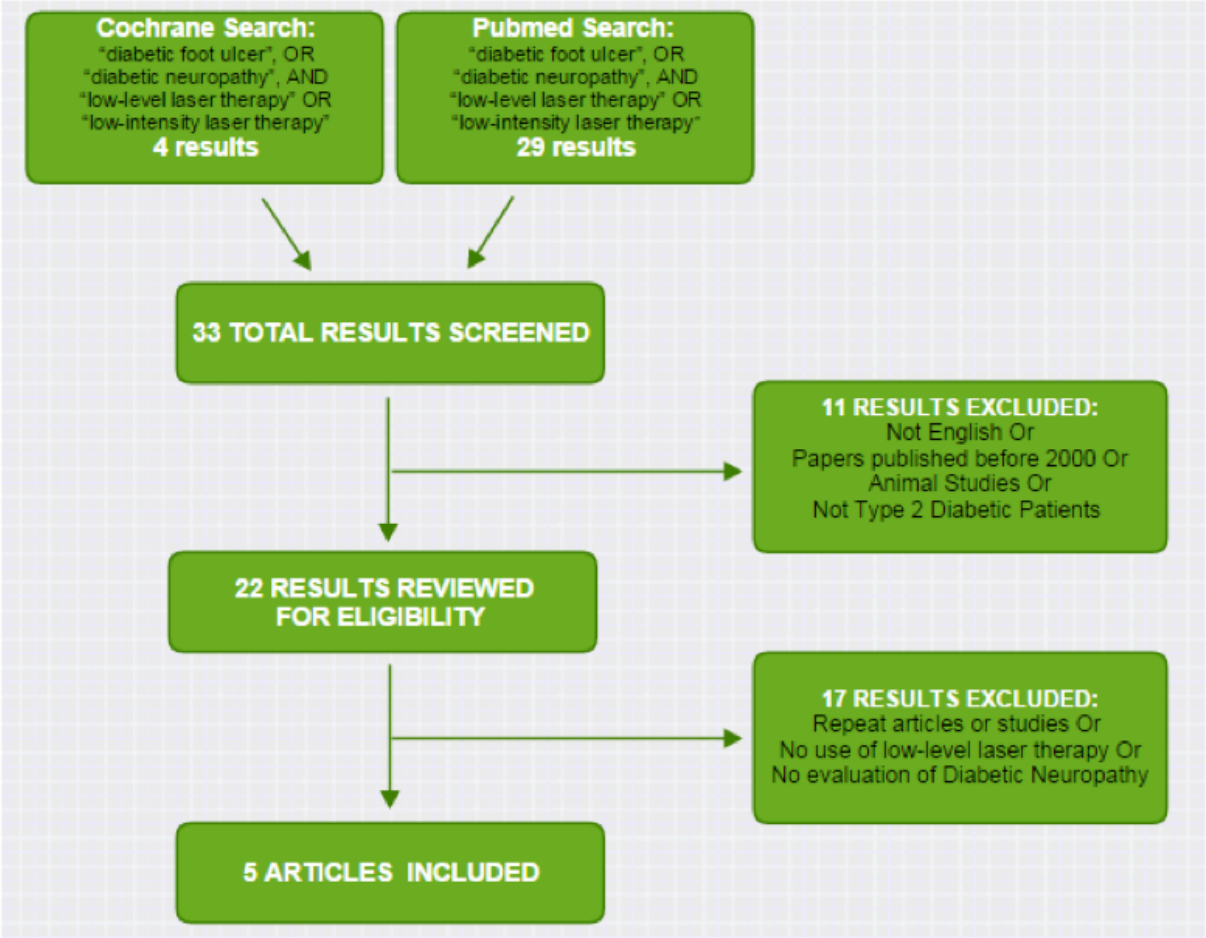

Fig 1. Cochrane databases and PubMed acquisition of papers based on inclusion and exclusion criteria.

of the 33 or 85% of articles found were excluded from the review. From the PubMed database 3 were chosen and 2 were chosen from the Cochrane database.

RESULTS

Of the articles reviewed, four studies concluded significant improvement in peripheral neuropathy outcome, and one study lacked definitive evidence for the effectiveness of low-level laser therapy.

The four studies that concluded improvement of DSPN with LLLT were consistent in regard to both methods and results. In the four studies, pain had to be present in both feet and patients had to have a VAS score of 4 or higher in order to be included. Use of analgesics or adjunct analgesics was permitted however must have been unchanged for at least four weeks before entering the study. Patients were excluded if they had any unstable medical conditions (malignancy, thyroid disease, neurological conditions that would interfere with peripheral neuropathy assessment). Patients were also excluded if pregnant, if they had metallic implants, had alcohol or other illicit drug abuse, or any other symptoms of severe pain.

In the randomized, double blind, sham-laser controlled study by Zinman et al, TCSS was used to diagnose DSPN.[3] In the study by Khamseh et al, MNSI was used to diagnose DSPN.[4] Khamseh et al focused primarily on the effects of LLLT in regards to Nerve

Conduction Velocity (NCV), which demonstrated statistically significant improvement in nearly all participants of the study group, whereas Zinman et al focused primarily on the effects of LLLT on neuropathic pain, using pre- and post-treatment VAS scores as a primary efficacy parameter and did not find statistically significant reductions in pain, although there was some reduction in pain.[3,4] It was mentioned of Zinman et al's study within the Discussion section to highlight the fact that LLLT has shown clinical effectiveness in treating NCV, one of the many aspects of DSPN.[4]

In the randomized, double-blind study conducted by Bashiri, who used TCSS to assess DSPN, a statistically significant reduction in neuropathic pain was observed in the study group in both 2 and 4 weeks post LLLT as compared to pre-treatment. However, a statistically significant reduction

Table 1. Positive effects of LLLT as demonstrated 4 separate studies

Study	Laser	Efficacy Parameters	p-value
Zinman et al	λ905nm average power 0-60mW	Primary: VAS Secondary: TCSS	At 4 weeks intervention (p=0.07)
Khamseh et al	λ808nm, max power 1000mW w/ InGa(A1)As pulse emission 905nm, max power 25 W, pulse duration 100ns, energy per pulse 2.5μJ, frequency 1100Hz, radiant exposure 10Jcm^2	Nerve Conduction Studies (NCS)	Increase in neural potential amplitude at right and left peroneal, right and left sural, and left tibial nerves ($p<0.05$), increase in conduction velocity in right tibial nerve not statistically significant (p=0.482)
Bashiri et al	λ78nm, radiant exposure 2.5j/cm^2	Primary: VAS Secondary: TCSS	2 and 4 week interventions vs. pretreatment VAS: ($p <0.0001$) 2nd week vs. 4th week intervention VAS: ($p < 0.012$) mean differences 2 and 4 weeks intervention vs. pretreatment TCSS: ($p < 0.0001$) 2nd week vs 4th week intervention TCSS: ($p = 0.792$)
Yamany et al	He-Ne laser, λ805nm w/ infrared pulse λ905nm, max power 10 W	NCV, mean nerve amplitude (MNV), microcirculation, VAS	NCV and MNV: peroneal and sural Microcirculation increase at heel, bi VAS: (p=0.0001)

[a]All control (sham laser groups) yielded statistically insignificant changes and are not shown

in pain was not noted when comparing the 4 week to the 2 week interval.[5] These findings are encouraging in regards to outcome, but can also possibly attributed to differences in laser technology. Both studies had similar treatment regimens, in that both study populations were treated two times per week, with laser exposure on each foot for 5 minutes per session, for approximately one month. Bashiri also referenced Zinman et al's study within the Discussion section. The laser used in Zinman et al's study had a wavelength of 905 nm with an average power of 0-60 mW, whereas the laser used in Bashiri's study had a wavelength of 78nm and 2.5j/cm2.[4,5] .Bashari noted the mixed results of each study and recognizing the fact that more research needs to be done on different laser types, lengths of exposure, and also the therapeutic roles of radiation on heat produced by the different types of lasers in order to establish reproducible results.[5]

In the study conducted by Yamany et al, DSPN was diagnosed by abnormal Nerve Conduction Studies (NCS). The study utilized a He-Ne laser with a wavelength of 850 nm coupled with an infrared pulse emitter with a wavelength of 905 nm. The participants in the study were treated 3 times per week for 4 weeks. Statistically significant improvements were observed in NCV, microcirculation, and pain reduction within the study group and not the control group.[6] This study emphasizes the fact that there are several factors that contribute to DSPN and the study proposes ways in which LLLT affects them

The fifth study included within this literature review, by Bril et al, recommended that LLLT should "probably not be used for the treatment of pain associated with DSPN" due to lack of robust supporting evidence.

Although this study fit the inclusion requirements for review, there was not a primary focus on LLLT. Rather, this Systematic Literature Review conducted by Bril et al explored other forms of treatment for DSPN, including pharmacological and other non-pharmacological options.[7]

DISCUSSION

From a physiological perspective, DSPN is not a pathology of the peripheral nerves alone but rather a combination of pathologies involving the microcirculation and the formation of diabetic foot ulcers. As stated earlier, many different forms of treatment exist for DSPN, including pharmacological and nonpharmacological approaches. Among the non-pharmacological therapies is LLLT, which, although it has yield mixed results in clinical studies, has shown improvements in pain reduction and nerve conduction velocities and is an area of high potential for further development.

As mentioned in the Results section, Zinman et al and Bashiri conducted similar studies in regard to design and methods. Both studies utilized the VAS score, which is a graded scoring system from 1 to 10 measuring pain, with 1 indicating no pain and 10 indicating the highest degree of pain imaginable, as a primary efficacy parameter to measure neuropathic pain. Different lasers were used in the studies, which yielded different results. Both studies measured baseline pain, pain at 2 weeks LLLT intervention, and pain at 4 weeks LLLT intervention, utilizing a sham-laser control group.

In Zinman et al's study, both the control group and the LLLT group noticed a reduction in pain at 2 weeks intervention when compared to baseline. The baseline scores were 6.9 ± 1.7 and 7.1 ± 1.9 for the control and LLLT groups, respectfully. After two weeks intervention, the control and LLLT groups dropped VAS scores to 5.4 ± 2.2 (-1.5 ± 0.6) and 5.8 ± 1.7 (-1.3 ± 0.2), respectively. At 4 weeks intervention however, the baseline control group yielded relatively similar pain scores to that of the 2 week intervention control group with a mean score of 5.4 ± 1.9

(-0.0 ± 0.3) whereas the LLLT group continued to reduce pain to a mean score of 4.7 ± 2.1 (-1.1 ± 0.4), the difference between the two groups however were not proven to be statistically significant (p = 0.07, as indicated in Table 1).[3]

In the study conducted by Bashiri, a statistically significant reduction in pain was recorded at 2 and 4 weeks intervention when compared to baseline measurement (p <0.0001), which is a different outcome from that of Zinman et al's study, which yielded reductions in pain that was statistically insignificant (p = 0.07). The mean baseline VAS score was 8.17, the mean 2 week intervention VAS score was 6.2 (-1.97), and the mean 4 week intervention VAS score was 5.9 (-0.3). [5]

The differences in outcome may be attributed to the different lasers used by Zinman et al (λ905nm average power 0-60mW) and Bashiri (λ78nm, radiant exposure 2.5j/cm^2).
The two studies that assessed DSPN response to LLLT through NCS were conducted by Khamseh et al and Yamany et al. Khamseh et al measured NCV of the right peroneal, left peroneal, right tibial, left tibial, right sural, and left sural nerves before and after LLLT intervention. The study demonstrated statistically significant increases in NCV for all nerves tested (p < 0.05) except for the right tibial nerve (p = 0.482).[4] The study conducted by Yamany et al measured the NCV of the peroneal and sural nerves and not the tibial nerves.

Statistically significant increases in NCV were seen in both the peroneal and sural nerves (p = 0.001 and p = 0.0001, respectively).[6] Although the studies utilized different lasers, statistically significant improvements were seen in both. When compared to the studies assessing neuropathic pain, it can be inferred that LLLT is more consistent in improving an objective NCV than reducing pain. The fact that NCV is inherently a more objective measurement than VAS must also be taken into account when interpreting the results of these studies.

One of the elusive answers regarding LLLT is its exact mechanism of action. Many theories have been proposed based on various research studies and the general consensus is that it has a biostimulatory effect on the nervous system.[6,9] Earlier studies have claimed that LLLT can improve reinnervation of tissue following injury.[6,10-12] Other proposed mechanisms of action for LLLT exist, including the prevention of motor cell degeneration, the induction of the proliferation of Schwann cells (which possibly explains the improvement in NCV), the increase in neural metabolism, and the increase in myelination and axonal regeneration.[6,13,14] Other hypotheses suggest that LLLT may affect neural blood flow in a similar mechanism to that of cutaneous blood flow, and may be a contributing factor in improving peripheral nerve function. It has been demonstrated that nerves and blood vessels utilize similar signaling mechanisms and physiological principles in their growth, differentiation, and navigation towards target tissues, suggesting synergistic responses to common stimuli such as a laser. [6,15] Yamany et al proposed that an improvement in skin circulation is most likely due to the release of angiogenic cytokines and growth factors in response to the triggering of a localized area by a laser, in turn promoting vasodilation and the formation of new capillaries. Perhaps this triggering has a similar effect on nerves.

The exact mechanism by which LLLT reduces pain is largely unknown. Yamany et al suggested that the reduction in pain may be due to ATP production by mitochondria, more oxygen consumption by neural cells, anti-inflammatory effects, and/or improvements in blood circulation. Many in vivo and in vitro studies have also revealed that the transmission of nociceptive Aδand C nerve fibers can be inhibited with 830nm lasers.[6]

In a study conducted by Yazdani et al in 2012, the effect of LLLT on Schwann cells was observed in vitro. Schwann cells are located primarily in the peripheral nervous system (PNS) and function in mediating remyelination of demyelinated axons of peripheral nerves. They have also been observed to produce extracellular matrix components such as laminin which aid in the navigation and fixation of axons in their growth patterns. The study utilized a gallium-aluminum-arsenic 810 nm, 50 mW diode laser with energy levels of 1 J/cm2 and 4 J/cm2. LLLT was found to stimulate human Schwann cell proliferation and upregulate Nerve Growth Factor (NGF) gene expression in mRNA.[8]

CONCLUSION

In a broad sense, these studies suggest that improvement of DSPN does not occur by one mechanism alone, but rather, a synchronous action of several systems mediated by a number of cytokines and growth factors. LLLT has been shown to stimulate a positive systemic cascade of events, although non-specifically. Most likely this is due to the various lasers and courses of treatment used. Through the combined actions of angiogenic stimulation, anti-inflammatory mediators, Schwann cell proliferation and action, cytokine recruitment, growth factor gene expression, and nerve regeneration, pain and discomfort associated with DSPN can be reduced.

The research involving treatment of DSPN with LLLT is limited, as only 5 articles meeting the criteria for this review were selected. Many studies have been done on the specific treatment of diabetic foot ulcers using LLLT. The limited amount of literature can be attributed to the wide-scoped focus on diabetic foot ulcers as a primary outcome and less on the underlying mechanisms that lead to their genesis. An effective and specific treatment, like LLLT, may be able to reduce diabetic neuropathy and lead to a reduced incidence of foot ulcers, and in effect reducing amputations. More research is needed to uncover the specifics of these mechanisms, the types of lasers used and their precise effects, and the most appropriate treatment regimens, as to establish reproducible methods and outcomes.

AUTHORS' CONTRIBUTIONS

The authors, S.Z. and D.S., equally contributed to the composition of this manuscript.

STATEMENT OF COMPETING INTERESTS

The authors declare that they have no competing interest associated with this manuscript.

REFERENCES

1. Boulton AJM, Vinik AI, Arezzo JC, Bril V, Feldman EL, Freeman R, Malik RA, Maser RE, Sosenko JM, Ziegler D. Diabetic Neuropathies: A statement by the American Diabetes Association. *Diabetes Care* 2005; 28(4): 956-62.
2. Schreiber AK, Nones CFM, Reis RC, Chichorro JG, Cunha JM. Diabetic neuropathic pain: Physiopathology and treatment. *World J Diabetes* 2015;6(3): 432-44.
3. Zinman LH, Ngo M, Ng ET, Nwe KT, Gogov S, Bril V. Low-intensity laser therapy for painful symptoms of diabetic sensorimotor polyneuropathy: a controlled trial. *Diabetes Care* 2004;27(4):921-4.
4. Khamseh ME, Kazemikho N, Aghili R, Forough B, Lajevardi M, Dabaghian FH, Goushegir A, Malek M. Diabetic distal symmetric polyneuropathy: Effect of low-intensity laser therapy. *Lasers Med Sci* 2011.
5. Bashiri H. Evaluation of Low Level Laser Therapy in Reducing Diabetic

Polyneuropathy Related Pain and Sensorimotor Disorders. *Acta Medica Iranica* 2013; 51(8)544-7.
6. Yamany AA, Sayed HM. Effect of low level laser therapy on neurovascular function of diabetic peripheral neuropathy. *Cairo University: Journal of Advanced Research* 2012; 3: 21-28.
7. Bril V,England J, Franklin GM, Backonja M, Cohen J, Del Toro D, Feldman E, Iverson DJ, Perkins B, Russell JW, Zochodne D. Evidence-based guideline: Treatment of painful diabetic neuropathy. *Neurology* 2011;76(20):1758-65.
8. Yazdani SO, Golestaneh AF, Shafiee A, Hafizi M, Omrani HG,Soleimani M. Effectsof low level laser therapy on proliferation and neurotrophic growth factor gene expression of human Schwann cells in vitro. *Journal of Photochemistry and Photobiology B: Biology* 2012;107: 9-13.
9. Rochkind S, Ouaknine GE. New trend in neuroscience: low-power laser effect on peripheral and central nervous system (basic science, preclinical and clinical studies). *Neurol Res* 1992;14(1):2–11.
10. Rochkind S, Nissan M, Razon N, Schwartz M, Bartal A. Electrophysiological effect of HeNe laser on normal and injured sciatic nerve in the rat. *Acta Neurochir* (Wien) 1986;83(3-4): 125–130.
11. Rochkind S, Nissan M, Lubart R, Avram J, Bartal A. The in-vivo-nerve response to direct low-energy-laser irradiation. *Acta Neurochir* (Wien) 1988;94(1-2): 74–77.
12. Anders JJ, Borke RC, Woolery SK, Van de Merwe WP. Low power laser irradiation alters the rate of regeneration of the rat facial nerve. *Lasers Surg Med* 1993;13(1): 72–82.
13. Barbosa RI, Marcolino AM, de Jesus Guirro RR, Mazzer N, Barbieri CH, de Cássia Registro Fonseca M. Comparative effects of wavelengths of low-power laser in regeneration of sciatic nerve in rats following crushing lesion. *Lasers Med Sci* 2010;25(3): 423–430.
14. Khullar SM, Brodin P, Messelt EB, Haanaes HR. The effects of low level laser treatment on recovery of nerve conduction and motor function after compression injury in the rat sciatic nerve. *Eur J Oral Sci* 1995;103(5): 299–305.
15. Carmeliet P. Blood vessels and nerves: common signals, pathways and diseases. *Nat Rev Genet* 2003;4(9)710–720.

Bone Marrow Edema Syndrome of the Talus: A Case Report and Literature Review

Joseph Waterhouse, BS, and Glenn Weiss, DPM

Abstract

Introduction
Bone marrow edema syndrome (BMES) is a rare diagnosis and is infrequently found in the talus. This uncommon site can lead to a delay in diagnosis and treatment. The patient in this case had a history of smoking, tuberculosis, psoriasis, and corticosteroid injection, all which had to be considered as the etiology of his ankle pain and swelling. Excluding differential diagnoses is essential in the diagnosis of BMES. Imaging modalities such as MRI and bone scan are necessary to do so. Treatment of BMES is mainly conservative with immobilization. New treatment options are being investigated which include extracorporeal shock wave therapy (ESWT) and pulsed electromagnetic fields (PEFs), along with other conservative options.

Study Design: Case Report

Methods and Results
A 63 year old male with a history of tuberculosis and plaque psoriasis presented with a recent onset of right rear foot and ankle pain and swelling. This case report and literature review acts as a unique presentation of a rare pathology with a complex patient history and differential diagnoses.

Level of Evidence: 4

INTRODUCTION

Bone marrow edema syndrome (BMES) of the talus is a rare pathology that may be overlooked in determining the source of ankle pain. Bone marrow edema itself is more commonly associated with the hip and is rarely found in foot bones.[6] The diagnosis of BMES includes increased T2-weighted image signaling coupled with reduced signaling on T1-weighted imaging, without any tendinous, ligamentous, or muscular involvement.[9] In addition to these MRI findings, neither fracture nor bony trauma should be observed. Progression of BMES is often nonspecific in early stages with radiographic evaluation appearing normal followed by eventual progression to osteopenia in later stages.[9] The pain in BMES originates from an increase in interstitial fluid, although the exact pathogenesis is unknown.[6] The etiology of BMES is not well understood, although local ischemic episodes have been suggested as an etiologic factor.[10] Spontaneous osteonecrosis is commonly discussed alongside BMES, but spontaneous osteonecrosis is typically caused by trauma unlike BMES.[10] BMES responds well to conservative treatment, whereas spontaneous osteonecrosis may require surgical intervention. Diagnostic tests are essential in ruling out other causative factors which include osteomyelitis, metastasis, rheumatological disease, and complex regional pain syndrome.

MATERIALS AND METHODS

A 63 year old male with a history of tuberculosis and plaque psoriasis presented with a recent onset of right rear foot and ankle pain and swelling. The patient did not disclose his previous treatment of tuberculosis. There was no history of trauma. The pain and swelling in the area increased throughout the day, and was minimally perceptible in the morning. The patient did not report experiencing morning stiffness. He had previously taken Meloxicam without any symptomatic relief. The patient admitted to cigarette smoking (one pack per day for many years), and denied any known allergies. The patient denied any other significant medical or surgical history.

Physical examination revealed tenderness localized to the antero-medial aspect of the ankle and at the talo-navicular articulation. Two radiographs of the foot and two radiographs of the ankle were ordered and evaluated as negative in the area of chief complaint.

A periarticular injection was performed on the antero-medial right ankle using 0.5cc 1% Lidocaine, 0.5cc 0.5% Marcaine, and 1cc Dexamethasone Phosphate using an aseptic technique to treat a suspected ankle and talonavicular capsulitis. An increased dosage of Meloxicam and bilateral heel lifts were provided to the patient.

The patient was seen three weeks later and patient states that the pain to the ankle was less but related a new onset of pain to the area of the sinus tarsi. There was tenderness on palpation over the sinus tarsi. Voltaren 1% gel was prescribed to the patient along with a referral for formal physical therapy. After three weeks the patient returned with increased pain and diffuse swelling about the ankle. He complained that physical therapy had increased his pain.

Radiographs were then ordered, three views of the ankle. The X-ray report revealed significant soft tissue swelling, but no evidence of any fracture or dislocation indicative of bony abnormality.

Blood labs were also ordered including an arthritis profile, CBC with DIFF/PLT, and Lyme disease antibody. The blood tests were within normal limits for all of the

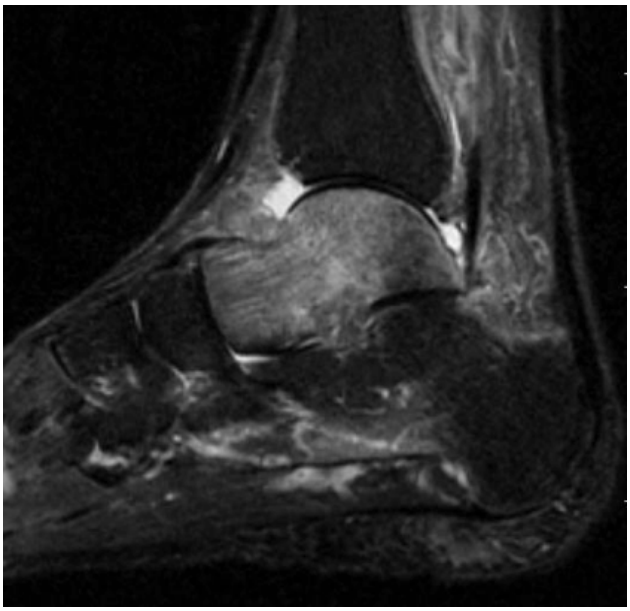

Fig.1 T2-weighted MRI showing bone marrow edema of the talus.

included studies, with exception of mild anemia.

An MRI of the right ankle was ordered [Figure 1]. The MRI revealed severe, diffuse bone marrow edema involving the talus. There was no fracture line noted and no evidence of a gross osteochondral defect. A small tibiotalar joint effusion was noted, as well as mild bone marrow edema involving the calcaneus at the attachment of the interosseous talocalcaneal ligament. Other incidental findings were noted but were not pertinent to the right ankle. The radiologist read the images as representing possible bone marrow edema syndrome of the talus.

There was concern that the soft tissue edema was related to the original injection and that there was a localized infection. A prescription for Augmentin 875mg was prescribed with the instructions to take one tablet every twelve hours until completion. The patient experienced severe nausea and vomiting from the medication and was seen in the ED of a local hospital where additional blood work revealed an elevated leukocyte count of 15,000. In consultation with an infectious disease specialist, the patient was seen the following week for an examination. A repeat CBC with differential demonstrated a normal leukocyte count. An Unna boot was applied to the right lower leg and the patient was given a post-operative shoe. The patient was seen two weeks later and reported that the pain and swelling were reduced. An Indium scan was done and was negative for osteomyelitis.

The patient was given a referral to a rheumatologist for further evaluation. Blood tests were negative for the presence of HLA-B27 antigen.

The pain and swelling spontaneously decreasing following the Unna boot application ultimately led to the diagnosis of BMES of the talus. It also required all other possible differential diagnoses being ruled out.

DISCUSSION

BMES is not an easy entity to diagnose, and in this case the patient's presenting symptoms, medical history, and blood tests led to a number of differential diagnoses.

Tuberculous Osteomyelitis

A history of tuberculosis combined with positive MRI findings make hematogenous tuberculous osteomyelitis a possible diagnosis. Although it is extremely rare, tuberculous osteomyelitis of the talus has been documented.[5] Extrapulmonary tuberculosis (EPTB) inclusive of all organs excluding the lung structures (ie. Pleura, bronchus) had a reported incidence of 19.3% in the European Union and European Economic Area between 2002 and 2011.[7] In 2013 skeletal tuberculosis accounted for 10.8% of EPTB in the United States.[8] The most common sites were the sternum and ribs with only a few documented cases of EPTB in the foot bones.[8] A biopsy consistent with tuberculosis infection of bone would reveal caseating granulomas with acid-fast growth on culture.[2] For the above patient, a negative finding on Indium scan precluded

the need for immediate bone biopsy. A bone biopsy is the definitive diagnostic tool for tuberculous osteomyelitis.

Injection-Induced Osteomyelitis

The possibility of osteomyelitis secondary to corticosteroid injection should be considered in evaluating a patient with increased pain and edema following an injection. The above patient had positive MRI findings which suggested a high index of suspicion of osteomyelitis. This is considered the most severe adverse effect that can result from corticosteroid injection. A systematic review of the literature cites osteomyelitis of the humerus as well as osteomyelitis of the calcaneus having resulted from multiple injections using corticosteroids.[3] An Indium scan can be helpful in ruling this out. Bone biopsy still remains the gold standard.

Psoriatic Arthritis

Rheumatologic disorders must be considered in a patient with a history of psoriasis and diffuse edema of the ankle joint area. Although isolated reports of radiographic changes to the talus are not documented secondary to psoriatic arthritis, the possibility of an extra-articular manifestation needed to be evaluated. Negative blood tests are not definitive, but make the likelihood of involvement less probable.

Metastasis

Ankle pain presenting as a result of metastasis may be considered with the presence of positive MRI findings. Although very rare, there have been cases reported of metastasis from the lungs to the talus.[13] A history of smoking obviously increases the risk of lung cancer, and as a result potential metastasis to foot bones. Pulmonary origin of metastasis to the talus is more likely in a cigarette user, but increased risk of cancer in general can suggest metastasis from a different source. A case of the metastatic spread of a buccal mucosa carcinoma to the talus was reported.[11]

Complex Regional Pain Syndrome

Complex regional pain syndrome (CRPS) is a condition where pain is usually secondary to trauma, fracture, or injury, and is present within a given region or area.[1] The pain is not typically proportional to the precipitating injury, and can involve swelling and patchy bone demineralization.[1] The exact cause of CRPS is not known, although peripheral nerve involvement has been speculated. If there is no history of trauma, CRPS may be less likely, especially if MRI findings are isolated to a single bone and shows improvement with immobilization.

Treatment

The treatment of BMES is primarily focused on immobilization, being that it is mainly considered a self-limiting process.[9] Other additive treatment options are often utilized to accelerate healing and decrease inflammation. Non-steroidal anti-inflammatory medications, physical therapy, and more recently intravenous vasoactive prostacyclin analogues have been prescribed.[9] A prospective randomized controlled trial compared the pain relief and functional improvement of extracorporeal shock wave therapy (ESWT) against intravenous prostacyclin with bisphosphonate when treating BMES of the knee. The result of this study favored ESWT as the more rapid and effective treatment option.[6] There are a number of adverse effects that can result from intravenous prostacyclin use, but studies have shown that addingthis to immobilization treatment (i.e. CAM walker) gives more of a significant advantage in healing than using immobilization treatment alone.[9,13]

The surgical treatment of choice has been cited as core decompression surgery, although this poses additional risks and costs.[6,9]

A recent study examined pulsed electromagnetic fields (PEFs) and its clinical application in treating idiopathic BMES of the talus. Significant improvement was noted within one month on MRI evaluation, and the BME was resolved within three months.[9] A primary advantage of this treatment option is the noninvasive nature compared to other treatment modalities.

CONCLUSION

BMES is an elusive diagnosis that requires meticulous testing to rule out other possible causes of an individual's pain. This case has been reported in order to highlight the unusual presentation of BMES with an interesting patient history of tuberculosis, psoriasis, smoking, and corticosteroid injection. The next step in caring for this patient will be approval for a bone stimulator in order to resolve the patient's pain.

AUTHORS' CONTRIBUTIONS

The authors JW and GW, equally contributed to the composition of this manuscript.

STATEMENT OF COMPETING INTERESTS

The authors declare that they have no competing interest associated with this manuscript.

REFERENCES

1. Abdi, Salahadin, MD, PhD. "Complex Regional Pain Syndrome in Adults: Pathogenesis, Clinical Manifestations, and Diagnosis." Complex Regional Pain Syndrome in Adults: Pathogenesis, Clinical Manifestations, and Diagnosis. UpToDate, 5 Oct. 2015. Web

2. Assari, Raheleh, MD. "Caseous Granuloma:Tuberculosis or Chronic Recurrent Multifocal Osteomyelitis?" *Iran J Pediatr* 24.6 (2014): 770-74. Web.

3. Brinks, Aaltien, Bart W. Koes, Aloysius Cw Volkers, Jan An Verhaar, and Sita Ma Bierma-Zeinstra. "Adverse Effects of Extra-articular Corticosteroid Injections: A Systematic Review." *BMC Musculoskeletal Disorders BMC Musculoskelet Disord* 11.1 (2010): 206. Web.

4. Dahuja, A., G. Dahuja, R. Kaur, and K. Bansal. "English." *MOJ Malaysian Orthopaedic Journal* 8.1 (2014): 61-62. Web.

5. Ebrahimzadeh, M. H. "Isolated Tuberculosis of Talus, an Extremely Rare Occurrence." The Foot 15 (2005), n.d. Web.

6. Gao, Fuqiang, Wei Sun, Zirong Li, Wanshou Guo, Weiguo Wang, Liming Cheng, Debo Yue, Nianfei Zhang, and Amanda Savarin. "Extracorporeal Shock Wave Therapy in the Treatment of Primary Bone Marrow Edema Syndrome of the Knee: A Prospective Randomised Controlled Study." BMC Musculoskeletal Disorders BMC Musculoskelet Disord 16.1 (2015): n. pag. Web.

7. Kulchavenya, E. "Extrapulmonary Tuberculosis: Are Statistical Reports Accurate?" *Therapeutic Advances in Infectious Disease* 2.2 (2014): 61-70. Web.

8. McDonald, Malcolm, PhD, and Daniel Sexton, MD. "Skeletal Tuberculosis." Skeletal Tuberculosis. UpToDate, 18 Aug. 2015. Web.

9. Martinelli, Nicolò, Alberto Bianchi, Elena Sartorelli, Alessandra Dondi, Carlo Bonifacini, and Francesco Malerba. "Treatment of Bone Marrow Edema of the Talus with Pulsed Electromagnetic Fields." *Journal of the American Podiatric Medical Association* 105.1 (2015): 27-32. Web.

10. Patel, Sanjeev. "Primary Bone Marrow Oedema Syndromes." Rheumatology, n.d. Web.

11. Pichi, Barbara, Paolo Marchesi, Valentina Manciocco, Paolo Ruscito, Raul Pellini, Giovanni Cristalli, Valentina Terenzi, and Giuseppe Spriano. "Carcinoma of the Buccal Mucosa Metastasizing to the Talus." Journal of Craniofacial Surgery 20.4 (2009): 1142-145. Web.

12. Sharma, P. Ravi. "Aggressive Giant Cell Tumour of Talus with Pulmonary Metastasis-

A Rare Presentation." Jcdr Journal Of Clinical And Diagnostic Research (2014): n. pag. Web.
13. Singh, D., A. Ferrero, B. Rose, A. Goldberg, and N. Cullen. "Bone Marrow Edema Syndrome of the Foot and Ankle: Mid- to Long-Term Follow-up in 18 Patients." Foot & Ankle Specialist (2015): n. pag. Web.

A Review of Current Case Reports Involving Sports-Related Tarsometatarsal (TMT) Joint Complex Pathologies

Alexandra Black, BA, Rosario Saccomanno, BS, and Jered M. Stowers, BS, BA

Abstract

Introduction
This study is a literature review of current case reports concerning injuries and pathologies of the tarsometatarsal (TMT) or Lisfranc joint complex. These are commonly misdiagnosed sports-related ailments of the midfoot that this article highlights in hopes of raising clinical awareness. The objective of this study is to outline the recent presentations, imaging techniques and treatments found in case reports and case series.

Study Design: Qualitative Systematic Review of the Literature.

Methods
A systematic review of literature was performed in the PubMed database using Boolean search operators and truncation. The search strategy was "Sports AND (Lisfranc* OR Tarsometatarsal"). *Inclusion criteria*: Case reports and case series, printed in English, published as early as January 2005, sports-related, involves tarsometatarsal or Lisfranc pathology. *Exclusion criteria*: Cadaveric or animal studies.

Results
I89 articles were found upon initial search. The first round of screening excluded 60 articles that were non-human, or cadaveric, studies or not case reports and 8 articles that were not printed in English. The second round of screening declined 2 articles that were not printed in English, 7 articles not published before January 2005, and 2 articles not within the scope of sports or sports-medicine. A total of 10 case reports were used and evaluated for the literature review of current case reports.

Conclusions
The aim of this literature review is to provide an in-depth evaluation of sports-related injuries compromising the Lisfranc joint complex. The high rate of misdiagnosis in the athletic population reinforces the fact that clinicians need to keep this pathology in mind when considering appropriate imaging modalities and their differential diagnosis.[1] An increased awareness of this lesser known midfoot injury will allow today's podiatrists to be the leaders in communicating this knowledge to the medical community.

Key Words: Tarsometatarsal, Lisfranc, Midfoot, Sports Medicine, Case Report, Case Series, Literature Review, Basketball, Running, Jogging, Hockey, Misdiagnosis

Level of Evidence: 5

INTRODUCTION

Injury to the tarsometatarsal (TMT) joint complex in a sports-related context can be a challenging condition for athletes to endure and for medical professions to properly treat. Also known as the Lisfranc complex, this functional joint represents the articulation site between the midfoot and the more distal forefoot anatomical structures.[1] The osseous components of the joint consist of the cuboid as well as the medial, intermediate, and lateral cuneiforms articulating with metatarsal bases I-V in the forefoot.[2] This 9-bone configuration provides skeletal integrity to joint complex and constitutes the transverse arch of the foot.[1]

Various ligaments in dorsal, plantar, and interosseous arrangements serve to further stabilize the TMT joint and can be subdivided into intertarsal, intermetatarsal, and tarsometatarsal ligaments. Of particular importance is the first interosseous tarsometatarsal ligament, or Lisfranc ligament, which is typically 1 centimeter long, 0.5 centimeters thick, and plantarly runs from the anterolateral surface of the medial cuneiform to the medial side of the second metatarsal base.[3, 4]

There exists a tarsometatarsal ligament on the dorsal side of the foot that is similar to the Lisfranc ligament, but the plantar ligaments are known to be stronger and thus better stabilize the TMT joint. In addition, the "keystone" or mortise configuration formed by the second metatarsal, which is recessed between the medial and lateral cuneiforms, further stabilizes the TMT joint.[5]

The name for the joint complex is coined after the work of Jacques Lisfranc de St. Martin, a French warfare surgeon who described the midfoot injury resulting from soldiers falling from their combat horses and landing in a plantarflexed (equinus) foot position. He later went on to develop a method for amputation within the functional joint as a surgical intervention for Napoleon's soldiers in 1815. [2, 3, 6] The phrase Lisfranc Injury (LI) can manifest as a disruption to any structure within the joint complex but most commonly results in damage to the soft tissue or osseous features of the second metatarsal bone, which has implications for associated Lisfranc ligament in this area.[3] Deformation in the area of the TMT complex can also manifest as a Lisfranc Ligament Injury (LLI) in which compromise to this ligament can result in instability between the medial cuneiform and the first and remaining

Figure 1. X-ray demonstrating the non-pathological Lisfranc ligament originating from the anterolateral surface of the medial cuneiform (black arrow) to the medial side of the second metatarsal base (white arrow). The small gray arrows outline the second tarsometatarsal joint.[4]

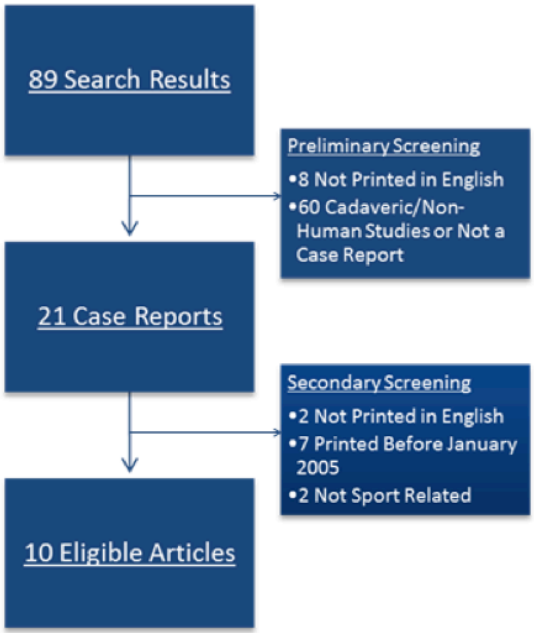

Fig. 2 PubMed Database Search. Search terms: "Sports AND (Lisfranc* OR Tarsometatarsal)"

four metatarsal bases.[7] The last type, Lisfranc Complex Dislocation (LCD), involves osseous displacement within the TMT complex and is scaled by severity based on the Myerson classification system discussed later in the review.[8, 9, 10] In fact, the literature describes multiple classification systems based on the author's intent and metrics for the disorder.

The first classification scheme developed by Quénu and Küss in 1909 arranged Lisfranc injuries into three groups: homolateral, isolated, and divergent.[11] This initial classification of injury was further modified by Hardcastle et al. in 1982. Type A indicates total incongruity, Type B indicates partial incongruity with subgroups B1 (partial medial displacement) and B2 (partial lateral displacement), and Type C indicates divergence.[11] The most used classification system in this review is the Myerson system. The Myerson classification system categorizes the Lisfranc injury into different types: the entire joint can be affected with dislocation of all metatarsal bones (Type A), the first ray (Type B1), one or more of the four lateral metatarsals (Type B2), "divergent" displacement of three or less metatarsal bones (Partial - Type C1), or of all four metatarsal bones (Total - Type C2).[8, 9]

A more recent classification system was developed by Nunley and Vertullo in 2002 to categorize midfoot sprains into three stages of Lisfranc injuries in the athletic population. Stage 1 is defined as a sprain to the Lisfranc ligament with no osseous diastasis or change in arch height. Stage 2 also preserves arch height but includes a 1-5 millimeter gap between first and second metatarsals due to rupture of the Lisfranc ligament. Stage 3 is the most severe classification and includes widening between the first and second metatarsals and rupture of the ligament, as well as a reduction of arch height.[12] Though this classification system is more specific for sports related injuries; the articles involved in this review used the Myerson classification for the diagnoses.

The sports population is particularly vulnerable to compromising this joint due to excessive demands placed on the foot's internal soft tissue and bones during activity. Lisfranc joint injury is considered to be an uncommon malformation seen in the general population, representing fractures in only 1 out of every 55,000 individuals annually in the United States.[13] However, among athletes Lisfranc injuries constitute the second most frequent type of foot injury.[1] Motions such as severe bending stresses, direct vertical force on the calcaneus during metatarsophalangeal dorsiflexion or plantarflexion of the foot, rapid changes in direction, or hyperplantarflexion accompanied with inversion or eversion have all been documented in case reports to increase the risk for or ultimately result in a Lisfranc joint injury. [1, 3, 6, 13, 14]

Despite the high incidence of this type of injury in athletes, the literature also reports approximately 20 percent of TMT joint injuries being either misdiagnosed or missed upon the first medical visit in the athletic

population.[13] The available diagnostic testing modalities upon initial screening include plain X-rays/radiographs (A-P, lateral, and oblique views) and 3-D computed tomography (CT) scans. Despite the potential of overlooking or misdiagnosing deformities within the TMT complex the literature accepts that radiography is gold standard modality in the diagnosis of a Lisfranc injury.[15] The results of the imaging along with further testing often dictate the classification of the Lisfranc joint injury (high-energy or low-energy) and the treatment plan available to rehabilitate the patient, whether that be repair via a graft, internal/external fixation, open/closed reduction, and/or by conservative treatment if the patient opts out of surgical intervention. The objective of this study is to outline the recent presentations found in case reports and case series in hopes to broaden clinical knowledge and awareness for this often overlooked joint pathology.

METHODS

A literature search was performed using the PubMed database. Articles pertaining to sports-related Lisfranc injuries were found by using the following search strategy using Boolean operators and truncation, "Sports AND (Lisfranc* OR Tarsometatarsal)". The inclusion criteria was predetermined to be case reports or case series printed in English and published as early as January 2005 that related to all sport types including running or jogging AND concerned tarsometatarsal or Lisfranc injuries, abnormalities, or pathologies. Cadaveric or animal studies were excluded.

These articles were screened for specific data points for the evaluation and analysis of Lisfranc pathologies following sports-related injuries. The list of characteristics included age, sex, sport, type of injury, mechanism of injury, presentation, R/L foot, imaging, diagnostic finding, official diagnosis, misdiagnosis, initial diagnosis if misdiagnosed, time between diagnosis and initial treatment, pre-intervention treatment, surgical/non-surgical intervention, post-intervention treatment, time to weight-bearing, and time to full recovery. These results were compiled in a series of tables for concise presentation of the overall trends and statistics of the involved studies.

RESULTS

Upon the application of the search parameters, 89 articles were found. During the first round of screening, 60 articles were excluded for being non-human studies or cadaveric studies or not being case reports. Eight articles were not printed in English. 21 articles were case reports and required further screening. On the second round of evaluation, two articles were not in English and seven articles were printed prior to January 2005. Two articles were excluded due to lack of relation to sports or sports-medicine. A total of 10 articles were eligible for this literature review (See Fig. 1).

DISCUSSION

OFFICIAL DIAGNOSES

There were three main categories of diagnoses found in the cases: general Lisfranc injuries, [1, 4, 6, 13, 16] Lisfranc ligament injuries, [3, 14] and dislocations. [2, 5, 17] Of the dislocations, Hirano et al. noted a Myerson type B2 dislocation with a Lisfranc ligament tear and Van Rijn et al. noted a Myerson type A dislocation. Patillo et al. stated that the dislocation was of the tarsometatarsal joint complex specifically of metatarsal bones I, II, and III. This description implies a Myerson classification of type C1, but was not directly classified by the authors.

HISTORY AND PRESENTATION

The sports that were implicated in the cases included: football, soccer, running/jogging, wrestling, hockey, and basketball. General exercising was also included for one case due to the patient's career in sports and

Table 1. Official diagnosis found in the review of the literature

Articles	LI	LLI	LCD
Diebal et al.	+		
Haddix et al.	+		
Lorenz et al.	+		
Mintken et al.	+		
Wright et al.	+		
Hatem et al.		+	
Wadsworth et al.		+	
Hirano et al.			†
Patillo et al.			Δ
Van Rijn et al.			§

LI – Lisfranc injury, LLI – Lisfranc Ligament injury, LCD – Lisfranc complex dislocation
† Myerson Type B2
Δ TMJ I, II, III dislocation (Myerson Type C)
§ Myerson Type A

sports instructing and the need for a treatment that allowed them to return to their career. Most individuals were student athletes, but one patient played in the NHL and one patient, as indicated above, was a sports instructor. Of the 10 cases, there were four females, and six males and the age ranged from 14-60 years. There was no significant predominance of left or right foot. This might imply no predisposition for Lisfranc injury on the dominant foot, but dominant side was not reported in any of the cases.

All of patients presented with immediate or short onset pain and swelling. Six of the cases were unable to bear weight immediately after injury. Almost all of the Lisfranc injury and dislocation categories were unable to bear weight, while the Lisfranc ligament injuries presented with pain while moving. This may lead to another way of differentiating the disorders, but there needs to be more cases supporting this claim. A tender or ecchymosed medial midfoot and pain around the tarsometatarsal joint or metatarsal bases I, II, or III were common. One case specified the ecchymosis appeared on the plantar aspect of the medial midfoot.[16] The Myerson type A dislocation presented with prominent medial cuneiform and navicular bones upon physical examination.[5] Only one case had a history of multiple Lisfranc complex injuries.[3] Interestingly, the unique presentations in these three cases may have led to their misdiagnosis being as though they were among the few inaccurately diagnosed upon initial examination.

Sport-related TMT injuries tend to be caused by indirect forces or low-energy trauma.[14] Each case report described an injury induced by indirect forces, which commonly present

Table 2. Diagnostic techniques found in the review of literature.

Articles (*Diagnosis*)	Standard Radiograph	Weight-Bearing Radiograph	CT	3D-CT	MRI
Diebal et al.	-	-	+		+
Haddix et al.	+			+	
Lorenz et al.	-	+	-		
Mintken et al.	- *(misdiagnosis)*, +				
Wright et al.	- *(misdiagnosis)*, +				
Hatem et al.	-				+
Wadsworth et al.	-		+		+
Hirano et al.	+			+	
Patillo et al.	+				
Van Rijn et al.	+			+	

Positive (+) and negative (-) findings on imaging. Positive and negative here indicate the presence and absence, respectively, of a diagnostic pathological finding regarding the tarsometatarsal joint complex using a specific testing modality.

with forced forefoot plantarflexion and abduction, direct vertical force applied to the calcaneus, or axial load placed on the foot during plantarflexion and inversion.[5, 6, 13, 14] In contrast, a direct force is described as a crushing mechanism or "high-energy" trauma typically involved in motor vehicle accidents, resulting in neurovascular compromise, compartment syndrome, soft tissue and subcutaneous damage.[5]

The most common indirect, low-energy trauma, mechanism of injury (MOI) was force applied vertically to a plantarflexed ankle with three of the patients.[1, 2, 16] In two of the cases, a force was directed vertically to the calcaneus while in a dorsiflexed position.[13, 14] One case reported a MOI as a force directly to the plantar aspect of the foot.[6] Two patients injured themselves while rapidly changing direction. [3, 17] There were two MOI's that were ambiguous and vague in the descriptions of "tripped while jogging"[4] and "force applied while jumping a ditch."[5] There were no trends in the mechanisms that fit the three categories of injuries reported in these cases. Most of the reported MOI's fit into multiple categories which makes this metric difficult to use for determining the pathology.

The most complicated MOI involved the patient with multiple Lisfranc injuries. The first injury was recorded as direct force on the calcaneus in dorsiflexion. The second MOI was a vertical load on a plantarflexed foot that may have been misdiagnosed as a dorsal ligament sprain. The most recent injury occurred while rapidly changing directions.[3] It is important to note that all the previous MOI's for this patient were similar to other Lisfranc injury MOI's presented in the other case reports and it has been reported in the literature that a worse outcome is

Table 3. Treatments and outcomes found in the review of the literature

Articles	Pre-Op	Op	Post-Op	Time to Full/Partial Weight-bearing (PWB/FWB)	Return to Sport
Diebal et al.		OR/IF	Cast, Crutches, PT	6 wks. PWB, 10 wks. FWB	12 mo.
Haddix et al.		OR/IF	Crutches, Roll-a-bout™, PT	*n/a* PWB, 16 wks. FWB	6 mo.
Lorenz et al.	Comp. wrap, Crutches, Walker boot	OR/IF	Crutches, Walker boot	*n/a* PWB, 14 wks. FWB	6 mo.
Mintken et al.	Crutches, Ice, Elevation	EF			
Wright et al.		OR/IF			
Hatem et al.	Crutches	OR			
Wadsworth et al.		†		Immediate PWB, 4 wks. FWB	4 wks.
Hirano et al.		Gracilis Tendon Graft		6 wks. PWB, 8 wks. FWB	36 wks.
Patillo et al.	Short leg posterior splint (non-WB)	OR-IF, (Bionix™ absorbable smart-screws)	Short leg posterior split (non-WB)	6 wks. PWB, *n/a* FWB	14 wks.
Van Rijn et al.		CR	Non-WB cast, (2 wks. screw retrieval surgery)	6 wks. PWB, *n/a* FWB	

IF – Internal Fixation, OR – Open Reduction, EF – External Fixation, CR – Closed Reduction
† Conservative approach involved restricted activities (walking, cycling, but no running), semi-rigid thermoplastic orthotics, gait correction, proprioceptive training and taping.

observed in individuals with related injury on the same side as the Lisfranc pathology.[18]

Of the various MOI's related to the Lisfranc joint pathology, an indirect load applied to the

plantarflexed foot is the most common in our review. With enough axial load stress exerted onto the relatively immobile, recessed position of the second metatarsal between the medial and lateral cuneiforms during excessive plantarflexion makes this position highly susceptible to dislocation.[19] That being said, an apparent lack of correlation between mechanism of injury and type of Lisfranc injury has been noted in the literature.[20]

DIAGNOSTIC TECHNIQUES

The diagnostic techniques used to find Lisfranc types of injuries included standard radiography (non-weight-bearing), weight-bearing radiography, CT/3D-CT, and MRI. The individual pathologies differed in the effectiveness of the diagnostic techniques, however.

Lisfranc Injury (LI)

All of the cases involving LI's used standard radiographs. Of the standard radiographs, only one case presented positive findings.[6] Two cases used weight-bearing radiographs resulting in one positive[1] and one negative[13] finding. Three cases used 3D-CT or MRI with only one negative finding.[1]

There were two misdiagnoses in this category of cases[4,16] and both involved standard radiographs that were initially misinterpreted, but correctly diagnosed upon the second round of examination. Despite these preliminary misdiagnoses the clinicians were correct in obtaining X-rays as radiography is the most widely accepted modality in the diagnosis of LI's and most reliable delineating the osseous structures and integrity within the TMT complex.[15] These misdiagnoses were most likely missed by the lack of multiple views including weight bearing and stressed types.

Lisfranc Ligament Injury (LLI)

The two cases that were diagnosed with LLI's were both sent for standard radiographs and both had negative findings. Further imaging with MRI in both cases, and CT in Wadsworth et al., were used and revealed positive findings of the elusive ligament injury. The negative radiographs, and in turn the misdiagnoses, illuminate the need for more extensive imaging of this type of injury or a different radiographic approach such as a stressed abduction view.

MRI was a successful diagnostic marker in both cases involving LLI. This was in part due to MRI being useful for assessing the integrity of ligamentous or soft tissue structures of the TMT complex. This was especially important being as though standard radiography would not have picked up the minute detail of the ligament. CT permits visualization of avulsions, fractures, and malalignment of bone and, therefore, was informative of an avulsion fracture of the second metatarsal base in addition to the positive MRI findings.[3]

Wadsworth et al. presented the patient with multiple previous Lisfranc injuries so this may have played a role in the extra imaging with CT and MRI of this patient. The previous diagnosis was a sprain of the dorsal ligaments of the tarsometatarsal joint. It is unknown if this was the complete problem or if the Lisfranc ligament was already impaired at this time and contributed to the patient's symptoms. This article was the only one that reported using a biomechanical exam for evaluation and diagnosis. Greater knowledge and use of the biomechanical exam would likely increase the accuracy of diagnosing the ligament type Lisfranc injury.

Relating to the biomechanical exam, a detailed analysis including full limb and pelvic evaluation may uncover abnormal patterns in gait, alignment, range of motion, and strength of musculature all of which contribute to tarsometatarsal weakness and susceptibility to injury.[3] For instance, excessive pronation

of the foot, internal rotation of the leg and thigh, and lateral tilting of the pelvis, determined by biomechanical examination, contributed to the repeated injury seen in Wadsworth et al. This particular case report highlights the necessity to assess musculoskeletal/biomechanical weakness, significant hindsight into the prediction and prevention of initial and subsequent pathology.

Lisfranc Complex Dislocation (LCD)

All three patients with LCDs presented positive findings on standard radiographs. 3D-CT imaging was used to confirm the dislocation in two of the reports. [5, 17]

It is notable that the dislocations were the only types of Lisfranc injuries that were detected first on standard radiography, and the dislocation reported by Patillo et al. (TMJ dislocation of metatarsals I, II, III or a Myerson Type C dislocation) was determined solely on standard radiography.

Despite the success of the radiographic technique for this type, Van Rijn et al. reported a misdiagnosis as a midfoot sprain upon the first round of standard radiographs. It was on further pain and swelling that the patient sought a second opinion and further radiographs were taken to reveal the dislocation.

TREATMENT AND OUTCOMES
Lisfranc Injury (LI)

Only two of the articles reported time between diagnosis and treatment, and they were both in the LI category. That time ranged from 2 days to 1 week.[13, 16] The reported pre-treatment interventions included a compression wrap and walker boot,[1] ice and plus elevation,[16] and crutches.[1, 16]
Treatments were almost uniform with all but one case using open-reduction internal fixation (ORIF). This treatment has been recommended as the gold standard for Lisfranc injury [2] and the reduction is suggested to reduce the implications of arthritis.[4] Percutaneous pins, or Kirschner wires (K-wires), can be used in this treatment and were listed in one article.[6] Only one author listed external fixation as their surgical intervention. It is unknown as to how this specific case compared in postoperative outcome due to the lack of information about time to weight bearing or full recovery.

Postoperative treatment included crutches, [6, 13, 16] physical therapy/rehabilitation, [6, 13] a cast,[13] and a Roll-a-bout™ assisted walking device.[6]

Time to full weight bearing ranged from 10-16 weeks while time to full recovery ranged from 6-12 months (See Table 3). Three of the cases reported a full return to their sport by at least 12 months. [1, 6, 13]

Lisfranc Ligament Injury (LLI)

Crutches were the only pre-treatment intervention that was mentioned for the LLI category.[14] The treatments wildly differed, so it is inconclusive as to whether the time before treatment had any effect when comparing the two LLI cases.

Hatem et al. described a manual reduction with percutaneous pins as described above, and a fixed medial cuneiform and second metatarsal. The author did not mention the time it took for the athlete to achieve full weight bearing or to return to sporting activities.

The clinicians in Wadsworth et al. decided that conservative treatment best suited this patient and listed the regiment of interventions used. The patient was restricted in physical activity to cycling or walking without running. A semi rigid thermoplastic orthotic with a 4 degree medial rearfoot post coupled with a 15 degree medial heel skive was used. Along with proprioceptive training, gait correction was controlled by internal

Table 4. Condensed chart for symptoms, indications, and treatments.

	LI	LLI	LCD
Symptoms:	• Pain on weight bearing • Edema • Tender metatarsal bases I, II, III	• Pain on weight bearing • Edema • Tender medial midfoot	• Pain on weight bearing • Edema • ender metatarsal bases I, II, III • Prominent medial cuneiform and navicular bones
Indicated Imaging:	• Weight bearing radiograph • CT/MRI	• CT/MRI	*Per Type*: • ***(A/B2)*** *- All imaging types* • **(C)** - Standard radiography
Gold Standard Treatment:	• ORIF	• Reduction • Conservative	• ORIF/CRIF[22§]

§Gold standard for Lisfranc complex dislocations call for closed or open reductions.[22] The range of treatments found in this review included gracilis graft, ORIF, CRIF (closed).

rotation and pronation. Immediate partial weight-bearing was used in this case with a return to sporting activities at 4 weeks. A full recovery was noted at 12 weeks. This case demonstrated the fastest recovery in this literature review, and it should be noted that this was the only patient treated with conservative methods. The patient was presented with two treatment options by orthopedists. An aggressive and a conservative option were offered and the patient opted for the more conservative route.

Lisfranc Complex Dislocation (LCD)

Hirano et al. with the Myerson type B2 dislocation injury used a relatively novel treatment that is rarely seen in literature. The dislocation and ligament injury were repaired using a gracilis tendon graft. Interference screws were used in the reconstruction surgery to hold the newly placed tendon to the cuneiform and metatarsal. The patient was able to partially bear weight at 6 weeks and fully bear weight at 8 weeks. A full recovery and return to sports was seen at 3 months.

Van Rijn et al. reported a closed-reduction surgery for a patient with Myerson type A dislocation. A bone reduction clamp, K-wires, and cannulated compression screws were used in the treatment. The postoperative treatment included a non-weight-bearing cast, elevation, and screw retrieval surgery at 2 weeks. The patient was able to partially bear weight at 6 weeks. No full recovery information was reported.

Patillo et al. and the NHL player presented the most comprehensive LCD treatment regimen. A non-weight-bearing short leg posterior splint was used as a pre-treatment intervention. The decision was made to treat the patient surgically with ORIF and using Bionix™ bioabsorbable smart screws. These

screws were used to reduce the possibility of hardware malfunction, thus negating the need for future surgery and hardware removal. The patient was then placed in a non-weight-bearing short leg split again, then a cast. At 6 weeks postoperatively the patient was able to bear weight is a walker-boot, compression sleeve, and total contact custom orthotic. A full return to sporting activities was achieved at 14 weeks. At 10 months the patient was rechecked via radiographs and a complete recovery was noted. This case presents some economic complications for future treatment of this type of injury in that the bioabsorbable screws may not be as cost efficient as the normal hardware, and thus might not be available to every patient. Contributing to success post-operatively is the important factor that this patient played in a sport in which the foot was rigidly fixed in a boot, thereby avoiding typical compression from running and reducing pressure that could potentially complicate healing.[2]

CONCLUSION

The purpose of this review of the recent literature involving sport-related Lisfranc pathologies is to reinforce the diagnostician's clinical knowledge of this debilitating injury. When the physician is presented with an edematous, tender and swollen midfoot that cannot bear weight and may present with ecchymosis on the medial side, the differential diagnosis must include a Lisfranc joint or ligament injury (See table 4).

Tarsometatarsal injury is easily overlooked, since it is considered an uncommon injury and does not always exhibit midfoot deformity on clinical examination.[21] Radiographs are not useful for detecting soft tissue damage due to their intrinsic nature. RI and CT imaging, on the other hand, should be employed with particular usefulness for the LLI type, in order to make a proper working diagnosis when assessing the Lisfranc ligament (soft tissues) and detecting small bone avulsions in addition to traditional radiographs. If tolerable, weight-bearing radiographs are especially vital when assessing the degree of displacement, integrity of osseous structures, and any true malalignment of the joint complex. Today's podiatrists should be the most efficient at diagnosing these lesser known pathologies and leading the push to communicate this knowledge within the medical community.

Established by this review is a certain trend of treatment plans (See Table 4). It is the opinion of the authors that Lisfranc injuries (LI) should be treated almost uniformly with ORIF. The Lisfranc ligament injuries (LLI) differed in treatment based on the severity of the patient's symptoms. The less severe or tender presentation called for conservative treatment, whereas the more severe pain indicates reduction with percutaneous pinning. That being said, treatment options should center on diastasis of the joint due to the possibility of arthrosis formation from a ruptured ligament which presented with little pain or tenderness. The patient, of course, has the final say in the treatment approach and may opt for a more conservative treatment when presenting with fewer detrimental symptoms. Finally, the Lisfranc complex dislocations used a wide variety of treatments. In the literature, it is generally accepted that closed reduction with percutaneous pinning is the gold standard. However, the range of treatments might include reconstruction or grafting of the ligament, ORIF, or closed reduction with internal fixation (CRIF). It is the opinion of the authors that the Lisfranc complex dislocation requires some malleability and adaption based on the presentation and patient needs.

Interestingly, this review of the literature includes one case report in which the patient was treated conservatively and had a full return to sport activity within 12 weeks, even with prior Lisfranc injuries. The injuries treated surgically required anywhere from 3 months to a year for return to full function. These findings suggest that further

research into the evaluation of conservative versus surgical management of the Lisfranc injury is necessary to determine the most effective approach in rehabilitating the athlete to maximal medical improvement.

AUTHORS' CONTRIBUTIONS

The authors (AB, RS, and JS) equally contributed to the production of this article. The authors can be reached personally at the following e-mail addresses:

Alexandra Black: Ablack2018@nycpm.edu
Rosario Saccomanno: Rsaccomanno2018@nycpm.edu
Jered Stowers: Jstowers2018@nycpm.edu

STATEMENT OF COMPETING INTERESTS

The authors declare that they have no competing interests associated with this article.

REFERENCES

1. Lorenz DS, Beauchamp C. Functional progression and return to sport criteria for a high school football player following surgery for a Lisfranc injury. *International Journal of Sports Physical Therapy.* (2013); 8(2), 162-171.
2. Patillo D, Rudzki JR, Johnson JE, Matava MJ, Wright R. Lisfranc injury in a national hockey league player: A case report. *International Journal of Sports Medicine*. (2007); 28(11), 980-984.
3. Wadsworth DJ, Eadie NT. Conservative management of subtle Lisfranc joint injury: A case report. *The Journal of Orthopaedic and Sports Physical Therapy.* (2005); 35(3), 154-164.
4. Wright MP, Michelson JD. Lisfranc injuries. *BMJ (Clinical Research Ed.).* (2013); 347, f4561.
5. Van Rijn J, Dorleijn DM, Boetes B, Wiersma-Tuinstra S. Missing the Lisfranc fracture: A case report and review of the literature. *The Journal of Foot and Ankle Surgery: Official Publication of the American College of Foot and Ankle Surgeons*. (2012); 51(2), 270-274.
6. Haddix B, Ellis K, Saylor-Pavkovich E. Lisfranc fracture-dislocation in a female soccer athlete. *International Journal of Sports Physical Therapy*. (2012); 7(2), 219-225.
7. Preidler KW, Wang Y, Brossmann J. Tarsometatarsal joint: anatomic details on MR images. *Radiology*. (1996); 1999(3): 733-736.
8. Stavlas P, Roberts C S, Xypnitos FN. The role of reduction and internal fixation of Lisfranc fracture-dislocations: A systematic review of the literature. *International Orthopaedics.* (2010); 34(8), 1083-1091.
9. Myerson MS, Fisher RT, Burgess AR, Kenzora JE. Fracture dislocations of the tarsometatarsal joints: End results correlated with pathology and treatment. *Foot & Ankle.* (1986); 6(5), 225-242.
10. Welck MJ, Zinchenko R, Rudge B. Lisfranc injuries. *International Journal of the Care of the Injured*. (2014); 46(4): 536-541.
11. Hardcastle P, Reschauer R, Kutscha-Lissberg E, Schoffmann W. Injuries to the tarsometatarsal joint: incidence, classification and treatment. *The Journal of Bone and Joint Surgery*. (1982); 64-B(3): 349-356.
12. Nunley J and Vertullo C. Classification, investigation, and management of midfoot sprains: lisfranc injuries in the athlete. *The American Journal of Sports Medicine*. (2002); 30(6): 871-878.
13. Diebal AR, Westrick RB, Alitz C. Lisfranc injury in a west point cadet. *Sports Health*. 2013; 5(3): 281-285.
14. Hatem SF, Davis A, Sundaram M. Your diagnosis? midfoot sprain: Lisfranc ligament disruption. *Orthopedics*. (2005); 28(1), 2, 75-7.
15. Kaar S, Femino J, Morag Y. Lisfranc joint displacement following sequential ligament sectioning. *The Journal of Bone and Joint Surgery*. (2007); 89(10): 2225-2232.
16. Mintken PE, Boyles RE. Tarsometatarsal joint injury in a patient seen in a direct-access physical therapy setting. *The Journal of*

Orthopaedic and Sports Physical Therapy. (2009); 39(1), 28.
17. Hirano T, Niki H, Beppu M. Newly developed anatomical and functional ligament reconstruction for the Lisfranc joint fracture dislocations: A case report. *Foot and Ankle Surgery: Official Journal of the European Society of Foot and Ankle Surgeons.* (2014); 20(3), 221-223.
18. Rajapakse B, Edwards A, Hong T. A single surgeon's experience of treatment of Lisfranc joint injuries. *Injury.* (2006); 37(9): 914–921.
19. Burroughs K, Reimer C, Fields K. Lisfranc Injury of the Foot: A Commonly Missed Diagnosis. *Am Fam Physician.* (1998); 58(1): 118-124
20. Vuori JP, Aro HT. Lisfranc Joint Injuries. Trauma Mechanisms And Associated Injuries. *The Journal of Trauma: Injury, Infection, and Critical Care.* (1993); 35(1): 40–45.
21. Pease J, Miller M, Gumboc R. An Easily Overlooked Injury: Lisfranc Fracture. *Military Medicine.* (2009); 174(6): 645–646.
22. Watson, T, Shurnas, P, Denker, J. Treatment of Lisfranc joint injury: Current concepts. *The Journal of the American Academy of Orthopaedic Surgeons*. (2010); 18(12): 718-728.

A Comparison of Non-Surgical and Surgical Treatment Options in Diabetic Foot Calcaneal Osteomyelitis: A Literature Review

Tyrone Mavorga, BA, Yasmin Sarraf, BS, and Dhaval Patel, BS

Abstract

Introduction
Osteomyelitis of bone occurs following an infectious hyperemic process. Treatment ranges from conservative (non-surgical i.e. antibiotics, debridement) to aggressive (surgical) and is dependent on several underlying factors such as the length of infection (acute or chronic), infection site and extent of bone involvement. Clinicians can consider using a combination of approaches, and studies have shown successful remission among a variety of treatments, including antibiotics, PMMA beads, hyperbaric oxygen, sural flap, debriding, and partial calcanectomy. Unfortunately, due to its nature as a highly heterogeneous disease and to the pathophysiological differences among patients, there is debate in the literature as to whether it should be managed conservatively or aggressively. The purpose of this literature review is to assess clinical outcome and effectiveness of different treatment modalities on the basis of clinical situations and initial pathogenic status of the heel ulcer in diabetes mellitus patients.

Study Design: Qualitative systematic review of the literature.

Methods
The authors used PubMed to perform an English language literature search using Boolean search operators. The term 'Diabetic Foot Osteomyelitis' was expanded to include the terms 'antibiotics' OR 'surgery'. Inclusion criteria consisted of 'Diabetic Foot Osteomyelitis' found in the Title/Abstract, adults and children, printed in English, published between January 2010 and the present day. Exclusion criteria consisted of non-English articles, cadaveric studies, animal studies, case studies.

Results
106 articles were found following the initial search of *diabetic foot osteomyelitis* with the inclusion criteria that the terms could be found in the Title/Abstract. By expanding the criteria to include the additional terms 'antibiotics' OR 'surgery' and eliminating those which fell under the exclusion criteria, the search narrowed the number of eligible articles for this review to 43.

Discussion
Comparison of treatment approaches to calcaneal osteomyelitis in diabetic patients does not yield a universal approach to care, nor is there conclusive data to suggest when it is appropriate to treat osteomyelitis only medically and when to proceed surgically. A team approach, taking into consideration all variables while also being patient-oriented, is absolutely necessary in order to have positive outcomes for patients.

Key Words: Calcaneus, Osteomyelitis, Diabetic foot infection, Antibiotics

Levels of Evidence: 4

INTRODUCTION

The optimal way to treat osteomyelitis of the foot remains uncertain, with debate in the literature as to conservative (antibiotic) therapy versus non-conservative (surgical) treatment. Osteomyelitis of bone typically begins in patients with diabetic foot infections (DFIs) who have undergone skin degeneration due to neuropathic changes in the surrounding tissue, followed by chronic or severe ulceration. The probe-to-bone test followed by a collection of specimens for culture is a reliable method of diagnosing diabetic foot osteomyelitis when likelihood of infection is high, or excluding when likelihood is low.[1] In the majority of reported diabetic foot osteomyelitis cases, the two most common bacteria at the site of ulceration are *Staphylococcus aureus* followed by *Staphylococcus epidermidis*.[1]

Clinicians have long thought that removal of infected bone was required to arrest the progress of the infections. However, recent studies have shown that a strategic conservative approach using antibiotics first can be an effective solution, and the Infectious Disease Society of America (IDSA) has published a thorough guideline outlining these steps in their 2012 publication, *Clinical Practice Guideline for the Diagnosis and Treatment of Diabetic Foot Infections*.[2] These guidelines encourage physicians to consider initial antibiotic treatment of DFI and suggest further research is necessary before coming to a complete solution. Furthermore, an understanding of complicated DFI management, likely combining conservative and non-conservative surgical treatments, must be more thoroughly researched to gather enough data to drive treatment modalities for all possible causes of DFI.

A combination of approaches and studies that have shown successful remission among a variety of conservative treatments, such as antibiotics, polymethylmethacrylate (PMMA) beads, hyperbaric oxygen, and aggressive treatments, such as sural flap, debriding and partial calcanectomy. Antibiotics may be preferred in cases where patients want to spare the limb. Physicians will usually start patients on an empiric antibiotic therapy, or they may perform a bone culture to tailor the antibiotic to the specific organism infecting the bone. Management of osteomyelitis is particularly difficulut to treat especially in patients with comorbidities that affect vascular supply to the tissue which effectively renders antibiotic delivery to the site ineffective.[38] In such cases a more aggressive approach to eradicate the infection is a calcaneal resection, which removes the non-viable bone while maintaining weight-bearing. Physicians may debride the bone in order to remove dead tissue. The purpose of the debridement is to remove colonizing bacteria along with necrotic tissue in order to stimulate wound healing in a well vascularized patient. Aside from these, there are a number of adjunctive therapies that have begun to emerge. Physicians are investigating newer treatments such as the hyperbaric oxygen chamber, PMMA beads and the sural flap. The hyperbaric oxygen chamber works by distributing oxygen to the area in order to enhance killing of the bacteria and to stimulate wound healing. PMMA beads aid in distribution of the antibiotics to increase its efficacy. The sural flap is a newer microsurgical technique that has the advantage of conserving the vascularization of lower limbs, an especially important concern in diabetics. The purpose of this literature review is to assess clinical outcomes and effectiveness of non-surgical versus surgical treatment modalities on the basis of clinical situations and initial pathogenic status of heel ulcers in diabetes mellitus patients.

METHODS

The authors used PubMed to perform an English language literature search using Boolean search operators. The term 'Diabetic

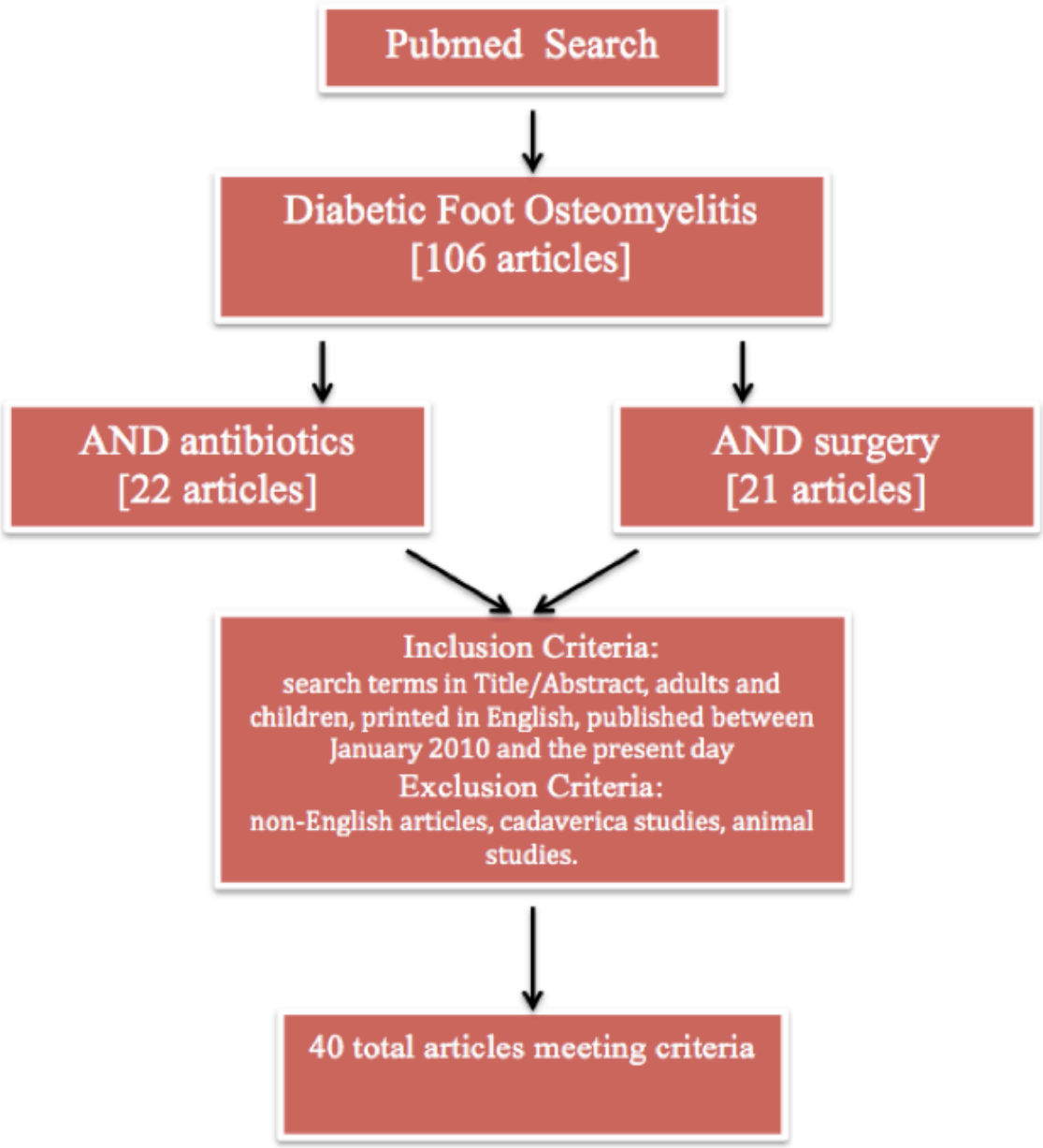

Table 1: Methods Flow Chart

Foot Osteomyelitis' was expanded to include the terms AND 'antibiotics' or AND 'surgery'. This narrowed the number of eligible articles to 43. Inclusion criteria consisted of 'Diabetic Foot Osteomyelitis' found in the Title/ Abstract, adults and children, printed in English, published between January 2010 and the present day. Exclusion criteria consisted of non-English articles, cadaveric studies, animal studies, case studies, further reducing the literature to 40 articles. From these, we chose articles that sought to review at minimum two methods of treatment for osteomyelitis in patients with diabetic foot infection.

RESULTS

Tone et al. compared antibiotic therapy between 6 weeks and 12 weeks with 40 total

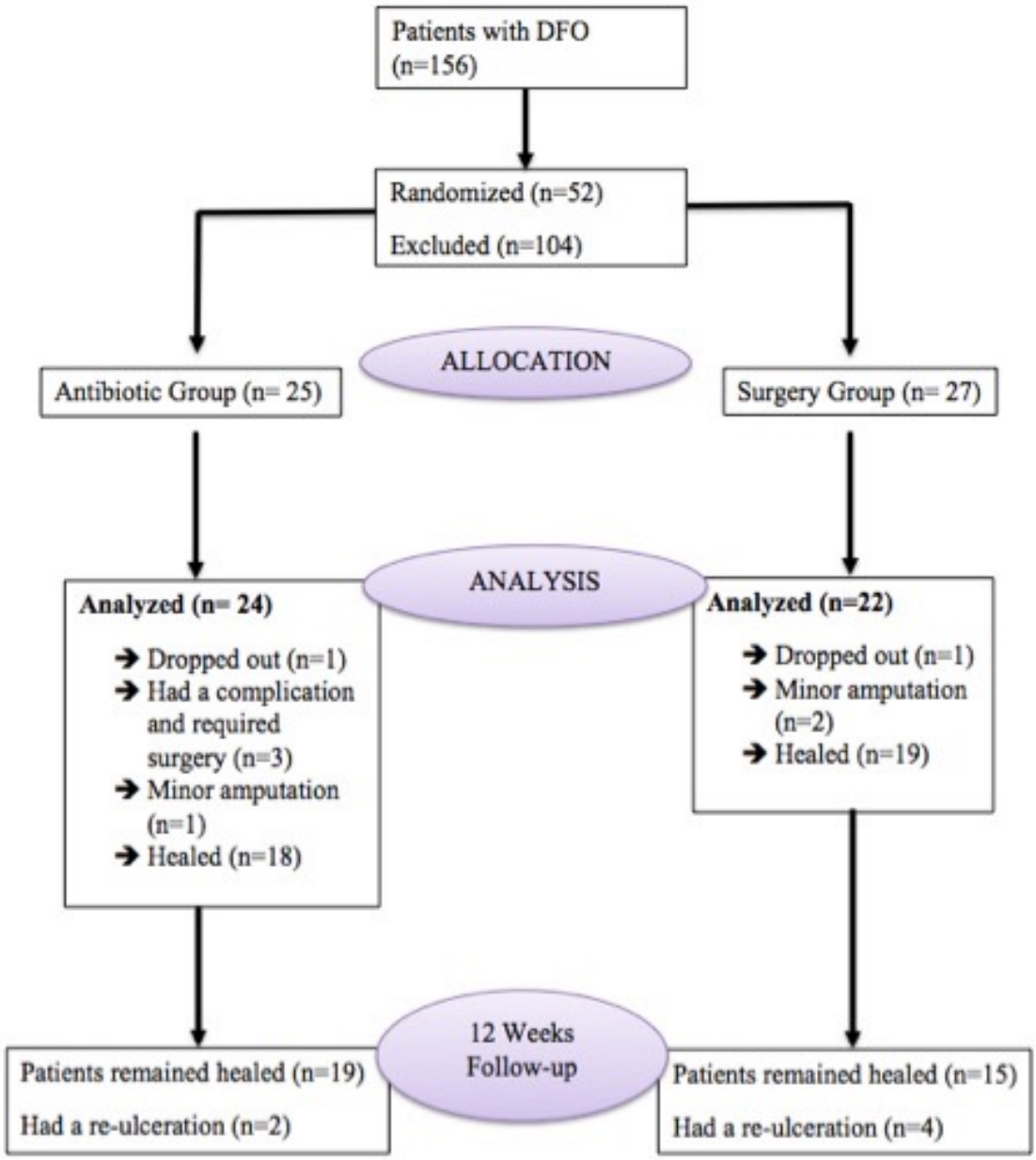

Fig. 1 Flow Charts of Patients[13]

patients. For gram positive cocci, they used rifampin in combination with levofloxacin, trimethoprim-sulfamethoxazole, doxycycline or linezolid. For gram negative bacilli infection, they used levofloxacin or ciprofloxacin in combination with cefotaxime, ceftriaxone or cefepime for the first 2 weeks of treatment and then continued for the rest of the treatment as monotherapy with levofloxacin or ciprofloxacin. The study consisted of 40 subjects where 20 were in the 6 week group and 20 more were assigned to the 12-week group. They found that 30 (75%) patients, 14 (70%) from the 6-week group and 16 (80%) from the 12-week group, were hospitalized for mean duration of 9.2 days with no significant differences between the two groups of patients. At the conclusion of a follow-up duration of 12 months, 26 patients (66%) were considered to be in remission from which 12 (60%) were from the 6-week group and 14 (70%) were

Study	Number of Subjects	Therapy	Objective of the study	Outcome
Tone 2015[26]	40	Antibiotic Therapy	Comparison between 6 and 12 weeks of antibiotic therapy	Similar outcome between 6 and 12 weeks of antibiotic therapy
Panagopoulos 2015[20]	8	Antibiotic loaded (PMMA) beads	Investigation of the effectiveness of PMMA beads	Successful treatment of all patients without surgical removal of beads, and wound healing seen in 6 patients
Boulton 2010[3]	88	Hyperbaric Oxygen (HBO)	Investigation of the effectiveness of HBO	Complete healing of ulcer in 53% patients who received HBO compared to 12% in placebo
Gnatiadis 2010[8]	1	Sural Flap	Investigation the role of sural flap in case report	No evidence or recurrence of osteomyelitis in radiographs and complete healing of the flap at 4 months post-operatively
Ulcay 2014[27]	37	Antibiotic therapy with bone debridement	Comparison of antibiotic therapy with bone debridement and without bone debridement	No significant difference between the group who received antibiotic therapy with bone debridement and the one without bone debridement
Lazaro-Martinez 2014[12]	52	Antibiotic Therapy and Conservative Surgery	Comparison of antibiotic therapy and conservative surgery in patients with osteomyelitis	No significant difference in outcome between antibiotic therapy and conservative surgery
Oliver 2015[19]	42	Calcaneus Resection	Comparison of lower extremity function (LEFS) in patients with less than 50% calcaneus resected and patients with more than 50% calcaneus resected	No significant difference between the outcomes in patients with less than 50% resected calcaneus and in patients with more than 50% resected calcaneus

Table 2 Comparison of OM Treatments

from 12-week group (P=0.50). Therefore, it was shown that an outcome was similar between 6 weeks and 12 weeks of antibiotic therapy.

Panagopoulos et al. investigated the use of implantable drug delivery (IDDS) in case studies across 8 patients with chronic metatarsal or calcaneal DFO. They identified cases where antibiotic loaded (Gentamycin) polymethylmethacrylate (PMMA) cement beads or antibiotic loaded (gentamycin) bone graft substitutes were used to treat osteomyelits. They also used concomitant antibiotics and minor surgery such as MT head resection guided by cultures. Cultures revealed *Staphylococcus* and gram negative bacteria. All the patients were successfully treated and the beads were absorbed within 2 months without surgical removal. Wound healing was seen in 6 patients, and one patient developed an ulcer. No definitive marker was used to characterize what the authors termed a 'successful treatment', however each of the patients that did not develop an ulcer did successfully resolve the osteomyelitis.

Boulton et al. conducted a single-center, randomized, double-blinded, placebo controlled trial where 88 diabetic patients with diabetic foot infections for a minimum of 3 months period were randomized to hyperbaric oxygen HBO (47) or hyperbaric air (41) for 85 minutes a day, 5 days a week for 8 weeks with a maximum of 40 sessions. They found that in the HBO group 37 patients (53%) had complete healing of ulcer. For those who completed more than 35 HBO treatments, 61% from HBO group had healing versus 29% on placebo group (P=0.009).

Ignatiadis et al. presented a case report investigating the role of sural flap in a 46 year old patient with chronic calcaneal osteomyelitis caused by diabetes. The patient had undergone surgical debridement of the calcaneus followed by the sural flap dissection. They showed that, during the first postoperative week, the flap sustained a superficial venous congestion and that approximately 5% of the flap coverage was lost due to skin necrosis. The patient continued the IV antibiotic therapy for 2 months followed by oral antibiotic therapy for more than a 1 month period. Radiographs showed no evidence or recurrence of the calcaneal osteomyelitis. The flap was completely healed at 4 months postoperatively (Figure 1).

Ulcay et al. conducted a retrospective cohort study where they compared antibiotic therapy with and without bone debridement. The outcome showed that there was no significant difference between the group with debridement and without debridement (p=0.243).

Oliver et al. investigated lower extremity function (LEFS) in patients who had less than 50% of calcaneus resected (cohort 1) and more than 50% of calcaneus resected (cohort 2). They compared LEFS score between the two groups. The average LEFS score for cohort 1 was 33.9 and for cohort 2 was 36.2. Therefore, outcomes were similar for both cohorts (P>0.5).

Martinez et al. conducted Randomized Controlled Trial (RCT) comparing antibiotic and conservative surgery for treating diabetic foot osteomyelitis (DFO). Antibiotic treatment initially consisted of the following three regimens: ciprofloxacin 500 mg b.i.d; augmentin 875/125 mg b.i.d; or trimethoprim 160 mg/sulfamethoxazole 800 mg combination b.i.d. The conservative surgery included removal of the infected bone without performing amputation of any part of the foot. There was no significant difference in the size of ulcers (p=0.155) or the duration of the ulcer (p= 0.192). Therefore, there is no significant difference between antibiotic and conservative surgery therapy (Figure 1).

DISCUSSION

The question of what is the most successful treatment in diabetic foot osteomyelitis is still debated today. It is of major concern as diabetics are at high risk for plantar cutaneous ulcerations. A study by Newman et al. found osteomyelitis present in 100% of diabetic foot ulcers in which the bone was exposed.[30] It has been previously thought that bone resection was the remedy for chronic osteomyelitis.[16, 17] However, recent reports have claimed successful cure rates with antibiotic therapy alone.[10] Although both techniques have advantages, currently no study has conclusively compared the efficacy of antibiotics to surgery in order to prove which one is superior. Martinez et al. compared the success rates of antibiotics to surgery and found no major difference. A comparison of treatments for calcaneal osteomyelitis in diabetics does not yield a universal approach to care, mainly because there are many factors to consider when choosing a treatment**.** These factors include: the site of infection, the local vascular supply, the degree of soft tissue and bone destruction, presence of necrosis, systemic signs of infection, and the clinician's and patient's preferences.[15] Thus, physicians today should take these factors into account, as well as the advantages and disadvantages of the specific treatment itself, in order to reach a desired outcome. Further compounding the difficulty in comparing the two treatment modalities is the lack of standardized target outcomes in regards to successful treatment of diabetic foot osteomyelitis. Because of the lack of evidence, we cannot conclude that one treatment is better than another. Despite these obstacles, there is sufficient evidence to direct recommendations in choosing one approach over another.

Antibiotics

One of the most common approaches, especially when it comes to conservative treatment, is treatment with antibiotics. The Diabetic Guidelines describes various situations in which antibiotic management would be the preferred treatment option for osteomyelitis: if radical cure of the infection would lead to unacceptable loss of function, if the patient wishes to avoid amputation, if infection is confined to the forefoot with minimal soft tissue loss, and if the patient and physician agree that the risk of surgery is too high and is not desirable. [2, 5, 6, 22] Patients may opt for antibiotics in order to avoid biomechanical changes that may result from surgery.[4] The extent of perfusion in the patients' limb needs to be taken into consideration when choosing antibiotics. Impaired circulation leaves the limb more prone to infection and can diminish antibiotic effectiveness.

The literature claims a success rate of antibiotic treatment of about 65-80%.[6, 7, 22] When treating DFO with antibiotics, however, no single drug was found to be superior to another.[14, 27] Physicians should consider taking a bone culture to see what organisms are infecting the individual in order to guide their antibiotic treatment regimen. A retrospective study by Senneville et. al, as well as the Tone et al. study demonstrated significantly higher rates of resolution when using antibiotic therapy based on bone culture rather than empiric therapy.[24, 27] In regards to duration of treatment, international guidelines recommend using antibiotics for 12 weeks. However, Tone et al. found that treating for only 6 weeks proved to be just as effective as 12 weeks. This can be useful in avoiding the issue of the emergence of resistant strains. With the continuous use of antibiotics, bacteria have been able to adapt and become resistant, thus rendering the original antibiotic ineffective and forcing drug companies to come up with new formulations. Limiting the treatment to only 6 weeks can leave a smaller window of opportunity for pathogens to develop resistance.

Debridement

Oftentimes physicians debride the bone in conjunction with antibiotic therapy. Debridement is meant to remove any necrotic tissue as well as any callus at the wound site in order to improve healing. By doing so, this process can remove bacteria, permit the formation of granulation tissue and allow the physician to examine if there is deep tissue involvement.[11, 18, 23] The removal of colonizing bacteria helps the process of wound healing.[1, 23] Ulcay et al. decided to study the effectiveness of bone debridement in patients with DFO and did not find significant results. However, this could be due to the fact that this was a retrospective study and that there were only a few cases considered. Therefore more studies need to be conducted in order to shed light on the effectiveness of debridement in conjunction with antibiotic therapy.

Surgery

A more aggressive treatment approach is calcaneal resection, which removes the infected bone. Surgery may seem appealing to some because it seems like a more definitive solution. Physicians may want to consider this approach when certain factors are present, such as a life or limb threatening infection. If the limb is critically ischemic, surgery may be more beneficial than antibiotics because it does not rely as much on blood flow for medication.[20, 21] Based on the patient's case, physicians may opt for a conservative surgery, which includes surgical debridement and a small resection in order to reduce the chance that a large amputation is needed later.[9, 24] Oliver et al. sought to investigate whether the amount of bone resected had a significant influence on LEFS and found that it did not. This could lead surgeons to be more aggressive when choosing how much bone to excise, in order to completely ensure that the infection has been eradicated. However, the study was limited as it was a retrospective study, had a small sample size, and had limited data. A prospective randomized control study may yield more conclusive evidence. Despite the success of surgery, many patients are hesitant about this approach because of the functional consequences that may result, such as weakness and gait dysfunction. Removing bone can result in altered biomechanics, which can lead to transfer ulcerations. While some patients who receive a calcanectomy are able to resolve the infection, many have to deal with the aftermath of partial limb amputation, a major concern among diabetics.[12]

Newer Approaches

There are many adjuncts that are being introduced, such as the hyperbaric oxygen chamber. This treatment is already used to treat diabetic foot ulcers.[15] It works by delivering 100% oxygen to tissues which has various effects that helps the patient fight the infection. Oxygen perfusion leads to enhanced neutrophil killing, stimulation of angiogenesis, enhanced fibroblast and collagen activity and decreased amputation risk.[3] In the end, healing time is accelerated, leading to a decrease in the final treatment cost. Two other new approaches are the sural flap and PMMA beads. The sural flap procedure falls under the surgery category, but it has many advantages compared to the incisions made in a traditional calcanectomy. These include a simpler reproducible design and the fact that microsurgical instrumentation isn't needed; therefore this technique can be used by a greater number of surgeons who might not have access to more expensive medical equipment. It preserves the primary vascularization of lower limbs and can be used in cases of extensive vascular compromise, both of which pertains to diabetics. The drawback with this surgery is that requires sacrificing of the sural nerve, which results in anesthesia on the lateral foot.

PMMA beads are a more conservative treatment and allow medication to be directly released into the area.[19] This can be especially beneficial in diabetics who are

especially prone to lack of perfusion in their lower extremities. There are several disadvantages of PMMA cement in that it is used for short term antibiotic release, can cause thermal damage of the drug and will eventually need to be taken out because it is non-biodegradable.[33] In order to address these issues, calcium phosphate cement beads can be used. Iwakura et al demonstrated the effectiveness of calcium phosphate cement impregnated with antibiotics in a case report where they were able to salvage the limb. In addition to delivering the antibiotics, the calcium phosphate cement is osteoconductive and therefore stimulates bone growth.[34, 36] In contrast to the PMMA beads, the calcium phosphate cement does not produce heat and therefore the antibiotic is not subjected to damage.[35, 37] These are relatively newer techniques, however, and there is limited data available to prove their efficacy.

CONCLUSION

In comparing the treatments for diabetic osteomyelitis, there is still no one method that is superior to another. In fact, one study attempting to directly compare antibiotic and conservative surgery shows no significant difference between the two.[12] If physicians opt for a conservative approach, their main option is antibiotics, which have had a good success rate as demonstrated in several studies.[6,7,23] Patients might push for antibiotics over a surgical approach in order to salvage their limb, one of the biggest concerns among diabetics.[12] In order to get the most success with antibitoics, a culture should be taken of the infected area in order to tailor the treatment around the specific organisms. [23, 25] Some physicians may use debridement in conjunction with antibitics, however that has shown to make no difference according to the study by Ulcay et al.[27] There are cases like life threatening infections or severe ischemia, where surgical intervention is a better option. Oliver et al demonstrated in his study that the amount of bone being resected did not affect the patient's LEFS, therefore a larger amount of bone can be resected in order to ensure complete erradication of the infection. Aside from these two main approaches, there are alternative approaches which include hyperbaric oxygen therapy which leads to a decreased amputation risk, the use of PMMA beads which allows medications to directly release into the area increasing its effectiveness[20] and use of sural flap.[3, 8] There is still a lot of research that needs to be done in this field, and because no study has proven superiority of one treatment to another, it would be best to take a team approach and consider all options while tailoring the treatment according to the needs of the patient.

AUTHORS' CONTRIBUTIONS

The authors equally contributed to the production of this article.

STATEMENT OF COMPETING INTERESTS

The authors declare that they have no competing interests associated with this article.

REFERENCES

1. Armstrong DG, Lavery LA, Vazquez JR, Nixon BP, Boulton AJ. How and why to surgically debride neuropathic diabetic foot wounds. J Am Podiatr Med Assoc 2002; 92:402–4.
2. Lipsky BA, Berendt AR, Cornia PB et al. Infectious Diseases Society of America clinical practice guideline for the diagnosis and treatment of diabetic foot infections. Clin Infect Dis, 2012;54:e132–e173.
3. Berendt AR, Peters EJ, Bakker K, et al. Diabetic foot osteomyelitis: a progress report on diagnosis and a systematic review of treatment. Diabetes Metab Res Rev 2008; 24(Suppl 1):S145–61.

4. Boulton, A. J. (2010). "Hyperbaric oxygen in the management of chronic diabetic foot ulcers." Curr Diab Rep 10(4): 255-256
5. Game FL, Jeffcoate WJ. Primarily non-surgical management of osteomyelitis of the foot in diabetes. Diabetologia 2008;51: 962–967
6. Embil JM, Rose G, Trepman E, et al. Oral antimicrobial therapy for diabetic foot osteomyelitis. Foot Ankle Int 2006; 27:771–9.
7. Embil JM. The management of diabetic foot osteomyelitis. The Dia- betic Foot 2000; 3:76–84.
8. Eneroth M, Larsson J, Apelqvist J. Deep foot infections in patients with diabetes and foot ulcer: an entity with different characteristics, treatments, and prognosis. J Diabetes Complications 1999; 13:254–63.
9. Gnatiadis, I. A., et al. (2010). "Surgical management of a diabetic calcaneal ulceration and osteomyelitis with a partial calcanectomy and a sural neurofasciocutaneous flap." Diabet Foot Ankle
10. Ha Van G, Siney H, Danan JP, Sachon C, Grimaldi A. Treatment of osteomyelitis in the diabetic foot. Contribution of conservative surgery. Diabetes Care 1996; 19:1257–60.
11. Jeffcoate WJ, Lipsky BA. Controversies in diagnosing and managing osteomyelitis of the foot in diabetes. Clin Infect Dis 2004; 39(Suppl 2):S115–22.
12. Jones V. Debridement of diabetic foot lesions. The Diabetic Foot
1998; 1:88–94.
13. Lazaro-Martinez, J. L., et al. (2014). "Antibiotics versus conservative surgery for treating diabetic foot osteomyelitis: a randomized comparative trial." Diabetes Care 37(3): 789-795
14. Lipsky, B. A., A. R. Berendt, P. B. Cornia, J. C. Pile, E. J. G. Peters, D. G. Armstrong, H. G. Deery, J. M. Embil, W. S. Joseph, A. W. Karchmer, M. S. Pinzur, and E. Senneville. "2012 Infectious Diseases Society of America Clinical Practice Guideline for the Diagnosis and Treatment of Diabetic Foot Infections." *Clinical Infectious Diseases* 54.12 (2012): 1-42. Web
15. Lipsky BA. Evidence-based antibiotic therapy of diabetic foot infec- tions. FEMS Immunol Med Microbiol 1999; 26:267–76
16. Lipsky BA, Peters EJ, Senneville E, et al. Expert opinion on the management of infections in the diabetic foot. Diabetes Metab Res Rev 2012;28(Suppl. 1):163– 178
17. Lipsky BA. Osteomyelitis of the foot in diabetic patients. Clin Infect Dis 1997; 25:1318–26.
18. Mader JT, Ortiz M, Calhoun JH. Update on the diagnosis and man-
agement of osteomyelitis. Clin Podiatr Med Surg 1996; 13:701–24.
19. No authors listed. Consensus Development Conference on Diabetic Foot Wound Care: 7–8 April 1999, Boston, Massachusetts. American Diabetes Association. Diabetes Care 1999; 22:1354–60.
20. Oliver, N. G., et al. (2015). "Lower extremity function following partial calcanectomy in high-risk limb salvage patients." J Diabetes Res **2015**: 432164.
21. Panagopoulos, P., et al. (2015). "Local antibiotic delivery systems in diabetic foot osteomyelitis: time for one step beyond?" Int J Low Extrem Wounds 14(1): 87-91
22. Pinzur MS, Sage R, Abraham M, Osterman H. Limb salvage in in- fected lower extremity gangrene. Foot Ankle 1988; 8:212–5.
23. Scher KS, Steele FJ. The septic foot in patients with diabetes. Surgery 1988; 104:661–6.
24. Senneville E, Lombart A, Beltrand E, et al. Outcome of diabetic foot osteomyelitis treated nonsurgically: a retrospective cohort study. Diabetes Care 2008; 31:637–42.
25. Smith J. Is debridement effective for diabetic foot ulcer? A systematic review: 1. The Diabetic Foot 2001
26. Tan JS, Friedman NM, Hazelton-Miller C, Flanagan JP, File TM Jr. Can aggressive treatment of diabetic foot infections reduce the need for above-ankle amputation? Clin Infect Dis 1996; 23:286–91.
27. Tone, A., et al. (2015). "Six-week versus twelve-week antibiotic therapy for

nonsurgically treated diabetic foot osteomyelitis: a multicenter open-label controlled randomized study." Diabetes Care 38(2): 302-307
28. Ulcay, A., et al. (2014). "Antibiotherapy with and without bone debridement in diabetic foot osteomyelitis: A retrospective cohort study." Pak J Med Sci 30(1): 28-31.
29. Vardakas KZ, Horianopoulou M, Falagas ME. Factors associated
with treatment failure in patients with diabetic foot infections: an analysis of data from randomized controlled trials. Diabetes Res Clin Pract 2008; 80:344–51.
30. Newman LG, Waller J, Palestro CJ, Schwartz M, Klein MJ, Hermann G, et al. Unsuspected osteomyelitis in diabetic foot
ulcers. Diagnosis and monitoring by leukocyte scanning with indium in 111 oxyquinoline. JAMA 1991;266:1246–51.
31. Urabe K, Naruse K, Hattori H, Hirano M, Uchida K, Onuma K, et al. In vitro comparison of elution characteristics of
vancomycin from calcium phosphate cement and polymethylmethacrylate. J Orthop Sci 2009;14:784–93.
32. Sasaki T, Ishibashi Y, Katano H, Nagumo A, Toh S. In vitro elution of vancomycin from calcium phosphate cement. J Arthroplasty 2005;20:1055–9.
33. Nelson CL, Hickmon SG, Harrison BH. Elution characteristics of gentamicin-PMMA beads after implantation in humans.
Orthopedics 1994;17:415–6.
34. Sasaki S, Ishii Y. Apatite cement containing antibiotics: efficacy in treating experimental osteomyelitis. J Orthop Sci
1999;4:361–9.
35. Takashi Iwakura, Sang Yang Lee, Takahiro Niikura, Masahiko Miwa, Yoshitada Sakai, Kotaro Nishida, Ryosuke Kuroda, Masahiro Kurosaka. Gentamycin-impregnated calcium phosphate cement for calcaneal osteomyelitis: a case report. Journal of Orthopaedic Surgery 2014;22(3): 437-9
36. Kurashina K, Kurita H, Kotani A, Takeuchi H, Hirano M. In vivo study of a calcium phosphate cement consisting of alpha-tricalcium phosphate/dicalcium phosphate dibasic/tetracalcium phosphate monoxide. Biomaterials 1997;18:147–51.
37. Niikura T, Tsujimoto K, Yoshiya S, Tadokoro K, Kurosaka M, Shiba R. Vancomycin-impregnated calcium phosphate cement for methicillin-resistant Staphylococcus aureus femoral osteomyelitis. Orthopedics 2007;30:320–1.
38. Ioannis I., Vassiliki T., Dimitrios A., Georgakopoulos G., Gerostathopoulos N., Polyzois V. Surgical management of a diabetic calcaneal ulceration and osteomyelitis with a partical calcanectomy and a sural neurofasciocutaneous flap. Diabetic Foot & Ankle 2010; 1-4.

The Efficacy of Maggot Debridement Therapy on Diabetic Foot Ulcers and Its Further Applications

Gabrielle Lee, BA, Paulina Piekarska, BS, and Michael Sayad, BS

Abstract

Introduction
The purpose of the study is to evaluate the efficacy and limitations of maggot debridement therapy (MDT) for diabetic foot ulcers, assessing the degree of debridement, antimicrobial activities of maggots, and the extent of wound healing. This literature review further investigates MDT as an effective debridement method for pressure, traumatic, ischemic, and venous ulcers.

Study design: Qualitative Systematic Review of the Literature

Methods
An English language literature review was conducted using PubMed and ScienceDirect databases. The exclusion criteria consisted of history of prior conventional surgeries, such as incision, drainage, surgical debridement, and amputation, for diabetic wounds and complications from treatments other than MDT. Inclusion criteria included patients on maggot debridement therapy for diabetic, pressure, traumatic, ischemic, or venous foot ulcers.

Results
Maggot debridement therapy was more efficient than conventional methods particularly when compared to negative-pressure wound dressing, which exacerbated necrosis of the tissue due to insufficient arterial flow. Full-debridement, which is defined as enhanced granulation tissue formation and complete elimination of necrotic tissues, was accomplished with maggot therapy without requiring follow-up conventional surgeries.

Conclusion
Maggot therapy is a safe and effective wound debridement method in diabetic patients. Beneficial effects include wound healing via secretion of antimicrobial proteins and stimulation of cell proliferation. As a cost-effective treatment, future studies propose utilization of the therapy for chronic wounds other than those of diabetic origin. Further research as well as doctor and patient education on maggot debridement therapy is necessary to discover the full benefits of larval-based treatment methodologies.

Key Words: Maggot debridement therapy, diabetic foot ulcers, venous stasis ulcers, *L. sericata,* conventional debridement surgeries

Level of Evidence: 5

INTRODUCTION

Medical Maggots

Maggot debridement therapy (MDT), also known as biosurgery, is a type of biotherapy that uses sterile larvae for wound debridement. The larvae of *Lucilia sericata* (green bottle fly) are the most commonly utilized species as they are one of the few that feast solely on necrotic tissue. Medicinal larvae are utilized for their ability to consume necrotic tissue leaving healthy granulation tissue behind. This process is known as extracorporeal digestion in which the maggots secrete a broad spectrum of proteolytic enzymes. These enzymes, also known as alimentary secretions and excretions (ASE), liquefy target tissue making it easier for maggot imbibement. The physical crawling movement of the maggot over the wound spread the ASE and significantly contributes to debridement efficacy.[18] These ASEs include matrix metalloproteinases (MMPs), trypsin, collagenase, and chymotrypsin.[18]

Sterilization techniques are used to wash fly eggs to ensure that they are bacteria free upon hatching.[1] *L. sericata* is first exposed to a piece of beef liver followed by oviposited eggs, which are transferred from the piece of beef liver into sterile 0.5 % sodium sulfite.[2] The eggs are then immediately sterilized and rinsed with sterile distilled water and incubated on blood agar plates.[2] This procedure results in sterile freshly hatched larvae.[2]

The benefits to MDT include disinfection, promotion of wound healing and promotion of wound closure via production of biologically active molecules, such as deoxyribonuclease (DNAse) that degrades microbial DNA, and inhibits microbial growth and biofilm formation [3,4] In addition, defensins are thought to be important in that they not only stimulate direct antimicrobial immunity but also promote wound healing by cytokine regulation and enhanced phagocytosis.[19]
While the positive effects of MDT have been noted in war wounds since the 1600's, it was not until the early 1900's that maggot experiments were conducted in a clinical context.[5] In the 1940's, MDT lost favor after the emergence of penicillin and other antibiotics. Today, maggot therapy is once again being recognized as an effective and cost-efficient form of wound management or adjunct treatment, especially with the increased prevalence of diabetes as well as the increasing number of antibiotic resistant strains of bacteria.[5]

Diabetes and Diabetic Foot Ulcers

Currently, there are 387 million people worldwide living with diabetes including 39 million in the United States alone.[6] Diabetic patients are at an increased risk of coronary artery disease, retinopathy, nephropathy, and amputations. Somatic neuropathy, amyotrophy, and the macrovascular and microvascular complications common in diabetics predispose these patients to foot ulcer development and even lower limb loss. Foot problems are the most common cause of hospitalization in diabetics.[7] Medical expenditures are 2.3 times higher in diabetic patients as compared to non-diabetic patients with a reported average yearly cost of $245 billion in 2012 in the US alone.[8]

Foot ulcer formation occurs due to a combination of loss of pain and pressure sensation, muscular weakness, and impaired immune system function. Somatic neuropathy inhibits patients from detecting noxious stimuli, which normally serve to make the patients aware of a problem.[7] Distal muscle weakness hinders the patient's ability to make gait adjustments in response to factors affecting the foot. Amyotrophy also renders the patient susceptible to biomechanical changes in the lower extremity that can further precipitate pressure sore formation.[7] The effects of hyperglycemia are

systemic resulting in suboptimal immune function which predisposes the diabetic patient to chronic infection.[9] Furthermore, with the increased emergence of antibiotic-resistant bacteria, diabetics with chronic ulcers are at an increased risk for infection with these hard-to-treat organisms as well as biofilm formation.[9]

Debridement is the first step in diabetic foot ulcer closure. It may be a short-term or long-term process that is based upon removal of necrotic tissue and healing. There are multiple options when it comes to wound debridement with surgical debridement being the current gold standard.[10] However, the drawbacks of conventional sharp surgical debridement are that it is radical, aggressive, and non-selective which may cause further necrosis of healthy tissue particularly at the wound edges. It also requires pain management post-operatively. Sharp debridement is also contraindicated for patients with peripheral vascular disease due to risk of further damaging already poorly vascularized tissues.[10]

In addition to conventional surgical debridement, there are autolytic, mechanical, and enzymatic methods that can be used in diabetics. Autolytic debridement utilizes the body's own lysosomal enzymes that degrade necrotic tissues.[10] It requires specific dressings that keep the wound area moist as moisture softens the tissue and promotes contact between the enzymes and necrotic flesh. The biggest limitation of this process is that it is slow and excess moisture can cause tissue maceration.[10,11] Mechanical debridement exists in multiple forms such as hydrosurgery, which is removal of tissue using a high-powered water jet and ultrasonic surgery, which works by cavitation—small bubbles that fragment target tissue.[12]

Mechanical debridement carries the same impediment as sharp debridement – it can inadvertently damage healthy tissue. Enzymatic debridement utilizes exogenously acquired concentrated forms of tissue degrading enzymes. This approach works faster than autolytic debridement but if applied incorrectly it can target healthy tissue and even cause discomfort to the patient.[13] Additionally, prescription for the necessary enzymes may become costly to the patient.[13]

MDT for diabetic foot ulcers

Maggot Debridement therapy (MDT) is a form of therapy in which medical maggots are introduced into non-healing wounds for the purpose of cleaning out tissue that is no longer viable. While this type of biotherapy is utilized worldwide, it still remains an underused and under-studied modality in wound care practices.[14,15] There is evidence supporting the use of MDT on Diabetic foot ulcers (DFU) in that maggots promote effective debridement by consuming necrotic tissues, produce antimicrobial enzymes to eliminate bacteria, and stimulate wound healing via granulation tissue formation.[15,16,17]

The purpose of this review is to analyze the current medical literature on MDT for treatment of diabetic foot ulcers as well as for pressure, traumatic, ischemic, and venous foot ulcers. This study focuses on larval enzyme secretions, available dressings, and optimal habitat for maggot activity in an effort to evaluate MDT as an effective debridement method. This review will provide evidence on the long-term use of MDT and address limitations.

METHODS

Two searches of the primary literature were performed on PubMed and ScienceDirect databases. The initial search utilized the Boolean operator "AND" for the terms "Maggot Debridement Therapy" AND "Diabetic Foot Ulcers." This first search yielded 46 articles on PubMed. The exclusion criteria consisted of prior conventional surgeries for diabetic wounds and other

complications from treatments other than MDT. Inclusion criteria for this first search included patients on MDT for diabetic foot ulcers without conventional surgeries and English written papers only. According to these exclusion/inclusion criteria, 9 out of 46 articles were excluded. Using the same protocol, a search was performed in the ScienceDirect database resulting in 115 articles, of which 37 articles met the inclusion criteria.

The second search employed the Boolean operators "and" and "not" for the terms "Maggot Debridement Therapy" AND "Ulcers" AND "Foot" NOT "Diabetic". The same exclusion criteria were applied for this search, and the inclusion criteria included patients with pressure, traumatic, ischemic, or venous ulcers. PubMed resulted 6 articles, which were all used for the systemic review. A ScienceDirect search yielded 227 articles, 18 of which satisfied the search intention of maggot debridement therapy for ulcers other than those of diabetic origin and were utilized for analysis.

RESULTS

DeFazio et al. created a simple, cost-effective, and closed-system habitat for the larvae *Phaenicia sericata* to treat drug-resistant, chronically infected complex distal lower extremity wounds.[25] The authors found enhanced healing through selective debridement of necrotic tissues, improved rate and efficiency of chronic wound healing, lengthened antibiotic-free intervals, and lowered amputation risks with diabetic foot ulcers.[25]

Helena Hilková et al. performed an 18-month MDT experiment on patients who were indicated for minor or major amputation of the limb due to diabetic, ischemic, traumatic, and venous wounds.[22] This experiment used *L. sericata* as the main larval type and the maggots were contained in a nylon bag that was applied on the ulcers. The study specifically examined survival, length, width, and larval instar, which was between successive molts and not yet sexually mature, of the maggots within each bag. Fifty-two bags were analyzed for 48 to 72 hours across all four types of ulcers. As a result, there were no significant differences in larval survival between the four wound types but the length and width of the maggots were significantly different. Larvae from venous ulcers were shorter (7.09mm) and thinner (1.77mm) than in traumatic, ischemic, or diabetic ulcers (the average 9.06mm long and 2.19mm wide). There were no statistically significant differences in larval survival, however, the survival rate in venous ulcers was on average 19% lower than other ulcers. [22]

Marineau et al. conducted a study on treatment of complex diabetic wounds reporting complete debridement, granulation tissue formation, and partial wound closure with MDT in 17/23 (74%) of patients. In the study, 6 of the patients were able to form granulation tissue over exposed tendons allowing them to avoid surgical removal.[29] One patient with multiple venous stasis ulcers secondary to lymphedema experienced 75% resolution within 10 days of treatment initiation. A diabetic patient with peripheral neuropathy experienced increased sensation post-MDT.

A meta-analysis conducted by Tian et al., reported that MDT was significantly more successful than other wound therapy modalities in terms of the degree of healing, time to full healing, amputation rate, as well as the number of antibiotic free days.[30] According to this analysis, there was no significant difference in infection recurrence between MDT and control.

Campbell and Campbell conducted a retrospective quality review reporting that 67/68 patients of a foot and leg ulcer clinic achieved over 90% of wound debridement with MDT.[31] After successful debridement,

Study Author(s)	# of Subjects	Duration of Treatment	Effectiveness	Species	Wound type	Notes
DeFazio et al.	1 (case study)	48-72 hours	(QUALITATIVE) Enhanced healing through selective debridement of necrotic tissues, improved rate and efficiency of chronic wound healing, lengthened antibiotic-free intervals, and lowered amputation risks with diabetic foot ulcers	*Phaenicia sericata*	Drug-resistant, chronically infected complex distal lower extremity wounds	Cost-effective, and closed-system habitat
Helena Hilková et al	52	48-72 hours for 18-month MDT	No significant differences in larval survival between the four wound types but the length and width of the maggots were significantly different= Larvae from venous ulcers were shorter (7.09mm) and thinner (1.77mm) than in traumatic, ischemic, or diabetic ulcers (the average 9.06mm long and 2.19mm wide) survival rate in venous ulcers was on average 19% lower than other ulcers.	*Lucilla sericata*	Diabetic, ischemic, traumatic, venous wounds	Specifically examined survival, length, width, and larval instar of the maggots within each bag
Marineau et al.	23	Variable	74% complete debridement, granulation tissue formation, and partial wound closure with MDT	*Lucilla sericata*	Complex diabetic wounds	1 diabetic patient with peripheral neuropathy reported increased sensation post-MDT
Tian et al.	Meta-analysis	Variable	Positive significant difference in degree of wound healing, time to full healing, amputation rate, and antibiotic free days		Diabetic foot ulcers	

Table 1. Summary of Maggot Debridements

Study Author(s)	# of Subjects	Duration of Treatment	Effectiveness	Species	Wound type	Notes
Campbell N, Campbell D.	68	Variable	90% debridement in 67/68 patients in 2-10 days Wound closure in 85% 15% needed additional surgery for wound closure	*Lucilla sericata*	Leg and foot ulcers	Use of MDT resulted in a 67% drop in cost for foot and ulcer care per week
Pinheiro et al.	1	43 days	Ulcer retraction from 8.4cm^2 to 0.7cm^2 Reduction of necrosis Granulation tissue on the ulcer surface Acceleration of wound healing Elimination of antibiotic resistant *E. coli, K. pneumoniae, P. aeruginosa*	*Chrysomya megacephala*	Diabetic foot ulcer	74 year old diabetic patient
Opletalova et al.	119	15 days	More slough production compared to control at week 1 and 2 Faster rate of debridement compared to control at week 1 and 2 Shorter treatment period was required for patients utilizing MDT	*Lucilla sericata*	Non-healing, sloughy wound 40cm^2 or smaller, less than 2cm deep	

Table 2. Summary of Maggot Debridements

wound closure was achieved in 86% of patients via moist wound dressings while 15% underwent surgery to achieve closure. In the week before MDT, nursing cost for foot and ulcer care amounted to $46,050. This dropped by 67% one-week post-MDT, to a total of $15,300.

Pinheiro et al. published a case study of a 74-year-old female diabetic patient who underwent 43 days of MDT. The study reported reduction of necrosis, ulcer retraction of 0.7cm^2 from the original 8.4cm^2, granulation tissue on the ulcer surface, and acceleration of wound healing.[23] MDT was successful in eliminating antibiotic resistant bacteria, specifically *E. coli, K. pneumoniae, and P. aeruginosa* that were previously present in the wound bed.

Opletalova and colleagues conducted a randomized multicenter trial of 119 patients and reported that MDT produced more slough and provided a significantly faster rate

Study Author(s)	# of Subjects	Duration of Treatment	Effectiveness	Species	Wound type
Sun et al.	Meta-analysis	Meta-analysis	Significantly longer period of antibiotic free days post treatment in patients treated with MDT No difference in infection rate between MDT and control Decreased risk of amputation for patients receiving MDT Healing time was significantly shorter with MDT MDT was more cost-effective than conventional therapy	Variable	Variable
Paul et al.	29	Variable	There was no significant difference in outcome between MDT and conventional therapy Patients undergoing MDT therapy showed a significant difference in length of ward sstay	*Lucilla cuprina*	Diabetic foot ulcers
Gileal et al	435	1-240 months (mean=8.9; median=4 months)	357 patients (82.1%) complete debridement of the wound; 73 patients (16.8%) partial debridement; 5 (1.1%) ineffective	*Lucilla sericata*	Diabetic foot ulcers

Table 3. Summary of Maggot Debridements

of debridement as compared to the control in week 1 and 2, respectively.[32] However, these differences disappeared by day 30. Treatment was longer in patients undergoing conventional therapy (40.1 minutes measured at days 1, 8 and 15) as compared to patients undergoing MDT (10.1 minutes measured at days 1, 8, 15). This difference was attributed to the administration of analgesia and sharp debridement that performed in the control group.

A systematic review conducted by Sun and colleagues reported that MDT shortened overall healing time and improved healing rate of chronic ulcers.[3] The authors found no difference in infection rate when comparing MDT to the control but did find that patients undergoing MDT experienced more antibiotic free days. The MDT group experienced a decreased risk of amputation. Treatment cost of one month of MDT was reported at $140.57 as compared to one month of hydrogel therapy (a form of autolytic debridement), which ranged from $732-1022. Paul et al. performed an 18-month-study to assess the effectiveness of maggot debridement therapy (MDT) with the sterile larvae of *Lucilia cuprina* for the treatment of diabetic foot ulcers.[33] This study compared diabetic foot ulcers treated with maggot debridement therapy to those treated with a conventional debridement therapy alone. Twenty-nine patients were treated with MDT and 30 patients were in a control group. Of the 29 patients who received MDT, 14

wounds were healed; in the control group, 18 wounds out of 30 were healed with conventional therapy. This study did not show a statistically significant difference between MDT and conventional debridement therapy for diabetic foot ulcers indicating that MDT is equally effective at DFU debridement when compared to the current standard of treatment. MDT was considered a great alternative to those patients at high risk for surgery as well as a more cost-effective tool.

Gileal et al. conducted a 13-year-study on the efficacy of medicinal maggots for the debridement of chronic wounds. This study assessed 723 wounds treated with maggot debridement therapy in ambulatory and hospitalized patients; 261 patients were treated during hospitalization, while 174 were treated as ambulatory patients.[34] Sterile *L. sericata* maggots were used in all cases. Both open and closed system techniques of MDT were used throughout the course of treatments. They found that 82% of patients showed complete debridement, while 17% showed partial debridement. In 1% of patients debridement was ineffective. The study concluded MDT to be "a very safe, simple and effective treatment modality for chronic wounds."[34]

DISCUSSION

Effectiveness

Sherman et al.[18] proposed MDT to be safer than the conventional surgical treatments in that it only debrided necrotic tissues and did not invade healthy tissues that the existing surgical treatments sometimes disturbed.[18] Invasion of living tissue can be associated with pain and discomfort requiring analgesia which can potentially increase cost. [32] This could also aggravate current symptoms and eventually lead the patients to develop further vascular and neuropathic problems. Maggot therapy allows new tissue to proliferate and differentiate without additional insult to the area. As many diabetic patients have an impaired immune system and healing processes, allowing granulation tissue to proliferate undisturbed may be an important factor as the studies in this review mentioned.

Nigam et al.[19] showed that the *Dipteran* species in particular exhibited disinfecting properties attributed to production of antimicrobial molecules that killed ingested microbes within their guts. The antimicrobial molecules defensin, diptericin, and other AMPs helped reduce inflammation and promote wound healing. In addition, certain types of maggots such as *Phaenicia/Lucilia sericata* excreted a waste product of their own metabolism that combated bacterial infections by altering the wound pH—making it more alkaline and unfavorable to many bacterial species.[19] *P. sericata* also carried in their midgut a commensal: *Proteus mirabilis*, which produced antibacterial agents: phenylacetic acid (PAA) and phenylacetaldehyde (PAL).

Igari et al.[20] examined the stimulation of granulation tissue formation. In a chronic wound, there is an over-expression of fibrin (ECM component) thus inhibiting the normal wound healing process. Maggots applied to the chronic wound reversed inhibition of normal wound healing and enhanced tissue oxygenation in the wound bed via the mechanical stimulation of their crawling.[20] Furthermore, Horobin et al.[21] found that ammonia produced by certain types of maggots not only altered the pH of the environment but also stimulated growth of local granulation tissue. Ammonia was thought to be most effective in purulent wounds and indolent neuropathic ulcers, which were characteristics of DFU and other chronic ulcers.

Hilková et al.[22] study reported that trypsin-like enzyme, proteinases, secreted by maggots played an important role in protease activated receptor-mediated activation of proliferation or cytokine secretion in a wound.

These proteinases lysed fibrin/ECM that was the main hindrance in the healing of chronic wound. When the fibrin was lysed, the fibronectin fragments were released and they enhanced healing processes.[22] These enzymes specifically altered the integrity of protein surface of fibronectin, causing the release of small peptides that modulated fibroblast motility.[22] Maggots were especially important in this process because they allowed fibroblasts to be more attracted to the altered protein surfaces of fibronectin and since higher number of fibroblasts were recruited to the wound areas at a faster rate, it accelerated the entire wound healing process.[22]

DeFazio et al.[25] specifically focused on closed-system habitat for maggots found MDT enhanced healing through selective debridement of necrotic tissues, improved rate and efficiency of chronic wound healing, lengthened antibiotic-free intervals, and lowered amputation risks with diabetic foot ulcers. Most importantly, the study suggested the use of MDT in geometrically complex locations such as in between the toes where conventional surgeries experienced hardships in complete debridement. Maggots were permitted for unrestricted migration inside the well-ventilated/oxygenated closed-system, which was adaptable to complex wound geometries. The closed-system that the authors designed compensated the limitations of existing MDT use. The limitations included the prospect of maggot escape, failure to control maggot secretions and associated anxiety among patients, and the use of labor-intensive dressings. The closed-system prevented mechanical crush of maggots, ensured secure containment of maggots, and facilitated free-range debridement with low-cost and readily available materials, such as biohazard bag, disposable cup, chiffon netting, elastic band, and perforated tape. This closed-system controlled the secretion and pooling/overflow of the fluids with an internal collection chamber, which was lined with multiple layers of superabsorbent gauze. Because this internal collection chamber efficiently managed secretions, it minimized skin irritation or discomfort from unregulated fluid collection. Since maggots were introduced through a physically confined ventilation port directly overlying the wound that was subsequently sealed with polyester chiffon netting, the existing problems with maggot escape were resolved[25]. The fact that the biohazard bag was opaque maximized patient comfort.[25]

Gottrup et al. evaluated the ability of medical maggots to debride wounds that were located in surgically unapproachable areas. Far too often surgeons were limited in how well they could debride a wound purely based off the location of the wound. While medical maggots had both mechanical and biochemical means of debridement, the mechanical means directly competed with the surgeons' skill. "Mechanical debridement was done by the specific mandibles or 'mouth hooks' of the maggots and their rough bodies which both scratched the necrotic tissue."[24] These mouth hooks allowed for greater precision than surgical debridement due to ulcer size and location.

MDT for other ulcer types

The FDA has approved the use of MDT for the debridement of non-healing necrotic skin and soft tissue wounds, such as pressure ulcers, venous stasis ulcers, and non-healing traumatic or post-surgical wounds.[28] For these ulcers, "Biobags", a patented ravioli-like pouch containing the live larvae, hydrogel, and compression dressings are commonly utilized.[25]

Hilková et al. studied MDT for other types of ulcers, such as pressure, traumatic, and ischemic ulcers, yielding similar results as when applied to diabetic ulcers. Debridement rates, production of antimicrobial enzymes, and wound healing processes showed no statistically significant differences. However,

Fig.1.0 *Biobag maggot dressing application*
This figure shows a Biobag that contains maggots that are applied to an open wound.
*Reprinted with permission from *Medical Corps--International forum,* 2015

for venous ulcers, many studies presented varying results and explanations. The experiments by Hilková et al. showed thinner and shorter larvae in venous ulcers compared to other types of ulcers. In addition, the larvae in venous ulcers did not grow as quickly as the ones in diabetic, traumatic, or ischemic ulcers and the survival rate was lower. These results initially suggested that MDT was less effective in venous ulcers. However, further experiments by Hilková et al. showed that venous ulcers had less necrotic tissue and nutrients, effectively reducing the maggot life cycle. This was why maggots on venous ulcers died sooner than on other ulcers. In addition, when larvae were removed, venous ulcers were visually well debrided and only one cycle of MDT was enough to remove all the necrotic tissues. The previous notions of MDT's limited effectiveness in venous stasis ulcers did not hold true in this study as it showed complete debridement in less time therefore suggesting that MDT for venous ulcers may be equally as effective as when applied to other ulcer types. The researchers suggested that medications in the patient group with venous ulcers might have influenced their findings.[22]

Cost-effectiveness

Wayman et al.[24] assessed the cost of treating venous leg ulcers with MDT as compared to hydrogel therapy. The study was able to show that the cost per patient was almost doubled when using hydrogel compared to MDT. In addition, the cost of treating the patient over the lifetime of the wound was significantly less with MDT and it was

Fig. 1.1 *Hydrogel application in an open wound*
This figure shows a use of a hydrogel in a gel form applied to an open wound.
*Reprinted with permission from *Medical Corps--International forum,* 2015

calculated that upwards towards $50 million could be saved annually.[24] It was suggested that the savings associated with MDT were due to the fact that fewer visits were required to achieve complete debridement.[24]

Open and Closed systems

MDT can be conducted in open and closed systems depending on the degree and types of ulcers. Open system MDT refers to the application of freely crawling maggots to the wound that are then lightly dressed to keep them in place and allow them to breathe. Generally, the maggots are placed on nylon net which covers the wound, which is then covered by a gauze bandage and not a bio bag, as in the closed system MDT. Normally, 5-10 maggots are applied per cm^2 necrotic tissues for 3-4 days. After the period of debridement, the maggots are removed and the wound is washed with saline.[24] Open system MDT will restrict the migration of maggots and is therefore indicated for smaller, more regular shape wounds.

Closed system is used when there are multiple distal lower extremity ulcers because these systems facilitate free-range debridement in the foot.[25] The entire distal lower extremity is enclosed in the closed-system habitat allowing the maggots to freely roam over all target areas.[25] When the ulcers exist in geometrically complex locations, such as interdigital spaces, or large and irregular wound surfaces in the joints and toes, the closed system is preferred because it permits unrestricted migration of maggots from one

Fig. 1.2 *Closed system for distal lower extremity*
*Reprinted with permission from *American Society of Plastic Surgeons*, 2015

ulcer to another. This more effectively clears necrotic tissues and also provides a lower-maintenance environment than in an open system.[25] In addition, the closed system is commonly utilized when the debridement process results in massive fluid production. The internal collection chamber is lined with multiple layers of superabsorbent gauze that prevent pooling and leakage of fluids, which may irritate the skin and cause discomfort to the patients.[25] The closed system is also preferred for certain patients who mount high anxiety level to maggot visibility since the bags that cover the ulcer sites are dark and opaque.[25]

The closed-system habitat is for multiple necrotic ulcers in the dorsal/plantar surfaces of the foot and interstices of the web spaces. The extremity is placed through the opening of a medium size, recyclable biohazard bag, which is tapered in the longitudinal

dimensions as shown above. Maggots are introduced through the ventilation port, which is sealed with polyester chiffon netting. This polyester chiffon netting is a prevalent dressing and also ensures continuous oxygen supply. The internal surfaces of the chamber are lined with multiple gauzes that absorb excessive fluids. Perforated cloth tape firmly seals and maintains the shape of the chamber. Patients undergo this closed-system process for 48-72 hours.

Long-term use of MDT

Larvae are known to have antibacterial effects whether in the form of peptide secretion or necrotic tissue digestion and therefore dilution of bacterial concentration in the wound bed.[35] Studies suggest that larval secretions have a multitude of other activities, some of which are anti-inflammatory.[36] Larval salivary gland extracts have been found to decrease activity of superoxide and myeloperoxidase.[36] Larval secretions have also been shown to affect immune cell differentiation, limiting their progress into inflammatory macrophages and promoting differentiation in pro-angiogenic macrophages.[37] Some studies have shown that maggot ASE stimulates fibroblast migration and angiogenesis leading to more rapid wound closure.[36]

While the status of foot ulcer healing depends on multiple factors such as immune status, diabetes control, and vascular compromise, rate of further foot ulcer development has been reported as high as 70%.[38] It is important to consider that the multitude of benefits of MDT are likely to only be occurring while the larvae are in the wound bed; when debridement is complete and larvae are removed, their secretions are removed with them. While clean of necrotic tissue and disinfected, the wound is still open and exposed. Re-infection and biofilm formation are likely possibilities.[36] One of the many important considerations should be the incorporation of long-term use MDT or maintenance debridement. This will not only ensure presence of larval antimicrobial peptides in the wound bed but will prolong the angiogenic and inflammatory suppressive effects as well.

Limitations and Considerations

Commonly mentioned limitations include pain in the wound bed, psychological aversion, and maggots escaping from dressings.[39] It is important to note that 100% of patients who complained of pain when undergoing MDT had pain before the treatment. Maggots grow rapidly as they feast on necrotic tissue. As they grow, their enlarged presence may be stimulating exposed nerve endings.[39] This side effect can be avoided via administration of analgesics, using fewer maggots, changing dressings more frequently to ensure removal of growing maggots with replacement of smaller ones, and if necessary – removal of maggots entirely.[31]

Patient anxiety is largely based around the fear of sensation of maggots crawling over skin. Education is key to decreasing patient discomfort. Informed consent should provide the patient with necessary information on how maggots work, the advantages of MDT, what to expect, as well as contact information – allowing the patient access to medical personnel 24/7 should any discomfort arise.[31] Physician education is also necessary as some of these fears may be shared. MDT is not always an option offered to patient simply due to unfamiliarity of medical personnel with the benefits and application of larval dressings.[40]

Proper application of larval dressings is crucial in preventing maggot escape, which can be a nuisance and can discourage the patient from further participation. Properly placed dressings also ensure that liquefied necrotic debris mixed with larval secretions will not come in contact with the periwound area which can prevent any unnecessary irritation to healthy tissue.[40] There are many different dressings available and for tissue areas that pose difficulty in bandage

Fig. 1.3 *Closed system for proximal lower extremity*
This is another example of a closed-system showing more proximal lower extremity.
*Reprinted with permission from *American Society of Plastic Surgeons,* 2015

application: it is possible to make your own dressing. Larval dressings have component parts that serve specific purposes: netting or mesh to keep the maggots confined to one specific area, an area which allows oxygen in, and a means for collecting waste.[40] This is a confinement dressing that allows the maggots full access to the wound bed. There are also containment dressings designed specifically to keep maggots in pouch-like dressings making it impossible for them to leave the area. Some studies have suggested that maggots contained within a dressing show slower debridement possibly due to a lack of the mechanical properties of maggots freely crawling over the tissue but also because they are unable to fully access the tighter wound spaces.[36]

Eschars and calluses pose a problem as maggots are unable to debride such tough, hard tissue. In these instances debridement is either impossible or slower. These more impenetrable areas need to be removed via other means such as sharp debridement or autolytic dressing before beginning MDT.[40]

While maggots have the ability to ingest and kill bacteria within their gut, some bacteria can be deadly to them. MDT is highly recommended for wounds infected with Gram-positive bacteria, such as *Staphylococcus aureus* and it is considered less effective for wounds infected with Gram-negative bacteria, such as *Escherichia coli, Klebsiella pneumoniae,* and *Pseudomonas aeruginosa.*[23] *P. aeruginosa* species is particularly toxic to maggots because of its ability to produce biofilm and participate in quorum sensing.

CONCLUSIONS

Evidence continues to build in-support of MDT but these studies are rarely RCT's. Maggot therapy has often been considered a last resort of wound debridement. Sharp debridement is the current first line treatment.

This review aims to consolidate some of the many published studies, which show that MDT is an effective method of wound management particularly in diabetic patients where infection and inflammation can induce devastating consequences. Smaller studies and case reports continue to point in support of MDT in terms of its antibacterial properties particularly against multiple-antibiotic resistant strains as well as the ability to stimulate tissue healing and promote wound closure. Maggot therapy is not restricted by locations, as are many of the conventional methods of wound therapy. Larvae can enter complex areas like the interdigital spaces to treat otherwise complicated wounds. Apart from their ability to debride necrotic tissue while preserving new healthy cell layers, maggots also produce a variety of secretions, which are anti-microbial in action and have been reported to work against some antibiotic resistant species. Larger scale standardized studies are necessary to produce concrete and statistically significant proof of MDT benefits. In order to develop further support for MDT, these studies should also include patient education and cost differentiation as maggot therapy has often been cited as a more cost-effective option but actual cost savings have rarely been reported.

AUTHORS' CONTRIBUTIONS

The authors equally contributed to the production of this article.

STATEMENT OF COMPETING INTERESTS

The authors declare that they have no competing interests associated with this article.

REFERENCES

1. Hinshaw J. Larval Therapy: A Review of Clinical Human and Veterinary Studies. *World Wide Wounds* 2000.

2. Jaklic, D., Lapanje, A., Zupancic, K., Smrke, D., & Gunde-Cimerman, N. (2008). Selective antimicrobial activity of maggots against pathogenic bacteria. Journal of Medical Microbiology, 617-625.

3. Sun X, Jiang K, Chen J. A systematic review of maggot debridement therapy for chronically infected wounds and ulcers. *International Journal of Infectious Diseases* 2014:32–37.

4. Li P-N, Li H, Zhong L-X. Molecular events underlying maggot extract promoted rat in vivo and human in vitro skin wound healing. *Wound Repair and Regeneration Wound Repair Regen* 2015:65–73.

5. Maggot Debridement Therapy (MDT). *Department of Medical Entomology* 2010. Available at: http://medent.usyd.edu.au/projects/maggott.htm.

6. IDF Diabetes Atlas. *International Diabetes Foundation* 2014. Available at: https://www.idf.org/sites/default/files/atlas-poster-2014_en.pdf.

7. Porth C. Diabetes Mellitus and the Metabolic Syndrome. In: *Essentials Of Pathophysiology: Concepts of Altered Health States*. 2nd ed. Philadelphia: Lippincott Williams & Wilkins; 2007:699–723.

8. Statistics About Diabetes. *American Diabetes Association* 2014. Available at: http://www.diabetes.org/diabetes-basics/statistics/.

9. Alves C, Casqueiro J, Casqueiro J. Infections in patients with diabetes mellitus: A review of pathogenesis. *Indian Journal of Endocrinology and Metabolism Indian J Endocr Metab* 2012.

10. International Best Practice Guidelines: Wound Management in Diabetic Foot ulcers. *Wound International*. 2013. Available at: http://www.woundsinternational.com/media/issues/673/files/content_10803.pdf

11. Zacur H, Kirsner R. Debridement: Rationale and Therapeutic Options. *Wounds: a compendium of clinical research and practice* 2002;16(7). Available at: http://www.woundsresearch.com/article/1031.

12. Wendelken M, Markowitz L, Alvarez O. A Closer Look At Ultrasonic Debridement. *Podiatry Today* 2010;23(8). Available at: http://www.podiatrytoday.com/closer-look-ultrasonic-debridement.

13. Swezey L. Methods of Debridement. *Wound Source* 2015. Available at: http://www.woundsource.com/blog/methods-debridement.
14. Monarch labs. (n.d.). Medical Maggots™ (maggot therapy, maggot debridement therapy, MDT, biotherapy, biosurgery, biodebridement, larval therapy). Retrieved December 30, 2015, from http://www.monarchlabs.com/mdt
15. Altincicek, B. and Vilcinskas, A. (2009), Septic injury-inducible genes in medicinal maggots of the green blow fly Lucilia sericata. Insect Molecular Biology, 18: 119–125. doi: 10.1111/j.1365-2583.2008.00856.x
16. Society for General Microbiology. (2010, February 5). Bacteria toxic to wound-treating maggots. ScienceDaily. Retrieved December 29, 2015 from www.sciencedaily.com/releases/2010/02/100204204304.htm
17. Villet, M., & Bouwer, N. (2001). Healing wounds using maggots. Science in Africa.
18. Sherman, R. (2014). Mechanisms of Maggot-Induced Wound Healing: What Do We Know, and Where Do We Go from Here? *Evidence-Based Complementary and Alternative Medicine, 2014*(592419), 13-13. doi:10.1155/2014/592419
19. Nigam, Y., Bexfield, A., Thomas, S., & Ratcliffe, N. (2006). Maggot Therapy: The Science and Implication for CAM Part II—Maggots Combat Infection. *Advance Access Publication, 3*(3), 303-308. doi:10.1093/ecam/nel022
20. Igari K, Toyofuku T, Uchiyama H, Koizumi S, Yonekura K, Kudo T, Jibiki M, Sugano N, Inoue Y. Maggot Debridement Therapy for Peripheral Arterial Disease. *Annals of Vascular Diseases* 2013; 6(2): 145-149. Available at: http://www.ncbi.nlm.nih.gov/pmc/articles/PMC3692982/
21. Horobin AJ, Shakesheff KM, Woodrow S, Robinson C, Pritchard DI. Maggots and wound healing: an investigation of the effects of secretions from Lucilia sericata larvae upon interactions between human dermal fibroblasts and extracellular matrix components. Br J Dermatol 2003;148:923–33
22. Hilková H, Hambal M, Kozánek M, Takál P. Growth and Survival of Bagged Lucilia sericata Maggots in Wounds of Patients Undergoing Maggot Debridement Therapy. *Evidence-Based Complementary and Alternative Medicine* 2013; 1-7. doi: 10.1155/2013/192149
23. Pinheiro M, Ferraz J, Junior M, Moura A, da Costa M, Costa F, Neto V, Neto R, Gama R. Use of maggot therapy for treating a diabetic foot ulcer colonized by multidrug resistant bacteria in Brazil. *Indian Journal of Medical Research* 2015; 141(3): 340–342.
24. Gottrup, F., & Jørgensen, B. (2011). Maggot Debridement: An Alternative Method for Debridement. Eplasty, 11, e33
25. DeFazio M, Felder J, Economides J, Attinger C. Home Improvement in Maggot Therapy: Designing a Simple, Cost-Effective, Closed-System Habitat to Facilitate Biodébridement of Complex Distal Lower Extremity Wounds. *Plastic and Reconstructive Surgery* 2015; 722-723e.
26. Package Inserts. Monarch Labs - Living Medicine. Available at: http://www.monarchlabs.com/node/11.
27. Fleischmann W, Grassberger M, Sherman R. Clinical Applications of Maggots. In: Maggot Therapy: A Handbook Of Maggot-Assisted Wound Healing. Stuttgart: Thieme; 2004:34–36.
28. Sherman R. Maggot Therapy Takes Us Back to the Future of Wound Care: New and Improved Maggot Therapy for the 21st Century. *J Diabetes Sci Technol*. 2009 Mar; 3(2): 336–344.
29. Marineau ML, Herrington MT, Swenor KM, Eron LJ. Maggot Debridement Therapy in the Treatment of Complex Diabetic Wounds. *Hawaii Medical Journal*. 2011;70(6): 121-124.
30. Tian X., Liang XM., Song GM., Zhao Y., Yang XL. Maggot debridement therapy for the treatment of diabetic foot ulcers: a meta-analysis. J Wound Care 2013;22:462–469
31. Campbell N, Campbell D. A retrospective, quality improvement review of maggot debridement therapy outcomes in a foot and

leg ulcer clinic. *Ostomy Wound Management* 2014;60(7):16-25
32. Opletalová K, Blaizot X, Mourgeon B. Maggot therapy for wound debridement: a randomized multicenter trial. *Archives of Dermatology*. 2012;148(4):432–438.
33. Paul AG, Ahmad NW, Lee HL, Ariff AM, Saranum M, Naicker AS, Osman Z. Maggot debridement therapy with Lucilia cuprina: a comparison with conventional debridement in diabetic foot ulcers. Int Wound J. 2009 Feb;6(1):39-46. doi: 10.1111/j.1742-481X.2008.00564.x. PubMed PMID: 19291114.
34. Gilead L, Mumcuoglu KY, Ingber A. The use of maggot debridement therapy in the treatment of chronic wounds in hospitalised and ambulatory patients. J Wound Care. 2012 Feb;21(2):78, 80, 82-85. PubMed PMID: 22584527.
35. Arora S, Baptista A, Lim C. Maggot metabolites and their combinatory effects with antibiotic on Staphylococcus aureus. *Annals of Clinical Microbiology and Antimicrobials* 2011.
36. Sherman R. Mechanisms of Maggot-Induced Wound Healing: What Do We Know, and Where Do We Go from Here? *Evidence Based Complementary Alternative Medicine* 2014.
37. van der Plas MJA, van Dissel JT, Nibbering PH. Maggot Secretions Skew Monocyte-Macrophage Differentiation Away from a Pro-Inflammatory to a Pro-Angiogenic Type 2009. PLoS ONE 4(11): e8071
38. Adams CA Jr., Deitch EA. Diabetic foot infections. In: Holzheimer RG, Mannick JA, editors. Surgical Treatment: Evidence-Based and Problem-Oriented. Munich: Zuckschwerdt; 2001. Available from: http://www.ncbi.nlm.nih.gov/books/NBK6985/
39. Parnes A, Lagan KM. Larval Therapy in Wound Management: A Review. *International Journal of Clinical Practice* 2007;61(3): 488-493
40. Sherman RA, Mendez S, McMillan C. Using maggots in wound care: Part 1. *Wound Care Advisor* 2014. Available at: http://woundcareadvisor.com/using-maggots-in-wound-care-part-1-vol3-no4/.

Current Surgical Management of Charcot Neuroarthropathy: A Systematic Qualitative Review

Abigail B. Dunklee, BS, Alisha Poonja, BS, Edwin Zhu, BA, Kenny Luong, BA, and Sam Mark, BS

Abstract

Introduction
The purpose of this study is to evaluate the current surgical management of Charcot neuroarthropathy. A systematic literature review was conducted to assess the efficacy and limitations of current surgical treatments for Charcot neuroarthropathy, specifically internal fixation, external fixation, and a combination of both internal and external fixations.

Study Design: Qualitative Systematic Review of the Literature

Methods
An English language literature search was conducted on PubMed. Papers were found relating to Charcot Foot and the internal and external surgical methods of fixation by using the search terms “neuropathic arthropathy” OR “ Charcot” AND “surg$” AND “foot” AND “fixation”. The search was further narrowed to include articles from the past 5 years and to humans only.

Results
Twenty articles were obtained through the PubMed database. All twenty articles were used in this systematic qualitative review comparing internal fixation, external fixation, and a combination of both internal and external fixation.

Discussion and Conclusion
The goal of surgical treatment in Charcot neuroarthropathy reconstructive surgery is to stabilize the foot in a plantigrade alignment and to prevent further complications. Current literature supports the use of internal fixation, external fixation, and a combination of internal and external fixation. When potential wound complications or vascular compromise are the main concerns, internal fixation methods are typically utilized. However, for patients with severe bone loss, osteomyelitis, or significant soft tissue damage, external fixation is often more beneficial. When used in combination, the advantages of internal and external fixation respectively are compounded.

Key Words: Charcot foot, Charcot Neuroarthropathy, Charcot reconstruction, Diabetic neuropathy, Internal fixation, External fixation

Level of Evidence: 4

INTRODUCTION

Charcot foot or Charcot neuroarthropathy is a poorly understood deformity of the foot and ankle.[1] The deformity is most notably caused by peripheral neuropathy and diabetes mellitus and results in multiple joint dislocations and fractures with neuro-osteoarthropathy. Often this ultimately leads to complete destruction of the foot architecture.[1-6] Other possible causes of Charcot disease include: nephropathy, leprosy, rheumatoid arthritis, ulcerations of the foot, trauma, obesity and joint instability.[2-4]

There are multiple classification systems for Charcot neuroarthropathy. In 1966, Eichenholtz's landmark monography was published, which classified Charcot neuroarthropathy based on radiographic appearance and physiological course.[1] The process of the disease was classified into 3 stages with Shibata et al. later adding in Stage 0 or prestage 1.[1, 7] Stage 0 is characterized by erythema, edema, warmth and pain with little to no radiographic evidence of any fractures.[1, 7] During Stage 1, or the development stage, redness, swelling, and warmth continue with the radiographic appearance of bony debris, fragmentation or dislocation.[1,6,7] Stage 2, the coalescence stage, shows decreased erythema, edema and warmth, with the presence of reabsorption or fusion of bone fragments.[1,7] In the last stage, Stage 3, the remodeling stage, the foot reconsolidates and becomes stable again.[1,7]

Another parameter for classification involves the location of the deformity. The literature describes three different sets of classifications using this criterion. Sanders and Frykberg classified 5 anatomic patterns.[1] Pattern 1 involves the forefoot; pattern 2 involves the tarsometatarsal joints; pattern 3 involves the naviculocuneiform, talonavicular and calcaneocuboid joints; pattern 4 involves the talocrural and subtalar joints; and pattern 5 involves the calcaneus.[1]

The Brodosky classification system classifies the disease into various types.[1] Type 1 involves the midfoot region including the tarsometatarsal and naviculocuneiform joints; Type 2 involves the hind foot including the subtalar, talonavicular and calcaneocuboid joints; and Type 3 is separated into 3A and 3B, which involve the ankle joint and the posterior calcaneus, respectively.[1] The last method of classifying Charcot neuroarthropathy, based on anatomic location is the Schon classification system, which similarly classifies Charcot into 4 different patterns.[7] Pattern 1 involves the tarsometatarsal pattern; Pattern 2 involves

Table 1
Anatomic classification system for Charcot neuroarthropathy according to Sanders and Frykberg

Pattern	Location	Percentage of Cases
Pattern I	Forefoot (Metatarsophalangeal joint/Interphalangeal joint)	15
Pattern II	Tarsometatarsal joints	40
Pattern III	Naviculocuneiform, talonavicular, calcaneocuboid joints	30
Pattern IV	Talocrural, subtalar joints	10
Pattern V	Calcaneus	5

Table 1: Table from Crim, Brandon E., Lowery, Nicholas J., Wukich Dane K. Internal Fixation Techniques for Midfoot Charcot Neuroarthropathy in Patients with Diabetes in Clin Podiatr Med Surg 28 (2011) 63-685

Table 2
Anatomic classification system for Charcot neuroarthropathy according to Brodsky

Type	Location	Percentage of Cases
Type 1	Midfoot (tarsometatarsal, naviculocuneiform joints)	60
Type 2	Hindfoot (subtalar, calcaneocuboid, talonavicular joints)	25
Type 3A	Ankle joint	10
Type 3B	Posterior calcaneus	5

Table 2: Table from Crim, Brandon E., Lowery, Nicholas J., Wukich Dane K. Internal Fixation Techniques for Midfoot Charcot Neuroarthropathy in Patients with Diabetes in Clin Podiatr Med Surg 28 (2011) 63-685

the naviculocuneiform pattern; Pattern 3 involves the perinavicular pattern; and Pattern 4 involves the transverse tarsal pattern.[7]

Charcot neuroarthropathy can involve many complications such as ulcerations, infections and skin breakdown.[8] One treatment option has been a below the knee amputation to prevent the spread of infection. In the recent past, however, many orthopedic surgeons and podiatrists have looked to limb salvage techniques to help correct the Charcot foot deformity in patients and to prevent complications associated with the deformity. Surgical procedures range from exostectomies to corrective reconstruction procedures.[2] These procedures utilize internal fixation, external fixation or a combination of both. The goal of surgical intervention is to stabilize and realign the foot.[9] The objective of this literary review is to assess the efficacies and restrictions of the current surgical treatment options in order for the surgeon to be able to make an informed decision to create the most stable surgical construct.

METHODS

An English language literature search was conducted on PubMed. Papers were found relating to Charcot Foot and the internal and external surgical methods of fixation by using the search terms “neuropathic arthropathy” OR “ Charcot” AND “surg$” AND “foot” AND “fixation”. The search was further narrowed by restriction to only include articles from the past 5 years and for humans only.

RESULTS

Twenty articles were obtained through the PubMed database. All twenty articles were used in this systematic qualitative review to compare internal fixation, external fixation, and a combination of both internal and external fixation.

DISCUSSION

Internal Fixation

The use of internal fixation in Charcot neuroarthropathy reconstructive surgery allows for improved stability to the foot and simultaneous correction of the deformity. The utility of this method, however, is dependent on several factors including whether or not the soft tissue envelope will permit the placement of hardware.[10]

Plate Fixation

In instances where there is a high likelihood for failure, the use of superconstructs has been introduced.[1] These are defined as fusion that extends to unaffected joints, bone resection to decrease soft tissue tension, use of the strongest fixation device that the soft

tissue permits, and application of fixation devices in a way that creates maximal mechanical function.[2] According to Sammarco there are three superconstructs that can be utilized in Charcot midfoot deformity: plantar plating, locking plate technology, and axial screw fixation.[1]

The use of plates is a common method in Charcot neuroarthropathy reconstructive surgery. Plate fixation is often placed on the tension side of a deformity which increases the stability of the construct.[11] Plantar plating is an option for correction of sagittal plane deformities at the navicular-cuneiform-metatarsal joints, rocker-bottom midfoot deformities, and dislocations or subluxations in Charcot feet.[6, 11] Medial plating may be utilized for midfoot deformities with severe abduction or other transverse plane influences. For this technique, plates are placed along the medial column, which enables screws to cross the cortices of multiple metatarsal and tarsal bones.[11]

Locking plates, sometimes referred to as internal-external fixators, create a fixed angle construct. These devices are useful for osteoporotic bone because they attach the screws to a plate and thus prevent the screws from backing.[2] In contrast to other plating systems, locking plates do not require friction between the plate and bone to create compression.[2] As a result, they can be added to a construct in order to resist frontal plane rotation.[1] One advantage of newer, contoured models of locking plates is that they are able to be applied percutaneously. However, if locking plates are not properly applied they can interfere with bone healing. Additionally, if the bone segments are not properly aligned then the fixation could result in a nonunion.[1]

Diabetics who experience midfoot fractures and/or dislocations may benefit from the use of medial or lateral bridge plating. This construct involves extension of the fixation more proximal and distal so it is inserted into more stable bone.[11] As a result this plating is able to prevent collapse, malunion, and nonunion. For this technique, it is imperative that the surgeon considers anatomical details including the contour of the navicular, cuneiforms, calcaneus, and lateral metatarsals, as well as the arc of the cuneiforms and the ball and socket talonavicular joint.[2] The surgeon must also keep in mind the fact that this procedure requires normal joints to be compromised.[11]

Multiple, or stacked, plates have been cited in the literature as being a useful supplementation to the fixation for severely comminuted distal tibia or pilon fractures. The use of multiple plates can mitigate deforming forces that occur over time and may prevent collapse or malunion. However, the use of this construct is dependent on the soft tissue envelope.[2] An option available for rearfoot and ankle arthrodesis is blade plate fixation. These plates can be anchored through an anterior, posterior, or lateral approach.[11]

Plate fixation is a useful way to create a stable and plantigrade foot; however, it can be a challenge to apply. Most plate application requires large exposure to the area of interest, which simultaneously causes damage to the surrounding soft tissue. Additionally, the plates tend to be cumbersome and it is possible for them to cause increased strain in the overlying skin.[9] Additional details that need to be considered when choosing a plate fixation include the contour and length of the plate, the placement, the number of plates, and the types of screws.[2]

Screw & Nail Fixation

Another internal fixation technique places large diameter screws within the medullary cavity of medullary bone and extends them across the metatarsal joints and midfoot and into either the talus or cuboid.[1, 11] This technique is referred to as intramedullary beaming but is also known as axial screw placement and intramedullary foot fixation. It

is often used to create a stable construct in the unstable midfoot Charcot deformity.[6] Cullen et al. describes a midfoot fusion bolt as a 6.5-mm steel, solid-core, headless screw, which when placed along the longitudinal columns of the foot, constructs a beam.[12] The goal of intramedullary beaming both laterally and medially is to obtain fusion of the involved joints.[6]

Advantages of intramedullary nail fixation include limited damage to the soft tissue and diminished potential for wound complication or vascular compromise due to the plantar location and decreased periosteal stripping.[1] Additionally the intramedullary beaming is able to accept dorsal and plantar surface tension and disperse axial load which provides stability and allows fusion at multiple joints to occur.[1, 6] Cullen et al. also suggests that the construct is able to serve as a biologic barrier if wound dehiscence occurs. DeVries et al. noted that the retrograde intramedullary arthrodesis nail has a salvage of 95.2% and concluded that it creates a stable fixation.[5] A disadvantage of intramedullary beaming as mentioned by Stapleton and Zgonis is that it cannot be used in the presence of infection or osteomyelitis. There is also the potential for nonunion due to lack of compression, hardware failure, and persisting deformity.[11] Wiewiorski et al. noted one risk of intramedullary beaming is the possibility of axial migration of the bolt into the ankle joint.[9] Wiewiorski et al. performed a review of eight patients with neuroarthropathy and symptomatic rocker-bottom feet. His team used intramedullary beaming to fuse the medial metatarsocuneiform, medial naviculocuneiform, and talonavicular joints and concluded that this method was beneficial in reducing the risk of ulceration.[9] In another case report by Wiewiorski et al., researchers performed intramedullary medial column fusion using a solid bolt for a patient with an unstable rocker-bottom deformity. They concluded that this method was more resistant to shear loads than cannulated screws and that it was a beneficial technique for realignment of the medial column.[13]

Tan el al. reported on tibiocalcaneal arthrodesis with retrograde intramedullary nails or cannulated screws in 18 patients. After a mean follow-up period of 5.9 (range, 3-11) months, radiographic evaluation revealed a mean fusion time of 6.2 (range, 3-11) months using intramedullary nails and 5.3 (range, 3-9) months using cannulated screw fixation. They reported that retrograde intramedullary nails were superior to cannulated screws because they are stronger and can withstand bend and torsion. However, they also noted that patients with cannulated screws seemed to heal faster.[14]

Another scenario-specific Charcot neuroarthropathy reconstructive surgery technique is the Two-staged Boyd's operation as described by Altindas et al. This procedure involves a talectomy and calcaneotibial arthrodesis. The authors suggest that this procedure is advantageous because it shortens the limb and thus decreases equinus, allows for easy wound closure, facilitates weight bearing, and increases overall stability of the foot.[3]

Double row anchor fixation and excision of fracture fragments has been described by Greenhagen et al. for repair of a calcaneal insufficiency avulsion fracture, which is thought to be a Charcot neuropathic event. The authors utilized a suture bridge technique to repair the fracture, which they suggest provides more area for the Achilles tendon to be compressed to its insertion. They also suggest that pressure is reduced to the involved area by removal of the fracture fragments.[7]

Antibiotic-impregnated cement spacers have been cited in the literature as having a purpose in Charcot reconstructive surgery. Hong el al. utilized cement spacers in order to fill areas of bone loss and suggested that they enabled preservation of motion and

stability to the area by acting as a pseudojoint. In this case report a cement spacer was utilized after a talectomy in order to bridge the forefoot to the hindfoot in a patient with osteomyelitis. This provides another option for surgical reconstruction in a patient with compromised bone structure and infection.[15]

External Fixation

Static, Dynamic, and Hybrid External Fixators

There are various types of external fixation used for the stabilization of Charcot neuroarthropathy, each with their respective advantages and disadvantages. Static external fixators are primarily used to increase stability or to augment fixation. The most common static external fixation construct used for Charcot neuroarthropathy consists of a pre-built construct consisting of two circular rings for the tibia accompanied by a foot plate.[11] Dynamic external fixation most often implies the use of an Ilizarov or dynamic Taylor spatial frame and is used to address long-standing deformities that require gradual correction to achieve anatomic alignment. A potential challenge when performing Charcot reconstruction is the possibility of under-correction or over-correction in the management of the deformity. Dynamic external fixation allows for continuous postoperative adjustments and fine tuning, thus preventing postoperative complications such as non-unions.[11] For example, talectomy may be a component of Charcot reconstruction in patients with osteomyelitis or avascular necrosis of the talus. Once the talus has been removed, the surgeon must decide between acute shortening of the affected extremity, the use of a structural graft, or lengthening of the limb via dynamic external fixation.[11] Finally, stabilization via off-loading circular external fixation can be composed of a hybrid of other constructs and can be used to discourage any pressure on open lesions or soft tissue reconstruction.[11]

Advantages of External Fixation

Stabilization with external fixation may be beneficial in patients with severe bone loss, osteoporotic bone, ongoing osteomyelitis or other bone disorders.[11, 16] The work of Belvilacqua discusses the use of external fixation for patients with reduced bone density.[2] One of many hallmark findings of Charcot neuroarthropathy is bone resorption leading to osteopenia. Internal fixation carries the risk of failure due to inferior bone quality and lack of screw purchase.[17] Charcot reconstruction using internal fixation can be further complicated by damage to the vascular supply of the bone, whereas external fixation constructs allow for the placement of wires away from the affected joints. Belvilacqua et al. postulate that external fixation provides a stabilization method to maximize blood supply to the area of deformity, therefore preventing certain complications in patients with decreased bone quality.[2]

An additional advantage to the use of external fixation constructs is their continual access to a patient's skin and soft tissue. For example, patients with Charcot neuroarthropathy often have coexisting diabetic foot ulcerations.[17] The use of external fixation allows for placement of fixation away from the soft tissue defect while maintaining stabilization of the deformity. Therefore, the use of off-loading external fixation may benefit the healing of both the joints and the soft tissue envelope.[11] Similarly, external fixation may be advantageous for patients who require a skin graft or flap.[18] A case report was published by Ramanujam et al. discussing a 58 year old female who required a full thickness local advancement skin flap for the treatment of a non-healing ulceration secondary to a lateral column Charcot deformity with plantar subluxation. Off-loading external fixation may be advantageous in patients who require concomitant skin flaps or grafts as it protects

the flap from shearing and compression forces, allows access to the flap sites for frequent post-op care, and discourages the patient from weight bearing on the affected extremity.[18] In addition to simply off-loading, dynamic external fixation can improve wound healing as gradual correction can facilitate delayed closures by reducing the tension across pre-existing wounds.[11]

The specific joints involved in Charcot neuroarthropathy may influence whether a surgeon opts to use external fixation. In a study done by DeVries et al., the authors conducted a retrospective analysis examining 52 patients comparing the use of an intramedullary nail with or without the use of a circular external fixator in the stabilization of Charcot neuroarthropathy in the ankle. The authors hypothesized that the added stability provided by the use of an external fixator may benefit patients who are at high risk for complications or require extended arthrodesis; however, they failed to observe statistically significant differences between the two cohorts. DeVries et al. speculate that previous studies indicated benefits with the addition of external fixation because they examined stabilization of Charcot neuroarthropathy of the midfoot joints whereas their study examined breakdown of the ankle.[5]

Limitations of External Fixation

The use of an external fixator in Charcot reconstruction does provide numerous benefits; however, extensive planning is necessary to maximize the chances of limb salvage. The use of external fixation in Charcot reconstruction is often used in high-risk patient populations who have often had previous surgical attempts at stabilization. These cases can also be complicated by patient non-compliance and the presence of other comorbidities such as diabetes and obesity.[17] In addition, external fixation constructs may be difficult to manage, as they require constant observation.[18] Pin tract infections and other postoperative complications can be a deterrent to using external fixation for stabilization.[18] Also, an additional surgery is required for the removal of the device, multiplying the risks of anesthesia and other risks associated with any surgery. Once the device is removed, the patient may still require mechanical stability and off-loading[2]. Additionally, there are financial barriers due to high cost of external fixation constructs and psychological concerns of using large metal fixation devices constantly visible to the patient.[18] Finally, limb salvage using external fixation is a complicated procedure and further surgeries or amputations may be required in the future.

Combined Internal and External Fixation

Multiple studies have demonstrated that internal and external fixation techniques may be combined in order to enhance stability to the affected Charcot neuroarthropathic limb.[6, 10-11, 17, 19-20] While internal fixation techniques are able to provide the necessary correction and stability, when used alone it is associated with risk of failure secondary to complications. Internal fixation techniques such as tibiocalcaneal arthrodesis with talectomy may be risky for an osteopenic patient whose bone structure is unable to support the screw threads. Additionally, the postoperative course after a procedure utilizing internal fixation alone requires an extensive period of non-weightbearing.[11] External fixation can be combined with internal fixation techniques to offer advantages including mechanical bridging of the arthrodesis site and neutralization of stress within the tarsus. This allows greater stability and earlier weight bearing. External fixation also provides rigid stabilization and creates optimal conditions for wound healing and protection of the soft tissue envelope.[11]

Open reduction with percutaneous or internal fixation, followed by primary arthrodesis may be useful in a diabetic population with dense

peripheral neuropathy to provide osseous union and to maintain long-term stability in the midfoot.[10] However, it is also an invasive procedure that involves multiple surgical incisions and an extensive amount of fixation devices. The ultimate removal of these fixation devices is dependent upon the presence of healthy soft tissue. This may be problematic for diabetic patients with any degree of vascular compromise, which may predispose them to eventual skin necrosis.[10]

In one study described by Levitt et al, a patient underwent a staged reconstruction with initial surgical debridement, wide ulcer excision, and subsequent medial column arthrodesis. A circular external fixator was then applied for rearfoot/ankle stabilization and removed after approximately 7 weeks. This case effectively demonstrated that external fixation can be used in combination with internal fixation for enhanced postoperative stability.[10]

LaPorta et al. described another case in which a 60-year-old diabetic male presented with left hindfoot Charcot deformity and a chronic wound under talar head with cellulitis and purulent drainage. MRI demonstrated osteomyelitis of the talus. The patient underwent incision and drainage with total talectomy and tibiocalcaneal fusion. An autograft from the patient's resected fibula was used as a graft to augment the fusion site and an external fixator was applied.[17] Both the internal fixation and external fixation devices were removed at 4 months. At 2.5 years after the tibiocalcaneal arthrodesis the patient developed an acute Charcot flare-up at the level of the previous fusion site. Surgeons re-applied an external fixator and it remained for 4 months. At his most recent follow-up, 9 years after the removal of the external fixator, the patient had a stable pseudoarthrosis, was ambulating in diabetic shoes and a cane, and was independently operating a motor vehicle.7[17]

Intramedullary foot fixation (IMFF) along with external fixation has also been cited in the literature. IMFF was stated to achieve maximum anatomic realignment while preserving foot length. Additionally, it offers a considerable amount of rigidity in terms of interosseus fixation and it requires limited dissection, which allows for improved healing.[6] More importantly, it can be used as a primary procedure by itself, or secondary to external fixation. When IMFF is used in combination with external fixation, the follow-up is biweekly with the patient weight bearing as tolerated with an assistive device.[6]

Jeong et al described a case of successful application of combined internal and external fixation. A 43-old-male with type 2 diabetes presented with a swollen right ankle. The patient underwent ankle arthrodesis with a transfibular approach using multiple screw fixations. A ring external fixator was applied to the arthrodesis site for postoperative stabilization. Postoperatively the patient was allowed partial weight bearing with crutch ambulation at 12 weeks. The external fixator was removed at 3 months and a short leg cast was then applied for an additional 3 months. Complete union was achieved at 6 months post-operation.[20]

Recent literature supports the use of combined internal and external fixation in the treatment of Charcot neuroarthropathy reconstructive surgery. When used in combination, this technique offers increased stabilization of primary arthrodesis and of the initial reduction of the deformity. It can also enhance the stabilization of proximal rearfoot or ankle joints.[10]

CONCLUSION

Charcot neuroarthropathy often leads to debilitating deformities of the foot and ankle.[13] Surgical intervention must be considered if conservative treatment fails to prevent complications such as reduced bone density,

recurrent plantar ulceration, and consequent infection.[9] The primary goal of surgical treatment is to stabilize the foot in a plantigrade alignment to prevent further complications.[9]

Current literature supports the use of internal fixation, external fixation, and a combination of both internal and external fixation depending on the severity of the Charcot deformity and the condition of the patient. Sammarco suggests three superconstructs that can be utilized in Charcot midfoot deformity in cases where there is a high likelihood of failure for internal fixation: plantar plating, locking plate technology, and axial screw fixation.[1] When damage to the soft tissue and potential wound complication or vascular compromise are the main concerns, intramedullary nail fixation can be considered.[1] For patients with severe bone loss, ongoing osteomyelitis or other bone disorders, stabilization with external fixation is cited to be most beneficial.[11] One of the disadvantages for external fixation is the necessity for an additional surgery to remove the external fixation. DeVries el al. reported a cohort study on the combination of internal fixation and external fixation for Charcot neuroarthropathy. However, DeVries et al. failed to observe any statistical significance in a retrospective analysis examining 52 patients comparing the use of an intramedullary nail with or without the use of a circular external fixator in the stabilization of Charcot neuropathy in the ankle.[5]

A limitation of this study is the lack of long-term follow-up for each surgical intervention described because the articles used were recently published within a 5-year period. This opens up a future research topic to study the long-term failure rates and long-term patient satisfaction with the fixation used.

AUTHORS' CONTRIBUTIONS

All authors contributed to the design of the manuscript and performed literature review from the PubMed database.

STATEMENT OF COMPETING INTERESTS

The authors declare that they have no competing interest associated with this manuscript.

REFERENCES

1. Crim B, Lowery N, Wukich D. Internal Fixation Techniques for Midfoot Charcot Neuroarthropathy in Patients with Diabetes. *Clinics in Podiatric Medicine and Surgery*. 2011;28(4):673-685. doi:10.1016/j.cpm.2011.08.003.
2. Bevilacqua N, Stapleton J. Advanced Foot and Ankle Fixation Techniques in Patients with Diabetes. *Clinics in Podiatric Medicine and Surgery*. 2011;28(4):661-671. doi:10.1016/j.cpm.2011.06.007.
3. Altindas M, Kilic A, Ceber M. A new limb-salvaging technique for the treatment of late stage complicated Charcot foot deformity: Two-staged Boyd's operation. *Foot and Ankle Surgery*. 2012;18(3):190-194. doi:10.1016/j.fas.2011.10.006.
4. Burns P, Highlander P, Shinabarger A. Management in High-risk Patients. *Clinics in Podiatric Medicine and Surgery*. 2014;31(4):523-538. doi:10.1016/j.cpm.2014.06.007.
5. DeVries J, Berlet G, Hyer C. A Retrospective Comparative Analysis of Charcot Ankle Stabilization Using an Intramedullary Rod with or without Application of Circular External Fixator-Utilization of the Retrograde Arthrodesis Intramedullary Nail Database. *The Journal of Foot and Ankle Surgery*. 2012;51(4):420-425. doi:10.1053/j.jfas.2012.03.005.
6. Lamm B, Siddiqui N, Nair A, LaPorta G. Intramedullary Foot Fixation for Midfoot Charcot Neuroarthropathy. *The Journal of*

Foot and Ankle Surgery. 2012;51(4):531-536. doi:10.1053/j.jfas.2012.04.021.
7. Greenhagen R, Highlander P, Burns P. Double Row Anchor Fixation: A Novel Technique for a Diabetic Calanceal Insufficiency Avulsion Fracture. *The Journal of Foot and Ankle Surgery*. 2012;51(1): 123-127. doi:10.1053/j.jfas.2011.09.006.
8. Hastings M, Johnson J, Strube M, Hildebolt C, Bohnert K, Prior F, Sinacor D. Progression of Foot Deformity in Charcot Neuropathic Osteoarthropathy. *The Journal of Bone and Joint Surgery (American)*. 2013;95(13):1206. doi:10.2106/jbjs.l.00250.
9. Wiewiorski M, Yasui T, Miska M, Frigg A, Valderrabano V. Solid Bolt Fixation of the Medial Column in Charcot Midfoot Arthropathy. *The Journal of Foot and Ankle Surgery*. 2013;52(1):88-94. doi:10.1053/j.jfas. 2012.05.017.
10. Levitt B, Stapleton J, Zgonis T. Diabetic Lisfranc Fracture-Dislocations and Charcot Neuroarthropathy. *Clinics in Podiatric Medicine and Surgery*. 2013;30(2):257-263. doi:10.1016/j.cpm.2013.01.002.
11. Stapleton J, Zgonis T. Surgical Reconstruction of the Diabetic Charcot Foot. *Clinics in Podiatric Medicine and Surgery*. 2012;29(3):425-433. doi:10.1016/j.cpm. 2012.04.003.
12. Cullen B, Weinraub G, Van Gompel G. Early Results with Use of the Midfoot Fusion Bolt in Charcot Arthropathy. *The Journal of Foot and Ankle Surgery*.
2013;52(2):235-238. doi:10.1053/j.jfas. 2012.12.003.
13. Wiewiorski M, Valderrabano V. Intramedullary Fixation of the Medial Column of the Foot with a Solid Bolt in Charcot Midfoot Arthropathy: A Case Report. *The Journal of Foot and Ankle Surgery*. 2012;51(3):379-381. doi:10.1053/j.jfas. 2012.02.010.
14. Tan B, Ng S, Chong K, Rikhraj S. Tibiocalcaneal Arthrodesis in a Singaporean Hospital. *Journal of Orthopedic Surgery.* 2013;21(1)51-54.
15. Hong C, Jin Tan K, Lahiri A, Nather A. Use of a Definitive Cement Spacer for Simultaneous Bony and Soft Tissue Reconstruction of Mid- and Hindfoot Diabetic Neuroarthropathy:A Case Report. *The Journal of Foot and Ankle Surgery*. 2015;54(1):120-125. doi:10.1053/j.jfas. 2014.10.009.
16. Ramanujam C, Stapleton J, Zgonis T. Diabetic Charcot Neuroarthropathy of the Foot and Ankle with Osteomyelitis. *Clinics in Podiatric Medicine and Surgery*. 2014;31(4): 487-492. doi:10.1016/j.cpm.2013.12.001.
17. LaPorta G, Nasser E, Mulhern J. Tibiocalcaneal Arthrodesis in the High-Risk Foot. *The Journal of Foot and Ankle Surgery*. 2014;53(6):774-786. doi:10.1053/j.jfas. 2014.06.027.
18. Ramanujam C, Facaros Z, Zgonis T. External Fixation for Surgical Off-Loading of Diabetic Soft Tissue Reconstruction. *Clinics in Podiatric Medicine and Surgery*. 2011;28(1):211-216. doi:10.1016/j.cpm. 2010.10.004.
19. DiDomenico L, Brown D. Limb Salvage: Revision of Failed
Intramedullary Nail in Hindfoot and Ankle Surgery in the Diabetic Neuropathic
Patient. *The Journal of Foot and Ankle Surgery*. 2012;51(4):523-527. doi:10.1053/ j.jfas.2012.02.015.
20. Jeong S, Park H, Hwang S, Kim D, Nam D. Use of Intramedullary Nonvascularized Fibular Graft with External Fixation for Revisional Charcot Ankle Fusion: A Case Report. *The Journal of Foot and Ankle Surgery*. 2012;51(2):249-253. doi:10.1053/ j.jfas.2011.10.026.

Effects of Adjuvants on Onset and Duration of Local Anesthetics Used In Regional Nerve Block

Amara Abid, BS, MSC, Alina Kogan, BS, and Nader Ghobrial, BS, MSC

Abstract

Introduction
The purpose of this study is to review the different drugs used as adjuvants to local anesthetic agents in regional nerve blocks in order to find out which drugs are effective in improving the local anesthetic action.

Study Design: Systematic Review of the Literature

Methods
A PubMed search limited to papers published between 2013 and 2015 was performed. Independent literature searches were performed using the keywords “nerve block" AND one of the following terms: adjuvants, opioids, buprenorphine, morphine, fentanyl, vasoactive agents, epinephrine, clonidine, dexmedetomidine, anti-inflammatory drugs, dexamethasone, NOT "upper extremity”. Informal reviews, letters, publications prior to 2013 and non-English papers were excluded. A total of 899 articles were identified through the database search.

Results
When vasoactive agents dexmedetomidine and clonidine were added to ropivacaine or bupivacaine, there was full blockage of sensory function with an earlier onset and prolonged postoperative analgesia. Epinephrine delays the uptake of local anesthetics and reduces the risk of anesthetic toxicity, but has conflicting studies on whether it prolongs the duration of postoperative analgesia. Duration of local anesthesia was increased by dexamethasone in short-, medium- and long-term acting local anesthetics. Also, patients who received buprenorphine with dexamethasone had longer nerve block duration, lower scores of postoperative pain and decreased (reduce in the amount of opioids required?) usage of opioids. Opioid agents (morphine, fentanyl and nalbuphine) have a role in increasing the quality of intra- and postoperative pain control when combined with either neuraxial or peripheral local anesthetics.

Conclusion
Dexmedetomidine and clonidine both prolonged postoperative analgesia. However, there is uncertainty as to whether epinephrine prolongs postoperative analgesia. Dexamethasone prolongs nerve block duration, decreases postoperative pain, and opioid usage. Opioids (morphine, fentanyl and nalbuphine) prolong postoperative analgesia and increase intraoperative pain control quality.

Key Words: nerve block, adjuvants, opioids, buprenorphine, morphine, fentanyl, vasoactive agents, epinephrine, clonidine, dexmedetomidine, anti-inflammatory drugs, dexamethasone

Level of Evidence: 4

INTRODUCTION

Local anesthesia evolved as a method to deliver safe anesthesia for different types of surgeries and also for providing postoperative analgesia. Since the introduction of the concept of local anesthesia, efforts have been made to improve it technically and qualitatively. The most important component of local anesthesia are the local anesthetic drugs which work by blocking neuronal sodium channels. Two families of local anesthetics we know esters and amides. In each local anesthetic family there are many agents. Both families vary regarding the pharmacokinetics and pharmacodynamics. Techniques such as neuraxial, local infiltration, intra-articular and regional nerve blocks are used to deliver those agents to their site of action. With the use of adjuvant agents and different anesthetizing techniques, local anesthetics can be modified regarding their efficacy and quality of action at the surgical site.

The use of local anesthetic peripheral nerve blocks for anesthesia and postoperative analgesia has increased and adjuvants are often added to these local anesthetics in order to prolong postoperative analgesia. [7] Moreover, adjuvants may also be helpful in patients who have anxiety, which may lead to hypertension, arrhythmia, and an increase in myocardial oxygen consumption by causing higher sympathetic stimulation in patients that are undergoing surgery.[2] Sedation and non-surgical pain management have become ways of targeting this anxiety in patients, so the primary aim of sedation is to provide comfort to patients, and maintain their hemodynamic stability.[2]

Opioids are one type of adjuvant that could be used to increase the level and duration of analgesia after arthroscopic joint surgery.[7] Peripheral administration of opioids (e.g. in knee arthroscopy) is associated with some clinical benefits. Because of morphine's long duration of action, it's the narcotic that fits this purpose. Morphine has an anti-inflammatory effect on joints and has no chondrotoxicity.[8] Nalbuphine is an opioid drug with mixed μ antagonist and κ agonist properties, and when applied intrathecally it can cause analgesia after lower limb and lower abdominal surgeries.[11] Combining the use of a transdermal fentanyl patch with either a sciatic or femoral–sciatic nerve block would improve pain control in patients undergoing foot and/or ankle surgery.[6]

Vasoactive agents are another group of adjuvants that can be used as additives to local anesthetic in order to prevent the reabsorption of local anesthetics and thus prolong postoperative analgesia.[7] Dexmedetomidine, clonidine, and epinephrine are three vasoactive agents that are commonly used as adjuvants to local anesthetics. Dexmedetomidine is an α-2 agonist, which is more selective than clonidine and can cause sedation without causing anesthesia, while also having analgesic and sympatholytic properties.[2] Clonidine is an α-2 agonist that has vasoconstrictor properties, but unlike epinephrine can prolong nerve blockades on peripheral nerves[7]. Higher doses of clonidine can cause sedation and hypotension, however, at lower doses clonidine will prolong motor and sensory nerve blocks.[6] Epinephrine is believed to prolong the duration of local anesthetics by way of its vasoconstricting properties that prevent systemic reabsorption of local anesthetic.[7]

Dexamethasone is a glucocorticoid agonist which is commonly used as an anti-inflammatory or immunosuppressive agent. It can cross the cell membrane and binds to intracellular glucocorticoid receptors.[1] The complex formed, called glucocorticoid response element, leads to changes in transcription and protein synthesis and causing an anti-inflammatory response by inhibiting the infiltration of leukocytes to the site of inflammation.[1] Dexamethasone is

used today in anaesthesia in order to prevent post-operative nausea and vomiting.[4] Meta-analyses demonstrate that administration of dexamethasone results in reduced post-operative pain and also opioid usage.[5]

The purpose of this systematic review is to show the clinically recommended adjuvants that when used in certain doses with local anesthetic drugs during regional nerve blocks would improve the onset and duration of action with no or minimal side effects as compared to using local anesthetics alone in regional nerve blocks.

METHODS

A review of the literature was performed using Pubmed of papers published between 2013 and 2015. Eleven independent literature searches were performed using the Pubmed database. The search was done using the Boolean "AND" and "NOT" operators. The first search included the keywords “nerve block" AND "adjuvants" NOT "upper extremity” and provided 28 articles. The second search included the terms "nerve block" AND "opioids" NOT "upper extremity" and provided 273 articles. The third search included the terms "nerve block" AND "buprenorphine" NOT "upper extremity" and provided 10 articles. The fourth search included the terms "nerve block" AND "morphine" NOT "upper extremity" and provided 164 articles. The fifth search included the terms "nerve block" AND "fentanyl" NOT "upper extremity" and provided 81 articles. The sixth search included the terms "nerve block" AND "vasoactive agents" NOT "upper extremity"

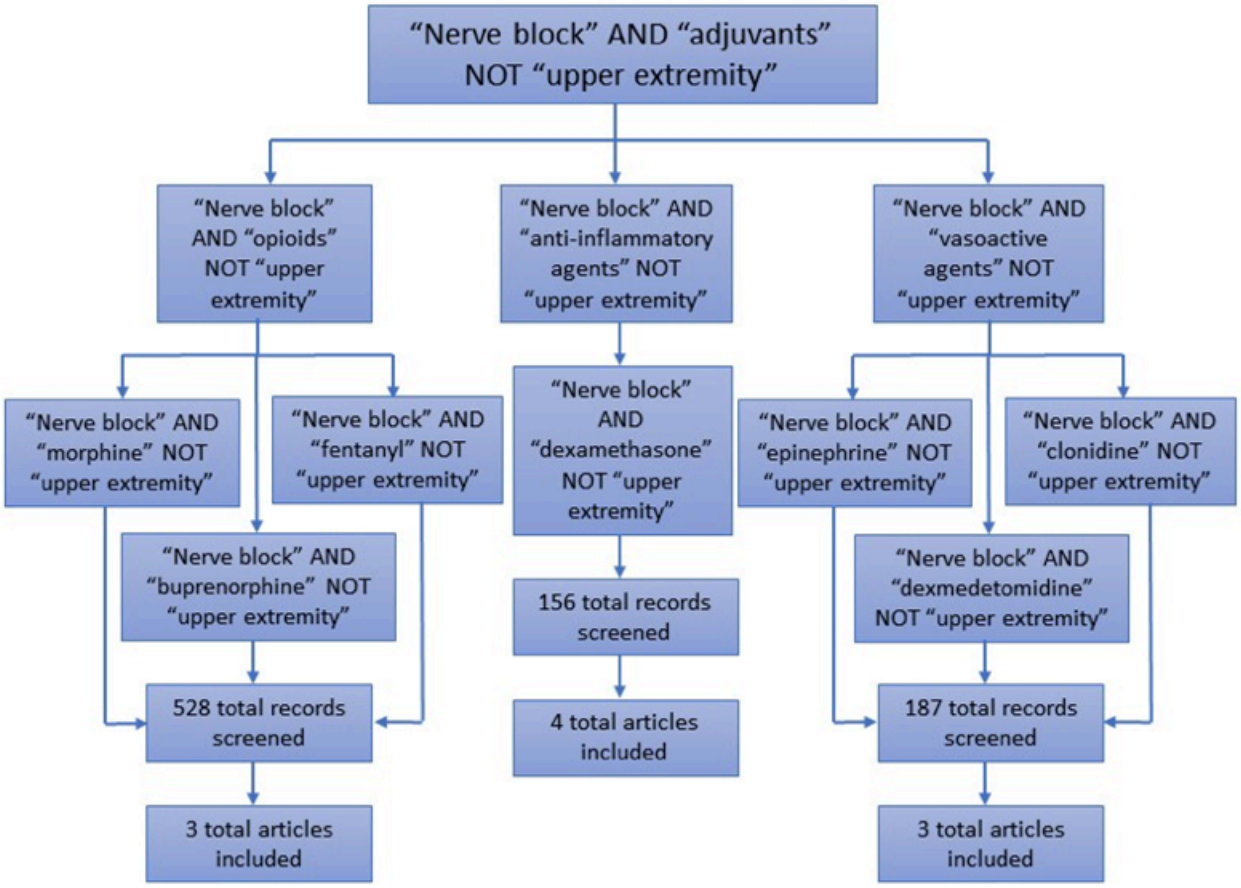

Fig 1: Summary of search results from PubMed Database.

and provided 1 article. The seventh search included the terms "nerve block" AND "epinephrine" NOT "upper extremity" and provided 117 articles. The eighth included the terms "nerve block" AND "clonidine" NOT "upper extremity" and provided 26 articles. The ninth search included the terms "nerve block" AND "dexmedetomidine" NOT "upper extremity" and provided 43 articles. The tenth search included the terms "nerve block" AND "anti-inflammatory drugs" NOT "upper extremity" and provided 108 articles. The eleventh search included the terms "nerve block" AND "dexamethasone" NOT "upper extremity" and provided 48 articles. Informal reviews, letters, prior to 2013 and non-English papers were excluded. A total of 899 articles were identified through the database search. A total of ten articles were selected and included in the review based on inclusion criteria, which included limb orthopedic surgeries conducted under regional nerve block and the usage of opioid, vasoactive or anti-inflammatory adjuvants with the local anaesthetic techniques. See Figure 1 for a summary of the searches conducted with the PubMed database.

RESULTS

I. Opioids

Jae-Hwang Song et al. studied the effect of adding fentanyl patch and intravenous midazolam to the patients underwent foot and ankle surgery under sciatic or femoral-sciatic nerve block using a mixture of lidocaine and ropivacaine injection compared to a control group who received the nerve blocks only.[5] The exclusion criteria include patients with neuromuscular, neurologic or disorders and any patients with signs of infection.[5] While Mitra Yari et al. conducted a double-blind clinical trial on 40 ASA I athletes who had undergone elective surgery for arthroscopic ACL reconstruction dividing the patients into four groups to compare the effect of adding different doses of intraarticular morphine (5, 10 and 15 mg) to intraarticular bupivacaine and a control group who received intraarticular bupivacaine only.[3] With the exclusion criteria include patients that has history of drug addiction.[3] Also, Shehla Shakooh et al studied the effect of adding (preservative free) Nalbuphine to heavy bupivacaine (0.75% Bupivacaine in 8.25% glucose) in patients undergoing lower extremity and lower abdominal surgeries under spinal anesthesia compared to control group who received only spinal heavy bupivacaine.[4] Exclusion was made to patients with history of drug hypersensitivity, long term analgesic therapy, signs of infections at the site of injection, coagulopathy and spinal deformities.[4]

Jae-Hwang Song and colleagues as well as Mitra Yari et al. primary outcome was investigating the number of requested additional postoperative pain medications the patients received.[5] The secondary outcome of interest was the degree of postoperative measured pain using a visual analog scale (VAS). Complications were monitored and metoclopramide was given for nausea.[5–3] Shehla Shakooh et al observations were made for time of drug administration, onset, complete sensory and motor block, recovery from the block, sedation, time when pain occur (VAS >3 cm) and adverse effects.[4]

The randomized controlled trial in Jae-Hwang Song et al. study shows that 47.12% in the control group patients and 27.16% in the treatment group requested postoperative analgesia. The mean VAS scores were lower in the treatment group. The combined use of midazolam and fentanyl in the treatment group did not result in any observed complications.[5] In Mitra Yari et al. double blinded clinical trial by using bupivacaine + 15mg morphine and bupivacaine + 10 mg morphine groups, there is significant difference in the mean VAS scores in addition to higher average time to the first analgesic request than the bupivacaine only group and bupivacaine + 5 mg morphine. No significant difference regarding complications between

all the four groups.[3] Shehla Shakooh et al. shows that there was significant difference between mean onset and complete sensory block between the treatment group and the control group with the treatment group a faster onset, shorter the time to achieve complete block and more prolonged postoperative analgesia than the control group.[4]

Jae-Hwang Song et al. found that the use of a fentanyl patch applied immediately after foot and ankle surgery using combined femoral, sciatic nerve block for anesthesia had more effective pain control and less adverse effects and complications than did combined femoral, sciatic nerve block alone in patients undergone foot and ankle surgeries.[5] Mitra Yari et al. indicate that the combination of bupivacaine with 15 mg morphine when compared to the 10mg and 5mg morphine with bupivacaine and bupivacaine alone has beneficial effects on reducing arthroscopic surgery pain and provides longer lasting analgesia without significant side effects.[3] Shehla Shakooh et al. demonstrates that the Nalbuphine group has showed faster onset and the time for complete sensory and motor block was shorter as compared to the control group. Postoperative regression of both sensory and motor block was slower and the need for first rescue analgesia was later in the Nalbuphine group. With lesser side effects in Nalbuphine group. Furthermore, Rawal et al found that even in large doses nalbuphine has the least irritating effect on neural tissue and has a minor behavioral and EEG changes.[4]

Limitations in the Jae-Hwang Song et al. study include no adjustment was made for the type of the surgeries that has been done for the patients also; in those in the fentanyl group who had postoperative nausea and received Metoclopramide. Its effect was not adjusted. Moreover, the human factors include the patients and the surgeon blockage efficiency.[5] In Mitra Yari et al. study limitation was that there is no significant difference between the 4 groups in the first four postoperative hours.[3] While in Shehla Shakooh et al. study the limitations shown by Tiwari et al. in another study that the onset of sensory and motor blockade was not affected by adding nalbuphine intrathecally.[4]

II. Vasoactive Agents

Three vasoactive agents were evaluated for their onset time and duration of analgesic effects. These agents included dexmedetomidine, clonidine, and epinephrine. Yektas. et al. compared the sedative effect of infused Dexmedetomidine with the effect of infused propofol in patients undergoing a sciatic and femoral nerve block for lower limb orthopedic procedures.[2] Singh et al. evaluated the effect of clonidine and/or fentanyl in combination with intrathecal bupivacaine for lower extremity surgery.[6] Schoenmakers K. P. W. et al. performed a prospective, double-blind, randomized study on adults over the age of 18 with ASA physical health classification of I-III in order to assess postoperative analgesia following the addition of epinephrine to ropivacaine for a popliteal nerve block.[10]

Inclusion criteria for Yektas et al. consisted of patients between the ages of 18 and 65 who belonged to the American Society of Anesthesiologists (ASA) classification I-II and were undergoing surgical procedure due to lateral and medial malleolar fractures.[2] Patients with vascular disease, cardiac disease, metabolic renal hepatic disease, pregnancy, hemodynamic instability, drug use that could cause acid-base imbalance, history of steroid use and allergy, contraindications for regional anesthesia, alcohol and/or drug addiction, and those who did not graduate from primary school were excluded from the study.[2] Singh et al. included 100 adult patients with ASA grades of I and II, who were split into four groups of twenty-five people and excluded patients who were on α blockers, had contraindications against regional anesthesia, a history of

ischemic heart disease, a history of hepatic or renal diseases, hypertension, diabetes mellitus, neuropathies, rheumatoid arthritis, spinal deformities, and a history of allergy or anaphylaxis to local anesthetics.[6] Schoenmakers K. P. W. et al. included adults over the age of 18 with ASA physical health classification of I-III, whereas patients with contraindications for regional anesthesia, hypersensitivity to amide-type local anesthetics, history of peripheral neuropathy, inability to understand numerical pain scales, and an inability to operate a patient controlled analgesia (PCA) device.[10]

Each study administered different dosages of anesthetic and adjuvant as compared to each other. In Yektas et al.'s study, 1 μg kg^{-1} of dexmedetomidine was administered for the first 10 minutes and 0.5 μg kg^{-1} h^{-1} was administered throughout the surgery.[2] Singh et al. administered hyperbaric bupivacaine of 7.5 mg (1.5 mL) and clonidine of 75 μg (0.5 mL).[6] In Schoenmakers study two groups were formed of 15 people, one of which received 30 mL of ropivacaine 0.75 % without 5 μg/mL of epinephrine (ROPI) and one which received 30 mL of ropivacaine 0.75% with 5 μg/mL of epinephrine (ROPI-EPI).[10]

Onset, duration, and postoperative analgesia were evaluated on different scales between the studies. For Yektas et al. the Ramsay sedation scale (RSS) was used to assess the level of sedation, and the modified Aldrete scoring system was used to assess the recovery from anesthesia.[2] Scores of 2 – 4 on the RSS scaled signified sedation and RSS scores were recorded every 5 minutes.[2] In Singh et al.'s study patients were instructed to use the visual analogue scale (VAS) preoperatively as a tool for measuring postoperative pain.[6] The highest level of sensory block was evaluated every 5 minutes for a total duration of 20 minutes following injection of the anesthetic with the adjuvant.[6] The sensory block was recorded at 5, 10, 15, and 20 minutes after intrathecal injection and subsequently every 15 minutes.[6] The postoperative sensory and motor block recovery was assessed every 15 minutes for 3 hours.[6] Pain scores were assessed at 0, 0.5, 1.5, 2, 3, 4, 8, 12, 18, and 24 hours and any patient reporting a VAS of 3 or more was administered a supplemental dose of analgesic.[6] Schoenmaker et al. evaluated the intensity of operative pain using the numeric rating scale (NRS) with "0" representing no pain and "10" representing the worst pain possible.[10] TTFR was used to reflect the duration of sensory sciatic nerve block and the duration of analgesia and was defined as the time from t=0 to the point at which the patient first made the request for analgesia via the PCA pump.[10]

Dexmedetomidine had a faster onset time of 8.10 ± 1.07 minutes compared to clonidine, which had a sensory onset time of 10.20 ± 1.00 minutes and motor block onset time of 14.00 ± 2.04 minutes.[2,6] Patients infused with dexmedetomidine took 22.30 ± 3.32 minutes to recover from sedation following the discontinuation of the sedative.[2] The duration of the sensory block for clonidine was 128.20 ± 14.85 minutes and the duration for the clonidine motor block was 111.60 ± 9.80 minutes.[6] Clonidine also had lower VAS scores at 4 hours post-operation and required less analgesia.[6] The median time to the first request for postoperative analgesia was 463 minutes in patients that were not given epinephrine with ropivacaine and 830 minutes for patients that were given epinephrine with ropivacaine.[10] So patients to whom epinephrine was administered had longer postoperative analgesia than patients infused with dexmedetomidine and clonidine.

Dexmedetomidine provided a dose-dependent sedation and prolonged the sensorial block and did not produce nausea, vomiting, or hemodynamic impairment.[2] The addition of 75μg of clonidine to bupivacaine increased the duration of both sensory and motor blockade and reduced the need for postoperative analgesia.[6] Lower VAS scores were observed for 12 hours, and a

significantly reduced 24-hour supplemental analgesic consumption was noted in groups that received clonidine.[6] Administration of epinephrine showed a significant increase in the duration of postoperative analgesia.[10]

Each of the studies about dexmedetomidine, clonidine, and epinephrine had limitations. The RSS scale that was used to assess sedation in patients infused with dexmedetomidine is subjective because it requires the patient to provide verbal evaluations.[2] There was a small sample size for clonidine infusion and different doses of clonidine were not tested.[6] For epinephrine sensory and motor block duration wasn't measured at regular block intervals and TTFR is a subjective measure of block duration.[10]

III. Anti-inflammatory Agents

Huynh T. M. et al. evaluated the clinical effects of dexamethasone when combined with local anesthetic on peripheral nerve block performed in adults.[9] whereas YaDeau J. T. et al. evaluated the clinical effects of dexamethasone and buprenorphine when added to bupivacaine sciatic nerve block in a randomized controlled trial.[11] Popliteal nerve blocks, which include the lower sciatic nerve block, are important in aiding with postoperative pain control.[11] Huynh T. M. trial consisted of 1054 patients, out of which 512 received peri-neural dexamethasone and all of the nerve blocks were conducted as a single injection in patients undergoing surgery.[9] Three doses of dexamethasone (4, 8, and 10 mg) were combined with intermediate and long acting local anesthetics.[9] YaDeau J. T. study consisted of ninety patients that were divided into 3 groups; control group received nerve blocks using bupivacaine and IV dexamethasone; group 2 received control blocks + IV dexamethasone + IV buprenorphine; group 3 received control block with perineural injections of buprenorphine and dexamethasone.[11] Duration of analgesia, which is relief from pain, was reported. [9] and pain assessment was conducted on a numerical rating scale.[11]

Exclusion criteria in Huynh T. M. et al. study included repeated injections of anesthesia, intravenous regional anesthesia, intravenous administration of dexamethasone, healthy volunteers, children, and animal studies.[9] Exclusion criteria in YaDeau J. T. et al. study included surgery causing pain distally in the lower extremity, bilateral surgery, usage of opioids or steroids for more than 3 months, contraindications to popliteal fossa nerve block with 0.25% bupivacaine, contraindication to dexamethasone or buprenorphine, and lack of sensation in the leg operated on[11].

In Huynh T. M. et al. study, duration of analgesia was reported in 874 patients.[9] In the control group, the median time to the administration of postoperative analgesic was 325 minutes.[9] Dexamethasone administration increased the duration of analgesia to 351 minutes.[9] The duration of motor blockade was 202 minutes in control group with median duration of analgesia of 167 minutes whereas in the dexamethasone group motor blockade was 278 minutes and median duration of analgesia was 708 minutes.[9] Addition of dexamethasone doubled postoperative analgesia duration when combined with local anesthetic solutions.[9] Dexamethasone increased the duration of motor blockade when administered with intermediate and long acting local anaesthetics.[9] Dexamethasone decreased the median time to onsept of sensory blockade as compared to the control group.[9] In YaDeau J. T. et al. study, the addition of buprenorphine and dexamethasone in the popliteal fossa for the sciatic nerve block did not improve pain.[11] However, the group with perineural buprenorphine with dexamethasone had lower pain scores, representing the least amount of pain.[11] The group which received perineural buprenorphine with dexamethasone had

longer block duration (45.6 hours) than the group which received IV dexamethasone group (30 hours).[11] Usage of intravenous buprenorphine caused severe nausea and vomiting, but the group which received perineural buprenorphine with dexamethasone did not have nausea.[11]

These randomize control trials in Huynh T. M. et al. study demonstrates that combination of dexamethasone with intermediate and long acting local anaesthetics prolongs the duration of analgesia and motor blockade in peripheral nerve block.[9] Administration of dexamethasone also decreases the incidence of postoperative nausea and vomiting.[9] All the results demonstrate benefits of using dexamethasone with local anesthetics as compared to plain solutions.[9] The median pain scores reported by YaDeau J. T. et al. after 24 hours of foot and ankle surgery by all three groups were not improved by the addition of perineural or IV buprenorphine with dexamethasone.[11] However, the third group with perineural injection of buprenorphine and dexamethasone had prolonged block duration, reduced pain level experienced and reduced usage of opioids post-operatively.[11] Therefore both studies demonstrate prolonged block duration.

Limitations in Huynh T. M. et al. study includes the peripheral nerve blocks not guided via an ultrasound, whereas now ultrasonography is commonly used which can increase the reliability of the blocks.[9] Limitations in YaDeau J. T. et al. includes intravenous buprenorphine administration which caused moderate nausea and vomiting and thus these observations must be further evaluated.[11]

CONCLUSION

Combining an opioid drug (fentanyl patch, intra-articular morphine or intrathecal Nalbuphine) with regional blocks (spinal, nerve block or intraarticular injection) using local anesthetic drugs has shown more rapid onset, prolonged duration and more effective postoperative pain control than using local anesthetic drugs alone without any major adverse effects.[5,3,4] Dexmedetomidine, clonidine, and epinephrine were all found to have an increased duration of postoperative analgesia when used in combination with local anesthetic.[2,6,10] Dexmedetomidine and clonidine were found to have a prolonged duration of sensorial blocks.[2,6] Intrathecal clonidine was found to have a rapid onset.[6] Anti-inflammatory adjuvant dexamethasone with local anesthetic solution prolongs the duration of peripheral nerve block.[9] and the perineural injection of buprenorphine and dexamethasone prolongs block duration, reduces worst pain experienced and the usage of opioids post-operatively.[11] Conclusively, the addition of opioids, vasoactive agents or anti-inflammatory agents to local anesthetic drugs in nerve blocks has a great effect as it makes the onset faster, prolongs the duration and makes the block more solid and efficient with minimal adverse effects.

AUTHORS' CONTRIBUTIONS

All authors contributed to the design of the manuscript and performed literature review from the PubMed database.

STATEMENT OF COMPETING INTERESTS

The authors declare that they have no competing interest associated with this manuscript.

REFERENCES

1. Kirksey, M. A., Haskins, S. C., Cheng, J., Liu, S. S. Local anesthetic peripheral nerve block adjuvants for prolongation of analgesia: A systematic qualitative review. PLoS One. 2015; 10 (9): e0137312.
2. Yektaş, A., Gümüş, F., Alagol, A.

Dexmedetomidine and propofol infusion on sedation characteristics in patients undergoing sciatic nerve block in combination with femoral nerve block via anterior approach. Revista Brasileira De Anestesiologia. 2015; 65 (5): 371-378.
3. Mitra Yari , Morteza Saeb , Parisa Golfam, Zahra Makhloogh Analgesic efficacy of intra-articular morphine after arthroscopic knee surgery in sport injury patients. Journal of Injury and Violence Res. 2013 Jun; 5(2): 84-88.
4. Shehla Shakooh, Pooja Bhosle. Intrathecal Nalbuphine: an effective adjuvant for postoperative analgesia. Innovative Journal of Medical and Health Science 4 : 2 March – April (2014) 79 - 82.
5. Jae-Hwang Song, MD, Chan Kang, MD, Deuk-Soo Hwang, MD, PhD, Jung-Mo Hwang, MD. Fentanyl Patches to Supplement Ultrasound-Guided Nerve Blocks for Improving Pain Control After Foot and Ankle Surgery: A Prospective Study. The Journal of foot and ankle surgery 55 (2016) 121-124.
6. Singh, R., Kundra, S., Gupta, S., Grewal, A., Tewari, A. Effect of clonidine and/or fentanyl in combination with intrathecal bupivacaine for lower limb surgery. Journal of Anesthesiology and Clinical Pharmacology. 2015; 31 (4): 485-490.
7. Albrecht, E., Kern, C., Kirkham, K. R. A systematic review and meta-analysis of perineural dexamethasone for peripheral nerve blocks. Anaesthesia. 2015;70(1): 71-83.
8. De Oliveira, G. S., Castro Alves, L. J., Nader, A., Kendall, M. C., Rahangdale, R., McCarthy, R. J. Perineural Dexamethasone to Improve Postoperative Analgesia with Peripheral Nerve Blocks: A Meta-Analysis of Randomized Controlled Trials. Pain research and treatment. 2014.
9. Huynh, T. M., Marret, E., Bonnet, F. Combination of dexamethasone and local anaesthetic solution in peripheral nerve blocks: A meta-analysis of randomised controlled trials. European journal of Anaesthesiology. 2015;32: 751-758.
10. Schoenmakers, K. P., Fenten, M. G., Louwerens, J. W., Scheffer, G. J., Stienstra, R. The effects of adding epinephrine to ropivacaine for popliteal nerve block on the duration of postoperative analgesia: a randomized controlled study. BMC Anesthesiology. 2015; 15: 100.
11. YaDeau, J. T., Paroli, L., Fields, K. G., Kahn, R. L., LaSala, V. R., Jules-Elysee, K. M., Levine, D. S. Addition of Dexamethasone and Buprenorphine to Bupivacaine Sciatic Nerve Block. Regional anesthesia and pain medicine. 2015; 40(4): 00-00.

A Literature Review of Malignancies Masquerading as Diabetic Ulcers

McKenna Green, BS, Traci Bologna-Jill, BA, Vrunda Dalal, BA, MBS, and Disha Shah, BA

Abstract

Introduction
Diabetes is becoming increasingly prevalent in the United States. About 15-25% of diabetic patients develop ulcers during their lifetime. Many times lesions can masquerade as diabetic ulcers. Due to the complicated nature of treating diabetic wounds, other possible diagnoses for the lesion may be overlooked. This study will explore the appropriate timeline to biopsy an ulcer. Furthermore, it will discuss sites within the lesion to biopsy and evaluate the best techniques used. Complications resulting from misdiagnosis will also be addressed.

Study Design: Qualitative systematic review

Methods
A literature search utilizing Pubmed was conducted. Articles related to the topics of malignancies masquerading as diabetic ulcers were found by using the terms “diabetic ulcer” AND “malignancy”, “chronic diabetic ulcer” AND “biopsy technique”, and “masquerading” AND “ulcer” AND “foot”. Once searched, the abstracts were analyzed and selected based on the inclusion criteria, which were applicable to the foot, diabetes, ulcer, case studies, written in English, and published after the year 2000. The abstracts excluded were articles consisting of the exclusion criteria: non-English, published before 2000, and related to diabetic ulcer infections. The search yielded forty articles and a total of twelve articles were selected.

Results
Twelve case studies were examined in this review. Due to their diabetic status their physician believed that their ulceration was outcome of this disease. Many of the cases reported transformation from a typical diabetic ulcer to malignant ulcer in a span of weeks or a couple of months. The lesions were noted to have irregular margins, mushrooming granulation tissue, hyper granulation, hyperkeratosis, pigmented areas, bleeding, and exudate. Prior to formulating a final diagnosis, the lesions were treated as diabetic ulcers. The treatment protocol lasted anywhere from 2 months to 16 years. The final diagnosis in all the lesions proved to be of malignant origin. Although most were diagnosed within a year, two were noted to have remained for fifteen and sixteen years. Included in the final diagnosis of the suspected diabetic ulcers were: squamous cell carcinoma, basal cell carcinoma, kaposis sarcoma, malignant melanoma, and epithelioid carcinoma.

Conclusion
This literature review of case studies found that an un-healing ulcer lasting two to three months may suggest a different underlying cause. Also, lymph node involvement suggested that earlier biopsy should be utilized to prevent metastasis and improve prognosis. No correlation can be definitively stated based solely on presentation, due to its similarities in clinical presentation to a diabetic ulcer. Those with controlled diabetes, like those reviewed, are less likely to have long standing ulcers. Thus, warranting a reason for a biopsy. It is crucial to recognize the need to biopsy as early as possible in order to lead to a better prognosis. A few different biopsy techniques were utilized in the studies, in which punch biopsy was the most commonly used.

Key Words: Diabetic ulcers, malignant lesions, biopsy

Level of evidence: 4

INTRODUCTION

The human foot is an intricate structure. It has the ability to withstand much use over the decades, along with weight from the entire body.[1] More specifically, the foot and ankle together serve to absorb shock from the ground reacting forces against it.[1] If there is any change in normal structure and function it will lead to deformities and disability.[1] Diabetes is a disease which produces harmful effects from the level of the skin to the bone within. Therefore, the diabetic foot is especially prone to complications, which may lead to deformities because the foot cannot endure the stress. On the skin, it can lead to ulcers, which are very important to correctly diagnose because misdiagnosis can lead to potential limb loss.

In a diabetic foot, multiple pathologies can lead to ulceration, including peripheral neuropathy, peripheral vascular disease, and soft tissue/bone deformity.[1] The ulcer, which develops due to pressure, will commonly be located on the plantar aspect of the foot.[1] Some common areas on the plantar foot are the first metatarsophalangeal joint, lateral aspect of the fifth metatarsal phalangeal joint, and the posterior calcaneus (heel).[1] Before it ulcerates, the skin will undergo hyperkeratosis.[1] Following which the foot will undergo complete loss of epidermis and often portions of the dermis, even down to the subcutaneous fat.[1]

Over time, if not properly diagnosed, the delay in proper treatment leads to further limb threatening complications. The masquerading nature is due to the common clinical features of all ulcer types. [2] Some of the malignancies of the lower extremity discussed in this review are malignant melanoma, squamous cell carcinoma (SCC), epithelioid sarcoma, basal cell carcinoma (BCC), Kaposi's sarcoma, and acral lentiginous melanoma.[2]

Three of the most common skin cancers of the feet are SCC, BCC, and malignant melanoma.[2] SCC is the most common type that develops in the lower extremity.[1,2] Most often, it will stay confined to the skin. However, in its later stages, the cancer does have the tendency to spread.[1,2]

SCC will present as a scaling, indurating, and ulcerating nodule with a history of recurrent cracking or bleeding.[2,3] SCC is not painful, however, it can be pruritic.[3] Occasionally, it will begin as a callus-like lesion.[3] It often bears a resemblance to many other foot lesions: plantar warts, fungal infections, eczema, and ulcers.[2] SCC often arises in areas of actinic keratosis derived from sun exposure. [2,3] SCC often presents in light skinned individuals.

BCC grossly presents itself as a pearly papule with overlying vessels, but can often present as an ulcer with central necrosis.[3] It is normally locally aggressive, however, does not metastasize. BCC is common in sun-exposed areas, thus affecting light skinned individuals more commonly as well. The tendency for it to occur on the foot is minimal, as it is not highly exposed to the sun.[3]

Lastly, malignant melanoma is extremely deadly, and must be detected in its initial stages to prevent metastases.[3] These lesions are usually irregularly bordered with varied pigmentation.[3] It has a radial initial growth phase followed by a vertical growth phase.[3] It is the vertical growth phase which leads to metastasis via the blood vessels and lympathics. It is common in light-skinned people and also results from exposure to the sun.[3]

Although rare, misdiagnosis of malignancies of the lower extremity occur, leading to further complications. Currently no guideline exists for the proper time to investigate a different diagnosis, thus this review investigates different case studies and studies about diabetic wound healing in order

to produce a better indicator and reason to biopsy a suspected non-healing diabetic ulcer.

METHODS

A literature review utilizing PubMed was performed. A few separate searches were performed to identify articles related to the topic of malignancies masked as diabetic ulcers. The Boolean operator "AND" was applied to using the keywords "diabetic ulcer" AND "malignancy",which yielded 22 results, of which 9 were chosen based on the inclusion criteria related to the topic of research. Another search utilizing the keywords "chronic diabetic ulcer" AND "biopsy technique" yielded 8 articles from which 1 was selected. Additionally, "masquerading" AND "ulcer" AND "foot" yielded 10 articles from which 3 were chosen. After each search was performed, the abstracts were read in order to select the most relevant articles based on the inclusion criteria, which included articles applicable to the foot, diabetes, and ulcers. Other inclusion criteria included case reports, articles written in English and published after the year 2000. The articles that were written prior to 2000, non-English translation papers, and diabetic ulcer infections were excluded. After a complete search, 40 articles were found in which a review of the abstracts lead to a final number of 13 articles. This review included case reports of misdiagnosed ulcers revealing specific topics about the time of diagnosis and the biopsy that lead to the correct diagnosis.

RESULTS

Patient Presentation

The age range of patients investigated was from 48-88 years old. The mean age was 68 and the median age was 71. The following information was extracted from the case reports: presentation, pain, lymph node involvement, and duration of ulceration before biopsy, recurrence of ulceration, chronic irritation, and peripheral neuropathy. All of the twelve patients were previously diagnosed with diabetes. Thus the first diagnosis of the ulceration was considered a manifestation of this disease, with the exception of one ulceration misdiagnosed as pyoderma gangrenosum. Six patients had associated peripheral neuropathy. Ten of the ulcers were described as having an atypical presentation. Six of the ulcerations were noted to be atypical at the first doctor-patient encounter. Four of the ulcerations developed into atypical presentations after the initial encounter, and these changes occurred quickly over a few weeks or months. For the ulcers to be classified as atypical, they had irregular margins, mushrooming granulation tissue, hypergranulation, hyperkeratosis, pigmented areas, bleeding, and exudate.

Out of the twelve cases, the two remaining ulcers appeared to be of 'normal' presentation for that of a diabetic ulcer. Four of the ulcers were associated with pain. The most common locations of the lesions were in areas of weight bearing on the plantar foot. Seven ulcers were found under the metatarsal heads or on the heel of the foot, two were found on the dorsum of the foot, one was found in the area of an amputation of the digits, and one was found on the medial surface of the leg Two patients were on immunosuppressive medications, and two were on antibiotics. Two patients had skin grafts to the area of ulceration prior to the diagnosis of malignancy. One patient had a history of osteomyelitis. Finally, one patient had a history of previous malignancy. Specifics can be located in Table 1- Diagnosis and presentation of lesions in diabetic patients.

Hemoglobin Alc (HbAlc) values were noted in three of the cases. A value of 6% is noted as being considered controlled. In case 11, the HbAlc value was noted to be 5.6%. Two other cases, case 8 and 10 were also noted

Ref.	Age of Pt. at Dx	Diagnosis	Biopsy Technique	Lymph Node Involvement	Presentation	Pain
4	48	Malignant Melanoma	Incisional	Yes	Mushrooming granulation tissue irregular	Yes
5	50	SCC	Punch -Ulcer Margins	-	Irregular Margins	-
5	52	SCC	Punch -Ulcer Margins	Yes	Bleeding, Irregular	-
6	54	Malignant Melanoma	Incisional	Yes	Irregular Margins, pigmented macule	-
7	57	Epithelioid Sarcoma	Skin Biopsy	-	Irregular, granulation tissue	-
8	69	Malignant Melanoma	Excisional	Yes	Atypical, hypergranulation	Yes
9	73	SCC	Debridement	-	Discharge - Pus	Yes
10	76	Malignant Melanoma	Punch	Yes	Non-Pigmented, fleshy ulcer, callus - like	-
11	81	Acral Lentiginous Melanoma	Excisional	-	Bleeding, foul smelling drainage, irregular, hyperpigment	Yes
12	83	Kaposi Sarcoma	Incisional	-	Hyperkeratosis mushrooming granulation	-
13	83	BCC	Punch - Central	-	Dry, regular boarders, skin islands	-
14	88	Kaposi Sarcoma	Punch - Superior, Lateral, and Pigmented Region	-	Atypical, hypergranulation, serous exudate, pigmented macules	-

Table 1: Diagnosis and presentation of lesions in diabetic patients.

to be controlled, although no specific level was noted.

Duration of Ulceration

The ulcers appeared anywhere from two months to 16 years prior to diagnosis of malignancy. Two ulcers were found within 2-4 months, two were found within 4-6 months, one ulcer was found within 6-8 months and two were found within 10-12 months. Lastly, two were noted to have remained for 15 and 16 years. These times mentioned above were from when patients presented with the ulcer to when it was determined that they were malignant. The median duration of ulceration before a biopsy was taken was 12 months. Four were reported to have had episodes of recurrence. Specifics can be located in Table 1- Diagnosis and presentation of lesions in diabetic patients.

Biopsy Techniques used for Diagnosis

The final diagnoses were made by biopsy with histopathological analysis. Three cases used the incisional biopsy technique, four used the excisional biopsy technique, and one performed a biopsy of the debridement tissue. Punch biopsy was the most popular method for diagnosing malignancy, however, the location of the biopsy within the lesion

Ref.	Duration of Ulceration	Recurrance of Ulceration	Location of Ulceration	Peripheral Neuropathy	Noteworthy
4	18 months	-	Right plantar 1st met head	-	-
5	3 months	Yes	Left dorsal hallux	-	Skin graft
5	5 months	Yes	Left dorsal hallux	-	Osteomyelitis
6	12 months	-	Right plantar 5th met head	-	Antibiotics
7	16 yearrs	-	Left sole, area of amputation	-	Skin graft
8	12 months	-	Left 1st met head	Yes	-
9	7 months	Yes - 2x	Left heel	Yes	Immuno-suppressives
10	15 years	-	Right plantar 3rd met head	Minimal	Immuno-suppressives
11	6 months	Yes	Right plantar 4th/5th met head	-	-
12	2 months	-	Right plantar 1st met head	Yes	Antibiotics
13	3 years	-	Right leg	Yes	-
14	Unknown, enlarging over weeks	-	Right plantar	Yes	Hx of malignancy, all site HHV

Table 2: Diagnosis and presentation of lesions in diabetic patients.

varied. Three were taken at the ulcer margins, two were central, and one performed multiple biopsies at various sites of the lesion. Specifics can be located in Table 1- Diagnosis and presentation of lesions in diabetic patients.

Final Diagnosis

These cases resulted in the diagnosis of various dermatologic malignancies. Four patients were diagnosed with malignant melanoma, three with SCC, two with Kaposi's Sarcoma, one with BCC, and one with epithelioid sarcoma. Five were positive for inguinal lymph node involvement. Specifics can be located in Table 1- Diagnosis and presentation of lesions in diabetic patients.

DISCUSSION

Presentation

Koo et al., noted the need for a biopsy could be based on 'CUBED': C-Color, U-uncertainty, B-bleeding (including chronic granulation), E- enlargement or worsening, D- delay in healing.[14] This acronym notes delay in healing, which would be applicable to all of these lesions. Bleeding was present in two of the cases.[5,11] Granulation tissue was present in 5 cases.[4,7,8,11,14] These criteria

should be kept in mind when examining an unhealing ulcer in order to correctly diagnose the ulcer.

The presentation of each ulcer varied. There was no specific indicator that overlapped in these cases that raised suspicion of the unhealing ulcer to be caused by a malignancy. Since the occurrence of ulcers in diabetic patients is common, biopsies are rarely performed causing late diagnosis.[11] The Hemoglobin A1c (HbA1c) levels of the patients were noted to be within controlled range. In a study by Christman et al., 310 wounds from diabetic patients at the John Hopkins Wound Clinic were evaluated for healing rate based on the HbA1c levels.[15] Based on their study they found that patients with a HbA1c level of 5.6% healing at a rate of 0.35cm^2 per day, whereas patients with HbA1c levels of 11.1% healed at a rate of 0.001cm^2 per day.[15] Thus, based on the twelve cases reviewed in this paper, the HbA1c levels were reported to be controlled. Specifically case 11 noted a level of 5.6%, which would suggest that the wound should have healed if HbA1c values are good indicators of healing time. The John Hopkin's study noted that the HbAlc levels were more strongly correlated with wounds located on the foot.[15] Gregson et al. and Kong et al. both noted controlled HbAl1c values for patients with the final diagnosis of Malignant melanomes.[8,10] Although a definitive statement of HbAlc levels and healing time cannot be stated based solely on one study, this seems to be a promising indicator of a reason to biopsy.

Timeline

The presentation of the ulcers alone was not definitive to determine a diagnosis. A timeline provides a better marker to determine if the ulcer requires a different diagnosis and evaluation leading to a biopsy. Each case was compiled and compared to a research study presenting proper healing times of ulcers to create an appropriate timeline for the physician to obtain a biopsy. When a diabetic patient presents with an ulcer, the likely diagnosis is a diabetic ulcer and thus treated as such. Since diabetic ulcers are generally slower healing than non-diabetic ulcers, the appropriate time to biopsy the ulcer is unclear. Biopsying non-healing ulcers or partially healed ulcers in diabetic patients is controversial because the tendency to heal is already compromised, thus increased injury to the area could possibly worsen the ulcer. A study by Stefan Zimy, et al. studied the healing time of diabetic ulcers, which found a 95% confidence interval of 62-93 days in which neuropathic foot ulcers healed. This timeline of healing wounds is also supported by Christman's study, in which the healing time was 64 days.[15] This time interval provides the physician with a rough guideline for when to consider another diagnosis for a patient who has presented with a non-healing ulcer.[16] Based on the twelve case reports reviewed, the median amount of time the ulcer existed before biopsy was performed was twelve months. Five cases had lymph node involvement, suggesting that the ulcer had time to metastasize. The specific cases that had lymph node involvement included 3, 5, 6 7, and 18 months before biopsy was performed. Because metastasis occurred as early as three months (90 days) from the development of the ulceration, a more aggressive approach should be taken. This suggests that the earlier the biopsy is performed the better the outcome will be. Thus even if the patient is diabetic, performing a biopsy earlier will make sure the proper diagnosis was made to prevent sequelae of the malignancy. The three month maker is longer than the 62 days stated in Zimy et al.'s study, therefore a biopsy done once the ulcer has lasted past suspected healing could be a cause for a differential diagnosis. Kong et al. suggested early biopsy was indicated if neuropathy or ischemia was not present, if the ulcer had an atypical localization, or if it was painful/ pigmented.[8] These criteria may suggest the

diabetes is not the cause of the ulcer, since these are usual signs in long term diabetes.

Biopsy Techniques

The twelve cases reviewed utilized various different techniques to biopsy the ulcer. It was crucial to biopsy the wound and then follow-up with a proper treatment plan. The three techniques used were incisional, excisional, and punch biopsy.

A punch biopsy is usually reserved for neoplasms, vesicles and inflammatory disorders.[17] Normally a 4-6 mm disposable punch is applied to the skin. In five cases punch biopsy was performed with varying locations within the ulcer. In this review, punch biopsy was the utilized the most. The possible reason for the punch biopsy as the most common may be due to its ability to include deeper lesions, but does not require complete removal. In the case of a diabetic ulcer the least amount of tissue removed will benefit the compromised patient.

Excisional biopsy is when the lesion is completely excised with a margin of unaffected skin as well.[17] Excision biopsy was performed in two cases.[8,11] It is possible that this is utilized the least due to the chance the lesion is in fact a diabetic ulcer, which would lead to further complications in healing the already unhealed ulcer.

Incisional biopsy is similar, however it does not remove the entire lesion.[17] This technique was utilized in three cases.[4,6,12] Since this is similar to the excisional biopsy but less invasive, this is a good alternative for the diabetic patient to get a proper sample to diagnose correctly.

Two cases biopsied at the margins, one central, and another utilized three locations within the ulcer. The cases that took the biopsy at the margins both had irregular margins, which may have been a deciding factor in including the margins in the punch biopsy.[5] The central punch biopsy noted having regular margins, thus this may have lead to the decision to take the biopsy from the center.[13] Schnirring-Judge et al, recommended obtaining a biopsy from the proximal edge of the wound that includes the pathological ulcer and the normal tissue adjacent and also a second specimen from of the full thickness of the tissue from the center.[13]

The ambiguity in these ulcers complicate the ability to know exactly which biopsy and location to utilize, however, the chart demonstrates that biopsy is critical to the make a correct diagnosis.

CONCLUSION

After reviewing different case reports, it showed the ambiguity in treatment of diabetic ulcers. Ultimately, a timeline and Hemoglobin A1c values seemed to be the most promising link in masquerading ulcers. It is pertinent for podiatrists to be aware of the differential diagnosis and to treat each ulcer appropriately.

Our research was limited because currently only case studies present malignancies masquerading as diabetic ulcers. For ulcers that have mostly healed, doctors are apprehensive to biopsy due to difficulty in healing in the first place, thus this is an area for future research to determine when to biopsy suspected ulcers in diabetic patients.

AUTHORS' CONTRIBUTIONS

Four authors contributed equally to the finished literature review. All took part in developing a topic and subsequently performing the tasks to complete the paper, such as the initial literature search, evaluation of abstracts, and contribution to the abstract, introduction, results, discussion, and conclusion. The final paper was evaluated and agreed upon by all authors.

STATEMENT OF COMPETING INTERESTS

The authors declare that they have no competing interests associated with the manuscript.

REFERENCES

1. Kim, Paul, and John Steinberg. "Complications Of The Diabetic Foot". *Endocrinology and metabolism clinics*. N.p., 2013. Web. 22 Dec. 2015.
2. apma.org,. "Skin Cancers Of The Feet, Foot Health, Learn About Feet, APMA". Web.
3. Rubin, Emanuel, and Howard M. Reisner. *Essentials of Rubin's Pathology*. 6th ed. Philadelphia: Wolters Kluwer Health/ Lippincott Williams & Wilkins, 2009. Print.
4. Rogers, Lee C., David G. Armstrong, Andrew J.M Boulton, et al. "Malignant Melanoma Misdiagnosed as a Diabetic Foot Ulcer." *Diabetes Care* 30.2 (2007): 444-45. Web.
5. Panda, S., Seema Khanna,S. K. Singh, Gupta, SK. "Squamous Cell Carcinoma Developing in a Diabetic Foot Ulcer." *The International Journal of Lower Extremity Wounds* 10 (2011): 101-03. Web.
6. Torres, T., A. Rosmaninho, and M. Caetano. "Malignant Melanoma Misdiagnosed as a Diabetic Foot Ulcer." *Diabetic Medicine* 27.11 (2010): 1302-303. Web.
7. Nishimura, Y., Y. Yamaguchi, Y. Tomita, K. Hamada[4], A. Maeda[2], A. Morita[2]andI. Katayama."Epithelioid Sarcoma on the Foot Masquerading as an Intractable Wound for 18 Years." *Clinical and Experimental Dermatology* 35.3 (2009): 263-68. Apr. 2010. Web.
8. Kong, Marie-France, Rajesh Jogia, and Stephen Jackson. "Malignant Melanoma Presenting as a Foot Ulcer." *The Lancet* 366 (2005): 1750. Web.
9. Kong, Marie-France, Rajesh Jogia, and Stephen Jackson. "Squamous Cell Carcinoma in a Heel Ulcer in a Patient with Diabetes." *Diabetes Care* 31.7 (2008): E57. Web.
10. Gregson, C. L., and T. J. Allain. "Amelanotic Malignant Melanoma Disguised as a Diabetic Foot Ulcer." *Diabetic Medicine* 21.8 (2004): 924-27. Web.
11.Thomas, Susan, Yuan-Xiang Meng, Vijaykumar G. Patel, Strayhorn, G. "A Rare Form of Melanoma Masquerading as a Diabetic Foot Ulcer: A Case Report." *Case Reports in Endocrinology* 2012 (2012). Web.
12. Caminiti, MD, M., G. Glericic, MD, and A. Wuarantiello, MD. "Kaposi's Sarcoma Misdiagnosed as a Diabetic Plantar Foot Ulcer." *The International Journal of Lower Extremity Wounds* 8.2 (2009): 120-22. Web.
13.Schnirring-Judge, Molly, and Drew Belpedio. "Malignant Transformation of a Chronic Venous Stasis Ulcer to Basal Cell Carcinoma in a Diabetic Patient: Case Study and Review of the Pahtophysiology." *The Journal of Foot and Ankle Surgery* 49.1 (2010): 75-79. Web.
14. Koo, E., A. Walsh, and H. Dickson. "Red Flags and Alarm Bells: An Atypical Lesion Masquerading as a Diabetic Foot Ulcer." *Journal of Wound Care J Wound Care* 21.11 (2012): 550-52. Web.
15. Christman AL, Selvin E, Margolis DJ, Lazarus GS, Garza LA. Hemoglobin A1c is a Predictor of Healing Rate In Diabetic Wounds. *The Journal of investigative dermatology*. 2011;131(10):2121-2127. Web.
16. Zimy, Stefan, Helmut Schatz, and Martin Pfohl. "Determinants and Estimation of Healing times in Diabetic Foot Ulcers." *Journal of Diabetes and Its Complications* 16.5 (2002): 327-32. Web.
17. Vlahovic, Tracey C., DPM, FAPWCA. "A Guide To Biopsy Techniques For Skin Neoplasms." *A Guide To Biopsy Techniques For Skin Neoplasms*. Podiatry Today, Volume 22 Issue 5 May 2005. Web.

A Qualitative Review of Surgical Interventions in the Treatment of Jones Fractures: Comparison of Intramedullary Screw Fixation and External Fixation

Kevin Yee, BA, Brittany Hervey, BS, and Sang Hyub Kim, BA

Abstract

Introduction
The purpose of this study is to evaluate surgical interventions for Jones fractures of the fifth metatarsal at the metaphyseal-diaphyseal junction. Due to the anatomy and limited vascular supply in this specific area of injury, optimal treatment is still a topic of debate. In this review, the clinical and radiographic outcomes of intramedullary screw fixation and external fixation techniques were compared.

Study Design: Qualitative Systemic Review of the Literature

Methods
An English language literature search was performed using PubMed, with the term “Jones Fracture AND internal AND fixation” and another search as “Jones fracture AND external fixation”. The inclusion criteria included human subjects with Jones fracture involving surgical procedures. Exclusion criteria were 5th metatarsal avulsion and mid-shaft stress fracture, conservative management, cadaveric studies, non-English articles, and articles published prior to 2000.

Results
The search yielded 75 articles and 7 articles satisfied the criteria and were selected for a systematic review.

Conclusion
While internal screw fixation is the most widely accepted treatment for correction of Jones fractures, the procedure is debatable within the surgical community. Although intramedullary screw fixation yields satisfactory union rates and quick healing time, it is not without complications, which range from iatrogenic bone fracture to pain associated with screw placement. In this review, we present external fixation as an innovative alternative to a more commonly used internal approach. External fixation provides comparable radiographic and clinical healing times to that of internal fixation techniques while being relatively uncomplicated and yielding similar results.

Keywords: Jones fracture, 5th metatarsal injury, surgical intervention

Level of Evidence: 4

INTRODUCTION

Fractures of the fifth metatarsal are the most common type of metatarsal fractures seen in adults and children over 5 years of age.[1] Approximately 45-70% of all metatarsal fractures involve the fifth metatarsal.[1] Both proximal avulsion fracture and Jones fracture are related to the fifth metatarsal. The avulsion fracture involves the tuberosity of the fifth metatarsal. In contrast, Jones fracture occurs 1.5 to 3.0 mm distal to the tuberosity at the metaphyseal-diaphyseal junction.[2] Jones fracture is less common than other fifth metatarsal fractures, but is discussed extensively due to a lack of consensus on proper management and treatment.

Naming of the fracture can be attributed to Sir Robert Jones, who first described an acute fracture of the fifth metatarsal base in 1902 after sustaining the injury while dancing around a military pole.[3] A Jones fracture usually results from a vertical or mediolateral force on the base of the metatarsal of the plantarflexed foot when abnormal weight is placed laterally on the foot.[4] Additionally, a hindfoot varus has been implicated in overloading the lateral column of the foot leading to the development of the fracture, as well as potential refracture.[5] The proximal section of fifth metatarsal is a watershed region, resulting in high rates of delayed union or non-union subsequent to fracture. This watershed or avascular region as well as the damage of nutrient arteries may further delay the healing process, which is indicated by prolonged time to union, high delayed union and nonunion rates.[6]

The Torg classification divides Jones fracture into three types based on radiological appearance and healing potential.[3] Type I fractures are described as acute fractures with no intramedullary sclerosis, a fracture line with sharp margins, no widening or radiolucency, and minimal cortical hypertrophy. Type II fractures are described as delayed unions with a fracture line that involves both cortices with associated periosteal new bone, a widened fracture line with adjacent radiolucency related to bone resorption, and evidence of intramedullary sclerosis. Type III fractures are described as nonunions with a wide fracture line with periosteal new bone and radiolucency and complete obliteration of the medullary canal at the fracture site by sclerotic bone.[7] Depending on the type of fracture, treatment is adjusted accordingly. Torg et al. recommended conservative treatment without weight bearing for Type I fractures for a period of 3-12 weeks. Type II fractures may eventually heal with conservative treatment, but an active athlete will benefit from surgical treatment, as will type III fractures.[1]

Torg et al. advocated treating acute Jones fracture with non-weight-bearing immobilization, but many authors have reported disappointing results with conservative treatment.[8] Conservative treatment is typically reserved for those with low physical activity levels or medical comorbidities that preclude surgery. It consists of 6 to 8 weeks of cast immobilization and non-weight-bearing, followed by an additional 6 weeks of cast immobilization with full weight-bearing.[2] Many studies have demonstrated higher incidences of refracture and delayed healing associated with conservative or nonoperative treatment in comparison to surgical treatments. These complications are partly contributed to the anatomy and vasculature of the fifth metatarsal. Jones fractures are notorious for a high incidence of delayed union and nonunion, in part because the peroneus brevis and the lateral band of the plantar aponeurosis cause motion at the fracture site, despite cast immobilization.[2]

Surgical operation is highly recommended for Jones fracture, especially in athletes, young patients and high activity individuals. The most common operation is the intramedullary screw fixation. In a study comparing cast immobilization and screw fixation, Fernandez Fairen et al. found that only 50% of those

treated with immobilization healed after 12 weeks, and those treated with screw fixation healed within 9.5 weeks.[2]

There are variations in size, length and type of screws utilized in the intramedullary screw fixation. Some studies indicate that cannulated screws may allow easier insertion with less risk of malplacement as compared with conventional non-cannulated screws.[9] Other modified procedures such as the revision intramedullary screw fixation use cancellous autologous bone grafting or bone-marrow aspirate combined with demineralized bone matrix.[10] In addition, intramedullary screw fixation can be enhanced with fluoroscopic image intensification to allow visualization of the site of insertion and therefore guide the intramedullary screw.[10] Despite these diverse intramedullary screw fixation methods, there is no consensus on what should be used to obtain optimal results.

External fixation is used as an alternative to internal fixation for Jones fracture. Historically, external fixation has been implemented most commonly for fractures involving comminuted, infected or osteoporotic bone or for injuries with large soft-tissue defects. The device provides axial compression and stability across a fracture site, is quickly and easily applied, and avoids complications associated with surgical dissection and screw placement.[8] The potential advantage of external fixation over intramedullary screw fixation was that after treatment no hardware remained in foot. The relatively easy application is associated with lower complications inherent to screw implantation, good axial compression, and stability of the fracture. Most importantly, external fixation promotes earlier mobilization and return to competitive sports.[4]

METHODS

Two English language literature searches were performed using the PubMed database. The search was performed using the “AND” Boolean operator. The first search included the terms “Jones Fracture” AND “Internal” AND “Fixation”, which yielded 31 articles. The second search included the terms “Jones Fracture” AND “External Fixation”, which yielded 44 articles. Overall, the two searches resulted in 75 total articles. The inclusion criteria consisted of human subjects with Jones fractures that needed surgical intervention. Exclusion criteria were 5th metatarsal avulsion and mid-shaft stress fracture, conservative management, cadaveric studies, non-English articles, and articles published prior to 2000. After evaluating and screening the papers using the inclusion and exclusion criteria mentioned above, 7 papers matched the criteria and were analyzed. The search methods have been summarized in Figure 1.

RESULTS

After evaluating and screening 75 papers, 7 papers satisfied the criteria. Out of the 7 papers, 5 papers pertained to clinical studies of different treatments and were further analyzed for a qualitative review. Three papers were about internal screw fixation and two papers analyzed external fixation for Jones fracture.

Screw fixation

Nagao et al. studied the use of headless compression screw fixation in athletes with Jones fractures.[7] The study included 60 athletes from Japan, average age of 19 years (range from 15-31 years), and evaluated heal time, in addition to clinical and radiological outcomes. An average of 6.3 weeks (range 3-12.7 weeks) was reported for athletes to

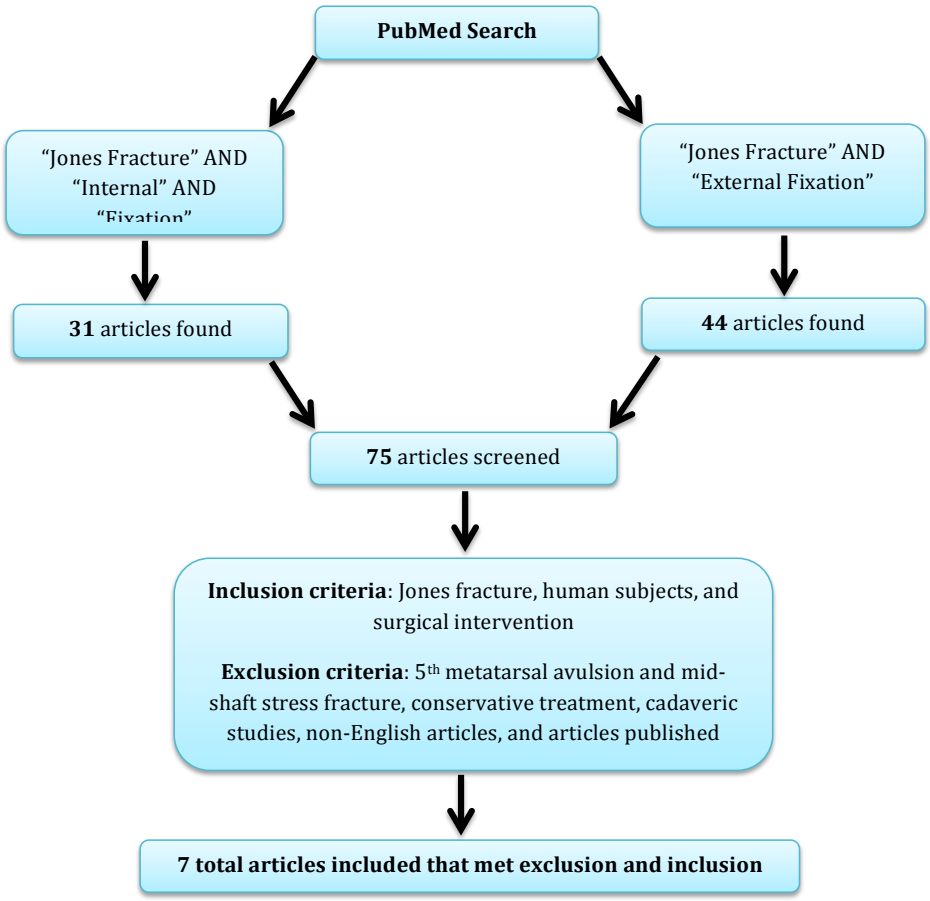

Figure 1: Acquisition of articles from PubMed based on inclusion and exclusion criteria (5 articles were selected)

run after surgery and 11.2 weeks (range 6-25 weeks) in order to see full activity after surgery. The authors stated that the headless screw design allowed patients to "return to full activity with minimal risk of soft tissue impingement". There were no reports of screw head irritation in this study. In contrast, Mologne et al. reported that screw head irritation occurred in 32% of patients that underwent cannulated screw fixation.[11]

Due to the location of the fracture and the osseous anatomy of the 5th metatarsal, surgically corrected Jones fractures by screw fixation are prone to nonunions and refracture. Hunt et al. conducted a case series on 21 athletes, average age of 28.4 years (range from 15-50 years), who suffer from nonunion and refracture of their Jones fractures.[10] The patients underwent revisional intramedullary screw fixation with a larger diameter screw combined with autologous bone graft or bone-marrow aspirate (BMA) + demineralized bone matrix (DBM). The average time it took to return to sport was 12.3 ± 2.6 weeks (range from 6-16 weeks) and at that time there no pain or tenderness was reported. It was concluded that the type of bone graft used did not have a significant effect on the time it took to return to sports (11.5 ± 2.7 weeks for BMA + DBM, 13.0 ± 2.1 weeks for iliac crest bone graft; $p > .05$). The union rate reported at the 4th month follow up was 100% and showed complete cortical healing in radiographs. The authors recommend using a larger diameter screw along with autologous bone graft when performing a revisional intramedullary screw

	Intramedullary Screw Fixation			External fixation	
	Charlotte Carolina screw vs. traditional solid screw	**Headless Compression Screw Fixation**	**Intramedullary Screw fixation with Bone Grafting**	**Ilizarov External Minifixator**	**DFS MiniFixator System**
Authors	Metzl et al.	Nagao et al.	Hunt et al.	Tomic et al.	Lombardi et al.
Sample size	47 patients	60 patients	21 patients	6 patients	10 patients
Sex	N/A	59 males 1 female	16 males 5 females	6 males	9 males 1 female
Mean age	43.8 years	19 years	28.4 years	20.3 years	25.2 years
Average healing time	N/A	6.3 weeks (11.2 weeks average return to activity)	12.3 weeks (average return to sports); 11.5 weeks (BMA+DBM); 13 weeks (iliac crest autologous bone graft)	4.1 weeks (clinical healing); 6.7 weeks (average return to full athletic activity)	5.7 weeks (clinical healing); 9 weeks (return to pre-injury activity levels)
Average follow-up time	37 months	178 weeks (~44.5 months)	29 months	48 months	46 months
Complications	2 cases of radiographic nonunion in traditional solid screw group, both experienced hardware failure	One suffered a delayed union and suffered a non-union	1 patient suffered a refracture	Two patients had minor complication of pin tract irritation and infection	3 cases of postoperative complications: refracture, asymptomatic nonunion, and cellulitis

Table 1: Summary of Studies and Results

fixation.

External fixation

Tomic et al. treated 6 athletes, with an average age of 20.3 years (range 18 to 24), with the Ilizarov External Minifixator, an external fixator used in this case series for Jones fractures.[4] Clinical healing with external fixation was seen at 4.1 (range 4.0 to 4.2) weeks and athletes returned to full activity at 6.7 (range 6.4 to 6.9) weeks. The authors stated that the use of external fixation was minimally invasive, allows for patient individualization, excellent stability and compression, earlier weight-bearing after surgery, and does not damage the metatarsal bone, vascularization, or soft tissue.

Lombardi et al. also used external fixation in 10 patients with acute Jones fractures.[8] The average age of the patients was 25.2 years (range from 15-49 years). The study included 9 patients that played sports or did long-distance running, the 10th patient spent a lot of time on his feet for his occupation and requested a quicker return to weightbearing. The clinical healing time was 5.7 ± 1.7 weeks, there was a case of nonunion that exhibited consolidation radiographically at 6.5 weeks. At 9 ± 1.3 weeks, patients were ready to function as they did prior to injury. It was noted that patients that underwent external fixation were quicker to return to activity than casting immobilization. The authors were confident in the device and decided to do an early removal at the 4th week instead of the 6th. The results of these studies are included in Table 1.

DISCUSSION

Comparison of Traditional Solid Screw vs. Indication-Specific Screw for Intramedullary Fixation of Jones Fracture

While there remains no consensus in the surgical community as to the ideal treatment of Jones fractures, internal fixation of the fracture through placement of an intramedullary screw remains a common treatment modality. Unlike non-operative treatment which is accompanied by prolonged healing time, intramedullary screw fixation is a common surgical alternative offering expedited healing, return to play, decreased nonunion rates and prevention of refracture.[3] Until the development of the Charlotte Carolina Jones Fracture System (Wright Medical Technology, Arlington, TN), there existed no screw specifically designed for the operative treatment of Jones fractures and thus a wide variety of screw types and sizes were utilized.[3]

A retrospective comparative series conducted by Metzl at el. compared the clinical and radiographic results of patients treated with the indication specific screw to those of a group treated with a traditional solid screw. Group I consisted of twenty-six patients treated with the Carolina Jones Fracture System, or “indication specific screw,” while the patients in Group II each received a traditional solid screw. According to Metzl et al., there was no statistically significant difference between the two groups with regard to clinical outcomes. Further, there were no statistically significant differences between the indication-specific screw group and the traditional solid screw group in clinical assessments such as limitations in activity, shoe-wear modification, recovery time, satisfaction or willingness to repeat the surgery.[3]

While the outcomes appear to be somewhat equivalent in both groups, it was noted that all adverse events in the study occurred in the traditional screw group within two months of surgery. Group II experienced significantly more adverse events than group I, including two cases of radiographic non-union which both resulted in hardware failure, one intraoperative fracture and one case of symptomatic hardware. [3] Although both groups achieved radiographic union above 95%, there was a higher incidence of

adverse events such as refracture in the traditional group. It can be concluded that the indication-specific screw for intramedullary fixation of acute Jones fractures has excellent clinical outcomes with low complication rates and should be highly considered when postoperative refracture is likely.[3]

Comparison of Indication-Specific Screw vs Headless Compression Screw Fixation of Jones Fractures

Differences in lifestyle activity among various groups of patients often have great influence on their surgical treatment options. In the vast spectrum of treatment modalities for Jones fractures, competitive athletes and those with active lifestyles are often given different consideration than non-athletes.[4] Nagao et al. were interested in studying sixty Japanese athletes that received headless compression screw fixation of proximal fifth metatarsal Jones fractures.[7] According to Nagao et al, there are inherent morbidities associated with intramedullary screw placement, especially in competitive athletes.[7] Screw head discomfort and refracture after bone union are common side effects of internal fixation with both traditional and indication-specific screws. Nagao et al. hypothesized that with the use of a headless screw the incidence of insertion site complications would be reduced. Thus, the study evaluated the clinical and radiographic outcomes of the Acutrak Headless Compression Screw (Acumed Inc, Beaverton, Oregon) for internal fixation of Jones fracture.

In a direct comparison of sheer strength, as reported by Nunley and Glission, the Carolina Jones Fracture System screw was shown to be superior to Acturak screws in fatigue tests.[12] Based on this raw data, it would appear that the Carolina screw would be a more robust hardware option for internal fixation of Jones fracture.[12] Nagao et al, however, reported no screw breakage in long-term follow up with patients treated with the Acutrak headless screw. Additionally, they were able to avoid irritation at the screw insertion site commonly experienced with placement of the Carolina screw. This study suggests that fixation of Jones fractures with a headless compression screw allows athletes to return to full activity with minimal risk of soft tissue damage. The study also concludes that the Carolina screw is appropriate for use in primary fractures while functioning to prevent clinical refracture following bone union.[7]

Use of Autologous Grafting in Revision Intramedullary Screw Fixation of Jones Refractures and Nonunions

Refracture and nonunion are unfortunate unwanted outcomes of initial surgical fixation of Jones fractures. In either case, revision procedures are necessary to achieve bone healing. Revision procedures commonly require the removal of previous hardware, debridement of the nonunion, fixation with a larger diameter screw and autologous and/or allogeneic bone grafting.[10] Hunt et al. performed a retrospective chart review of 21 elite athletes who underwent revision operations with autologous grafting for Jones fracture nonunions.[10] Several autograft methods were used including iliac crest cancellous bone graft (8 patients), bone marrow aspirate (BMA) plus demineralized bone matrix (DBM) (8 patients), calcaneal bone graft (4 patients) and DBM alone (1 patient). Postoperatively, all patients underwent physical examinations and serial radiographs until full radiographic healing was achieved. Hunt et al defined “radiographic healing” as complete healing of all four cortices and “clinical healing” as no tenderness to palpation and restoration of foot function.[10]

The results of the study by Hunt et al. revealed that the type of autologous bone grafting used did not significantly influence the average time to return to sport. All of the athletes in the study achieved complete

cortical healing and were able to return to their pre-injury levels of physical activity. Furthermore, all participants had complete resolution of pain before returning to their chosen sport.[10] Given the 100% union rate at four month follow up achieved in this study, Hunt et al. determined that a revision procedure utilizing autologous bone grafting is an excellent treatment option for Jones nonunions.

Comparison of the DFS Minifixator System vs. the Ilizarov External Minifixator in the External Fixation of Jones Fractures

A systematic review of the literature yielded only two published studies on the external fixation of Jones fractures that satisfied our inclusion criteria. One study by Lombardi et al presented a retrospective analysis of ten patients treated with the DFS Minifixator system. In a more recent study, a retrospective case series of six patients, Tomic et al evaluated the use of the Ilizarov External Minifixator. The authors of both studies opted for external fixation techniques instead of the widely accepted internal fixation methods discussed previously. Lombardi et al discussed intraoperative challenges presented by open reduction and internal fixation such as "disruption of tendinous attachments, screw breakage, and inadequate countersinking with subsequent soft-tissue irritation."[8] The authors were equally concerned with potential violation of the medial cortex of the metatarsal with placement of an intramedullary screw. They note that the use of larger diameter screws, especially in patients with prominent lateral bowing of the fifth metatarsal, are predisposing factors to aforementioned adverse events.[8] In the study by Tomic et al, the authors were mainly concerned with postoperative complications such as failure after screw fixation, particularly in the elite athlete.[4] They concluded that the standard method of internal fixation may not be the ideal treatment option for those requiring swift return to vigorous activity such as elite athletes.[4]

The study by Lombardi et al was a clinical investigation of patients having undergone external fixation with the DFS Minifixator system under fluoroscopic guidance. Surgical candidates were all under the age of thirty-five and led active lives that necessitated rapid recovery.[8] The lengths of time until clinical and radiographic healing were assessed. Lombardi et al defined clinical healing as "an absence of pinpoint tenderness on palpation of the fracture site and the patient's ability to bear weight on the involved extremity without discomfort."[8]. Radiographic healing was defined as "full trabeculation and consolidation across the fracture site on both the anteroposterior and lateral views."[8] On average, patients achieved clinical healing in 5.7 weeks and returned to pre-injury activity levels at 9 ± 1.3 weeks postoperatively.[8] At 46 month follow up by telephone, all patients relayed that they had maintained their pre-injury activity levels without episodes of pain or recurrence of injury.[8] Three patients in the study experienced complications; one case of cellulitis localized to one pin site of the apparatus, one nonunion and one refracture in a pregnant female patient.[8] The isolated case of cellulitis healed quickly upon pin removal and administration of antibiotics. A review of the postoperative radiographs of the nonunion revealed that one pin was in close proximity to the fracture site, generating a distraction force that interfered with healing.[8] Finally, the case of refracture at 3 months postoperatively was attributed to bone mass changes and increased stress on the metatarsals brought upon by pregnancy.[8]

In 2013, Tomic et al evaluated the efficacy of the Ilizarov External Minifixator as a surgical treatment of acute Jones fractures in 6 elite male athletes. Evaluation parameters included clinical and radiographic healing intervals as well as time to return to full activity. Tomic et al found the mean time from surgery to clinical healing to be 4.1 weeks and the interval to radiographic consolidation

of the fracture to be 5.8 weeks.[4] The authors reported an average interval of 6.7 weeks to return to full athletic activity.[4] There were no major complications reported via telephone inquiry at 48 months postoperatively. Furthermore, all participants reported a full return to pre-injury activity levels and satisfaction with treatment results. The authors reported no cases of refracture of the operative site.[4] Two patients experienced minor pin tract irritation and infection of a single pin that healed uneventfully with antibiotic administration and pin removal.[4] The intervals of return to physical activity reported by Tomic and Lombardi, 6.7 weeks and 9 weeks respectively, were substantially less than those achieved in the studies utilizing internal screw fixation. Nagao et al achieved an average return to full activity of 11.2 weeks with headless compression screw fixation, while Hunt et al reported an average of 12.3 weeks using intramedullary fixation with autologous bone grafting. Therefore, external fixation is a viable surgical option for those highly active patients whose lives demand early return to physical activity.

CONCLUSION

The Jones fracture is a common fifth metatarsal pathology that often requires surgical intervention. While intramedullary screw fixation has been the mainstay of treatment, our literature research suggests numerous advantages of external fixation over the traditional method. The use of external fixation devices such as the DFS Minifixator and the Ilizarov External Minifixator systems yields earlier return to physical activity. Furthermore, patients who received external fixation treatment were able to fully return to pre-injury activity levels. Thus, external fixation of Jones fractures yields clinical and radiographic results similar to, if not superior to those of intramedullary screw fixation.

External fixation of Jones fractures appears to be a promising treatment modality, however there are several limitations to our research. The articles that support this conclusion are retrospective in nature and contain small sample sizes. Additionally, both studies analyzed narrow sample populations consisting of elite athletes only. Therefore, further studies with larger and broader sample populations are necessary to determine the efficacy of external fixation for the treatment of Jones fractures.

AUTHORS' CONTRIBUTIONS

All authors participated equally in conception of the research topic, literature review, and extraction of data. SHK drafted the introduction. KY drafted the methods and results. BH drafted the discussion and conclusion. All authors drafted, reviewed, and agreed upon the manuscript.

STATEMENT OF COMPETING INTERESTS

The authors declare that they have no competing interest.

REFERENCES

1. Zwitser, E.W., Breederveld, R.S. Fracture of the fifth metatarsal; diagnosis and treatment. *Injury*. 2010; 41:555-562.
2. Mendicino, R.W., Hentges, M.J., Mendicino, M.R., Catanzariti, A.R. Technical Considerations for Surgical Intervention of Jones Fracture. 2013; 52 (3): 409-414.
3. Metzl, J., Olson, K., Davis, W.H., Jones, C., Cohen, B., Anderson, R. A clinical and radiographic comparison of two hardware systems used to treat jones fracture. 2013; 34 (7): 956-961.
4. Tomic, S., Vucic, V., Dobric, M., Bisignani, G. Treatment of Acute Jones Fracture with Ilizarov External Minifixator: Case Series of Six Elite Athletes, Journal of Foot & Ankle Surgery. 2013; 52(3): 374-379.
5. DeVries, JG., Cuttica, DJ., Hyer, CF. Cannulated screw fixation of Jones fifth

metatarsal fractures: a comparison of titanium and stainless steel screw fixation. J Foot Ankle Surg. 2011; 50:207-12.
6. Yates. J., Feeley, I., Sasikumar, S., Rattan, G., Hannigan, A., Sheehan, Eoin. Jones fractures of the fifth metatarsal: is operative intervention justified? A systematic review of the literature and meta-analysis of results. The Foot (Edinburg, Scotland). 2015; doi: 10.1016/j.foot.2015.08.001.
7. Nagao, M., Saita, Y., Kameda, S. et al. Headless compression screw fixation of jones fractures: an outcomes study in Japanese athletes. *Am J Sports Med*. 2012; 40:2578–2582.
8. Lombardi, C.M., Connolly, F.G., Silhanek, A.D. The use of external fixation for treatment of the acute Jones fracture: a retrospective review of 10 cases. *J Foot Ankle Surg*. 2004; 43: 173–178.
9. Reese, K., Litsky, A., Kaeding, C., Pedroza, A., Shah, N. Cannulated screw fixation of Jones fractures: a clinical and biomechanical study. *Am J Sports Med*. 2004; 32: 1736-1742.
10. Hunt, K.J., Anderson, R.B. Treatment of Jones fracture nonunions and refractures in the elite athlete: outcomes of intramedullary screw fixation with bone grafting. *Am J Sports Med.* 2011; 39 (9): 1948-1954.
11. Mologne, T.S., Lundeen, J.M., Clapper, M.F., O'Brien, T.J. Early screw fixation versus casting in the treatment of acute Jones Fractures. *Am J Sports Med*. 2005; 33 (7): 970-975.

12. Nunley, J.A., Glisson, R.R. A new option for intramedullary fixation of Jones fractures: the Charlotte Carolina Jones fracture system. Foot Ankle Int. 2008; 29 (12): 1216-21.

The Advantages of Dermoscopy in the diagnosis of Acral Melanoma from other Podiatric Lesions: A Literature Review

HyunJi Boo, BS, Suganthi Khandasamy, BA, MPH, Dhagash Patel, BA, BS, and Mansi Patel, BA

ABSTRACT

Introduction
Melanoma is one of the most common primary malignant tumors arising in the lower extremity. Even though improvements have been seen in the prognosis for some patients with melanoma, pedal lesions remain a major issue. It is crucial to diagnose melanoma as quickly and as efficiently as possible for a better prognosis. The use of dermoscopy is helpful in diagnosing such conditions. Dermoscopy is a non-invasive, in-vivo technique primarily used in the examination of pigmented skin lesions. This procedure allows the visualization of subsurface skin structures in the epidermis, dermoepidermal junction, and upper dermis - structures not visible to the naked eye. This paper describes the advantages of dermoscopy in the field of podiatry by assessing all the dermoscopic criteria that ensure a positive predictive value of diagnosing an acral melanoma from an acral nevus through a literature review. Additionally it analyzes cases of melanomas misdiagnosed as a plantar-pigmented wart and a diabetic ulcer.

Study Design: Qualitative Systematic Review of the Literature

Methods
The authors used PubMed to perform an English language literature search. The first search included the terms “Dermoscopy” AND “foot lesions” AND “melanoma”. This search provided 18 articles. The second search included the terms “Dermoscopy” OR “nevus” AND “foot lesions”. This search provided 111 articles. The third search included the terms “Dermoscopy” AND “foot lesion” AND “histopathology”. This search provided 12 articles. Each contributor examined 35 abstracts and determined whether the papers met the criteria. After applying the inclusion and exclusion criteria, first search yielded 3 articles, second search yielded 5 articles, and third search yielded 2 articles. Overall, 10 total articles were found.

Results
Although the presence of parallel ridge patterns (PRP) has been the dermoscopic standard for the diagnosis of a melanoma, cases of melanomas without PRP have been encountered. Further evaluation of pigmented pedal lesions with a dermatoscope helped improve the accuracy of the diagnosis of a melanoma. Additionally it helped narrow down dermoscopic patterns that ensure a positive predictive value of diagnosing an acral melanoma from an acral nevus.

Conclusion
The use of dermoscopy is slowly evolving in podiatry as it aims to minimize the amount of biopsies taken, thereby decreasing the risk of creating an ulcer as well as reducing the patient’s exposure to anesthesia. While controversy remains over sensitivity and specificity of using a dermatoscope alone to diagnose pedal lesions, particular attention should be paid to the accuracy of diagnosing a lesion when dermoscopy is used in conjunction with a biopsy. With the continued usage of a dermatoscope along with experience and expertise in the field, the need for a biopsy can eventually be eliminated.

Keywords: Dermoscopy, Melanoma, Pedal lesions, Benign nevus

Level of Evidence: 4

Etiology and Incidence

Melanoma is a disease resulting from the abnormal proliferation of melanocytes and their migration from the basal layer of the epidermis to the upper epidermis and dermis. Acral melanoma (AM), melanoma of the hand and foot, is the most prevalent melanoma in non-Caucasian populations, accounting for up to 70% of all melanomas in Africans, 50% in Asians, and 10% in whites.[1, 2] However, the lower prevalence in the Caucasian population can be attributed to the higher incidence of non-acral melanomas in Caucasians. The absolute incidence of AM has been estimated to be similar among ethnicities.[1] AM has been associated with a worse prognosis than other melanoma types, such as superficial spreading melanoma and nodular melanoma, a difference attributed to the high rate of misdiagnosis, between 25% and 36%.[3] Studies indicate that foot melanomas are prone to misdiagnosis, falsely diagnosed as tinea pedis, onychomycosis, warts, hematoma, paronychia, ingrowing toe nail, bacterial infection, ischemia or necrosis, blisters, ganglions, callus, and ulceration.[3] Late and misdiagnosis by physicians and ignorance of early signs by patients can be attributed to neglect of the feet during routine skin examinations, underlying diseases, especially diabetes mellitus, and confounding vascular and neurological disorders of old age. Acral melanomas are often amelanotic and lack the classic "ABCD" (asymmetry, border irregularity, color, diameter) signs of other melanomas, contributing to their misdiagnosis. AM's presentation as a brownish-black macule often causes confusion with a benign nevus. Prompt diagnosis and appropriate treatment are crucial to prevent the progression and dissemination of acral melanoma[4].

Diagnostic Methods

Histopathology has been the method of choice for the diagnosis of melanomas. The suspicious lesion is biopsied and examined for melanocyte location, mitotic figures, and degree of proliferation, tumor thickness and diameter. However it can be difficult to differentiate acral nevi from early acral melanoma because both conditions display proliferation of melanocytes in the epidermis. Further complicating the distinction, some acral nevi also display solitary arrangements of melanocytes in the crista profunda intermedia, a common feature of acral melanoma, as well as in the upper epidermis.[5] It is reported that a histological comparison of initial incision biopsy samples with later complete excision specimens indicates that the initial biopsy missed the presence of invasive melanoma in 20% of cases.[6] In the case of acral skin, the unique and uneven anatomical features of the area can make difficult the collection of biopsy specimens representative of the disease progression.[7] Excision and biopsy also exposes the patient

Image 1: Dermatoscopes[11]

to pain and infection, especially in the case of high-risk patients with diabetes mellitus.

Dermoscopy, a non-invasive skin surface microscopy shown in Image 1, is being utilized in conjunction with biopsy for the visualization and diagnosis of skin lesions. It facilitates the close and comprehensive examination of the large and mottled lesions, reducing the risk of misdiagnosis of pedal lesions and aids in the early detection of a malignancy.

It is useful to differentiate between acral nevus and early acral melanoma. Early acral melanomas demonstrate the preferential proliferation of melanocyte solitary arrangements in the crista profunda intermedia, the epidermal rete crossed by the exiting eccrine duct and representative of the overlying surface ridge.[8] Acral nevi, a common podiatric lesion, demonstrate melanocyte nests mainly in the crista profunda limitans, the epidermal rete under the surface furrows, with some presence in the crista profunda intermedia.[8] The preferential melanocyte proliferation at the crista profunda intermedia versus crita profunda limitans leads to the dermoscopically distinct parallel ridge pattern for early acral melanoma and parallel furrow pattern (PFP) for acral nevus. Refer to Image 2a and 2b. The presence of PRP is the dermoscopic gold standard for the detection of early acral melanoma; however, it was

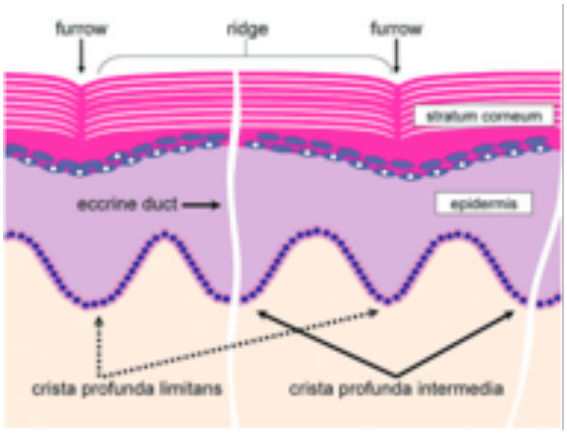

Image 2a: Anatomical structure of acral skin[8]

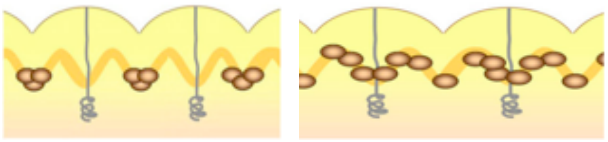

Image 2b: Melanin distribution patterns on acral skin[11]

recently shown that approximately one-third of AMs do not display a PRP dermoscopically, rendering their detection more troublesome.[2] Likewise, Lallas et al. stated although PFP's were the most potent predictor for the diagnosis of a nevus, posing a 9-fold probability, 10% of AM's exhibited PFP in some parts of the lesion. Subsequently, the detection of this feature should not exclude the diagnosis of AM when other melanoma-specific criteria are visualized. Similarly, a fibrillar pattern was associated with a 3-fold probability of a nevus, but was also present in 6-7% of AMs.[2]

Objectives

This paper reviews the literature and describes the advantages of dermoscopy in the field of podiatry by assessing all the dermoscopic criteria that ensure a positive predictive value of diagnosing an acral melanoma from an acral nevus. Additionally, it presents cases of misdiagnosis of a plantar-pigmented wart and a diabetic ulcer from a melanoma.

METHODS

Three independent online searches were performed using the Pubmed database. The search was done using the Boolean "and" and "or" operators. The first search included the terms "Dermoscopy" AND "foot lesions" AND "melanoma". This search provided 18 articles. The second search included the terms "Dermoscopy" OR "nevus" AND "foot lesions". This search provided 111 articles. The third search included the terms "Dermoscopy" AND "foot lesion" AND "histopathology". This search provided 12

articles. The initial search yielded 141 articles. Each contributor examined the abstracts of 35 articles and determined whether the papers met the criteria. Exclusion criteria consisted of studies that were conducted prior to 2009 and those not pertaining to our subject matter. Inclusion criteria consisted of availability of abstracts and studies conducted on human subjects. After applying the inclusion and exclusion criteria, first search yielded 3 articles, second search yielded 5 articles, and third search yielded 2 articles. Overall, 10 total articles were found. The search methods have been summarized in **Figure 1.** Additionally, all images used in this literature review were obtained from the articles reviewed with the permission from the author.

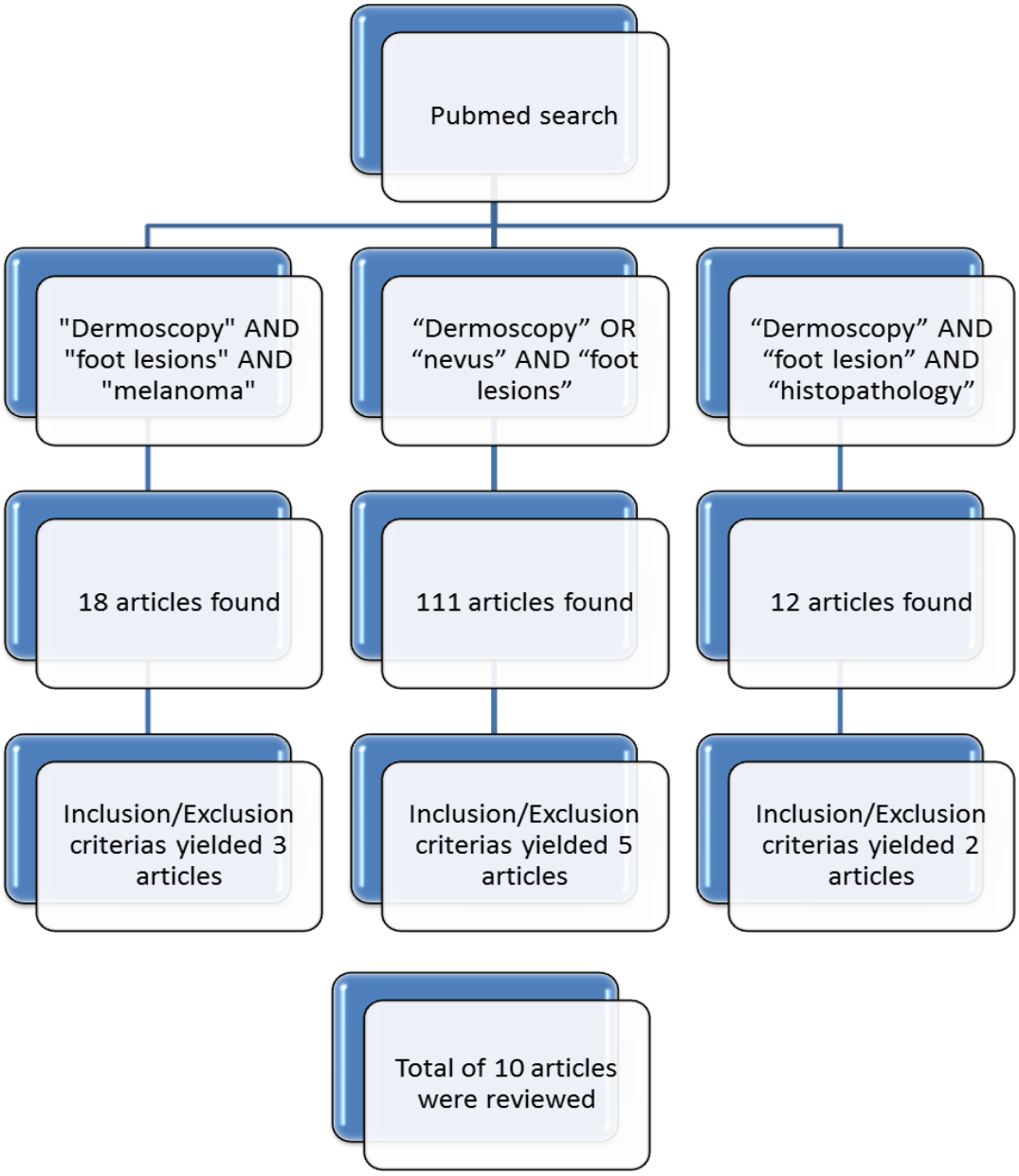

Figure 1 – Summary of Article search

RESULTS

Dermoscopic Patterns/Structures	Predictive value for melanoma	Prevalence
Benign patterns		
PFP (Image 3a)	Negative	23.8%
Lattice-like pattern (Image 3b)	Negative	9.8%
Lattice-like pattern with dots	Negative	7.8%
Fibrillar pattern (Image 3c)	Negative	12.0%
Pattern with globules	Negative	7.8%
Ladder pattern	Negative	4.4%
Benign pattern with dots and globules	Negative	4.3%
Malignant Patterns		
PRP (Image 4a)	Positive	17.6%
Bizarre pattern	Positive	26.2%
Milky red areas	Positive	20.5%
Diffuse pigmentation (Image 4b)	Positive	19.4%
Peripheral dots and globules	Positive	12.1%
Ends abruptly at the periphery	Positive	10.2%

Table 1 – Relationship between dermoscopic patterns and melanoma status[10]

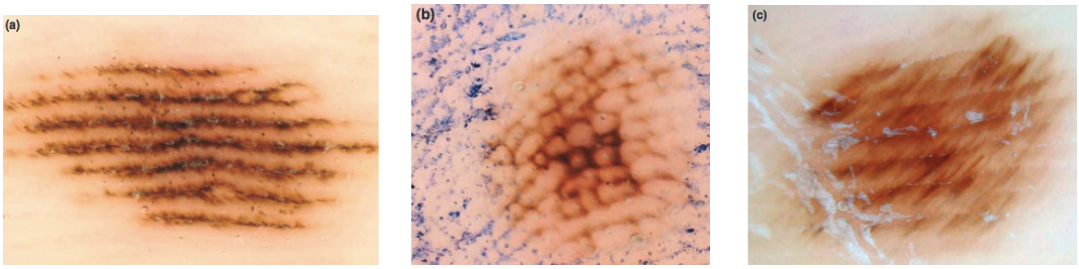

Image 3: Dermoscopic patterns of acral nevus a) PFP b) lattice-like c) fibrillar [2]

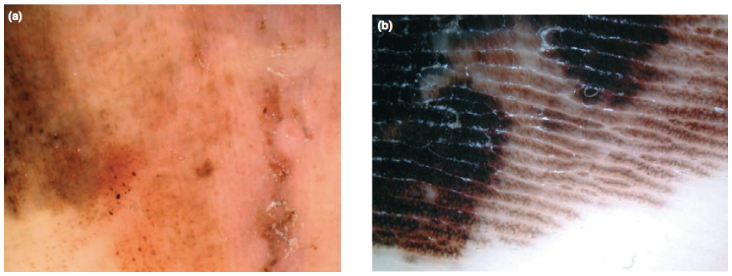

Image 4: Dermoscopic patterns of advanced acral melanoma a) irregular diffuse pigmentation b) PRP [2]

Dermoscopic variable	Nevus	Melanoma in situ	Melanoma invasive
Global Pattern			
Parallel lines	73.7%	62%	10%
Reticular	1.9%	5%	0%
Globular	4.9%	5%	1%
Structure less	13.8%	10%	38%
Starburst	0.2%	0%	0%
Multicomponent	5.5%	19%	51%
Other Patterns			
Asymmetry of structures	10.4%	48%	94%
Asymmetry of colors	9.3%	57%	94%
PRP	1.9%	50%	33%
PFP	59.7%	14%	8%
Fibrillar pattern	22.2%	10%	7%
Lattice- like pattern	11.4%	0%	0%
Irregular blotches	9.3%	33%	85%
Irregular dots/globules	9.7%	24%	57%
Irregular streaks/pseudopods	1.1%	2%	7%
Blue-white veil	6.6%	5%	46%
Regression structures	1.3%	7%	16%
Atypical vessels	0.4%	0%	16%
Atypical network	0.4%	5%	0%
Milky-red areas	0.6%	0%	19%

Table 2 - Frequency of dermoscopic criteria in 603 acral lesions according to diagnosis by Lallas et al[9]

Study	Number of pigmented skin lesions	Experience of the practitioners	Sensitivity with the use of dermatoscope
Bristow and Bowling	231	After 1 hour of training	69.7% to 96.3%
Sover, Aregenziano and Zalaudek	150	After 1 hour of training	91%
Sover, Argenziano and Hofmann-Wellenhof	150	No experience in dermoscopy	87%

Table 3 – Sensitivity in the recognition of skin cancer with the use of a dermatoscope by Bristow et al[11]

Dermoscopy as an Adjunct to Diagnosis :

A study by Ise and Yasuda described how dermoscopy was a helpful adjunct for the correct diagnosis of AM of the plantar foot, which had a hyperkeratotic appearance and mimicked a pigmented wart. They described a case report of an 81-year-old woman with a black-brown hyperkeratotic plaque of 10 mm with sharply demarcated symmetrical borders. Dermoscopic examination demonstrated a scaly surface and regular brown-to-black dots/globules as shown in Image 5a. At first the diagnosis of a pigmented wart was made. Later, biopsy and histopathological examination led to the diagnosis of a melanoma. Closer inspection of the lesion revealed surrounding pigmented macules with diffuse irregular hypopigmentation and PRP as shown in image 5b.[12] The final diagnosis of ALM in-situ was made.

Mansur and Demirci similarly reported on prediagnosis of a refractory diabetic ulcer. The distal phalanx was amputated and sent

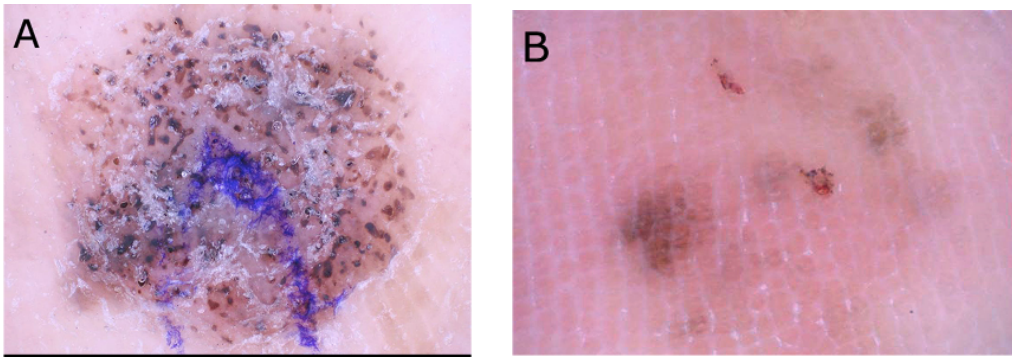

Image 5: Dermoscopic examination of a) hyperkeratotic lesion b) surrounding macules[12]

Image 6: Clinical presentation pre-amputation[4]

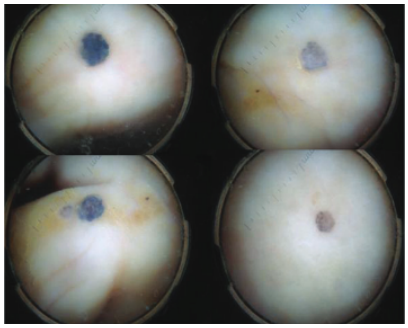

Image 7: Dermoscopic features of satellite lesions[4]

Image 8: Hyperkeratotic patch[7]

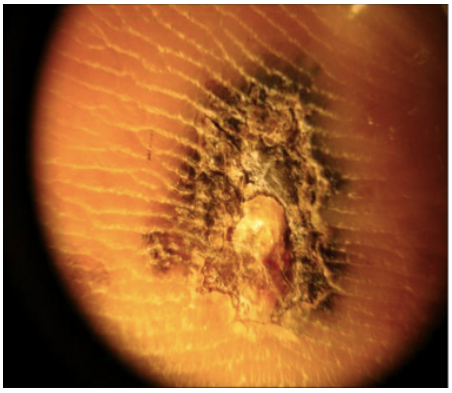

Image 9: PRP with abrupt cutoff of pigmentation[7]

to the pathology laboratory for histological evaluation. During this period, some papules and nodules scattered on the dorsal foot attracted attention and dermatological consultation was requested as seen in Image 6. The patient declared that these lesions had developed slowly over the previous year.[4] On dermatological examination, several greyish blue, hard, asymptomatic papules and nodules of 3–10mm in diameter were seen on the distal dorsal foot, neighboring the ulcer.[4] Dermoscopy of these lesions revealed homogenous, globular and structure-less blue-gray areas as seen in Image 7. Histopathological examination of the amputated phalanx showed ulcerated nodular melanoma.[4]

Oh and Bae provided a case report about a 66 year old female who presented with a 1.5 x 0.8 cm black-brown hyperkeratotic plaque on her heel surrounded by a brownish patch as seen in Image 8. The patient described the plaque starting as a small brown patch

and later developing a growing black macular center lesion.[7] Punch biopsy and histopathology indicated melanoma in-situ. Dermoscopic findings of PRP, abrupt end of pigmentation, and irregular diffuse pigmentation with focal depigmentation lead investigators to suspect more invasive malignancy.[7] Refer to Image 9. Wider excision revealed papillary dermis infiltration of tumor cell nests. They diagnosed the case as ALM with peripheral atypical melanosis.[7]

Watanabe's comparison of 5 cases of acral lentiginous melanoma (ALM) with 5 cases of acral melanocystic nevus (AMN) on weight-bearing areas of the sole showed the difference between regular fibrillar pattern (FP) of AMN and irregular fibrillar pattern of ALM. All ALM cases showed irregular color distribution, irregular fibril distribution, and "negative FP," whitish fibrils corresponding to eccrine ducts in the horny layer of the ridge against a background of structureless pigmentation. The white fibrils of negative FP stand out against the diffusely pigmented background. Four cases of AMN showed regular color distribution, regular fibril distribution, fibril termination at the furrows, and no white lines corresponding to eccrine ducts. Case 3 nevi was the exception because it showed negative FP; however this exception was distinguishable because the fibrils were regular and terminated at the furrows. The study shows that ALM in weight-bearing areas demonstrates structureless pigmentation and "negative FP," rather than PRP.[13]

DISCUSSION

Dermoscopic patterns of an acral melanoma vs. an acral nevus

Braun et al. evaluated 167 lesions for dermoscopic patterns to differentiate between an acral melanoma and a benign acral nevus. Based on the 13 dermoscopic patterns as presented in Table 1, the parallel furrow pattern (PRP) had the highest prevalence of all the benign patterns evaluated. The bizarre pattern had the highest prevalence of all the malignant patterns evaluated. The negative (benign) dermoscopy patterns of acral lesions are negatively associated with melanoma status and positive (malignant) dermoscopy patterns of acral lesions are positively associated with melanoma status. These results substantiate the authors' hypothesis in this study. Although the presence of PRP is the dermoscopic gold standard for detecting an early acral melanoma, Lallas et al. states that one-third of AMs do not display a PRP dermoscopically, making their detection more difficult. However, the study by Braun et al. illustrates other patterns that could be utilized to distinguish between an acral melanoma and a benign nevus.[10]

Moreover, Lallas et al. measured the frequencies of different dermoscopic patterns in 603 (472 nevi and 131 AMs) acral lesions. When analyzing the global patterns, parallel lines were the most frequent in nevi and in melanoma in situ. In contrast, a multi-component or a structureless pattern was more common in invasive melanoma. The 4 positive predictors for the diagnosis of an acral melanoma were identified as irregular blotches, parallel ridge pattern, asymmetry of structures, and asymmetry of colors. This study further demonstrates other dermoscopic criteria that could be used to help diagnose a melanoma from a nevus as shown in Table 2.[9]

Furthermore, Bristow and Bowling demonstrated that even with minimal training of using a dermatoscope, the sensitivity of identifying a malignancy improved from 69.7% to 96.3% as opposed to not using dermoscopy as a tool for identification. Table 3 further highlights additional studies that show improved sensitivity of diagnosing a malignancy with the use of a dermatoscope with minimal to no training at all.[11]

Dermoscopy as an adjunct to diagnosis:

The three one-patient case reports and one comparative study that were reviewed indicate that dermoscopy can be a valuable tool to avoid potential misdiagnosis of acral melanoma.

Ise and Yasuda's case report illustrates the value of dermoscopy in the correct diagnosis of melanoma. The observation of sharp and symmetrical borders and regular brown-black dots led to the initial diagnosis of a pigmented wart. However, dermoscopic examination of the larger surrounding area revealed pigmented macules with diffuse, irregular hypopigmentation and PRP. These dermoscopic observations were crucial in the final diagnosis of ALM in-situ[12].

Mansur and Demirci incorrectly diagnosed the non-healing, painless ulcer as a refractory diabetic ulcer and proceeded to amputate. However the clinicians would have made the correct diagnosis of acral melanoma with macroscopic satellitosis before treatment if dermoscopy had been used to observe the lesion[4]

Oh and Bae's case report of the 66 year old female patient indicates that the observation of specific dermoscopic patterns (PRP, abrupt end of pigmentation, and irregular diffuse pigmentation with focal depigmentation) led the clinicians to suspect more progressed melanoma than indicated by the initial biopsy. The dermoscopic patterns were critical in the diagnosis of invasive acral melanoma, despite initial indication of melanoma in-situ.

Watanabe's comparative study of 10 acral lesions may be able to partially address the presence of fibrillar pattern in 6-7% of acral melanomas, as indicated by Lallas et al. This study demonstrates that a more detailed understanding of dermoscopic patterns aids in the distinction between regular fibrillar pattern, indicative of benign nevi, and irregular negative fibrillary pattern, indicative of melanoma. PRP in non-weight-bearing ALM is the pattern resulting from diffuse pigmentation divided by whitish lines at the furrows. However, weight bearing produces a shift in the horny layer in areas of the sole, causing PRP pigmentation to become more diffuse and providing a dark, diffusely pigmented background. The presence of eccrine ducts in the crista profunda intermedia causes the observed negative FP. In contrast, acral nevus in weight-bearing areas show a regular fibrillar pattern (FP) produced by the slanting of melanin columns in the horny layer. Fibrillar pattern is normally designated as a benign pattern. However, if seen in the weight-bearing areas of the sole, ALM should be considered. Careful dermoscopic examination of lesions in weight-bearing areas of the sole could prevent potential misdiagnosis of acral melanoma.

LIMITATIONS

Throughout this literature review, several limitations were noted. The lack of consensus on the definition of dermoscopic terms bars a more comprehensive analysis of the studies reviewed. Even though Lallas offers clear definitions of terms, such as irregular blotches and irregular dot/globules, the adherence to and use of such terms are not universal. For example, this review could not determine if Oh and Bae's "irregular diffuse pigmentation" corresponds to Lallas' "irregular blotches." [7, 9] It should also be noted that all dermoscopic observations must be understood within the clinical context. Dermoscopy is not a tool to be used in lieu of other factors, such as age and illness, but in conjunction with more established methods.

CONCLUSION

Although dermoscopy is not the gold-standard for diagnosis, it is a useful adjunct tool in the diagnosis of melanoma. From the literature we can conclude that dermoscopy

can improve the clinician's ability to make the correct diagnosis of an unknown podiatric lesion. With further research of dermoscopic patterns and improved physician training, dermoscopy has the potential to become the primary diagnostic tool for the evaluation of dermatological lesions. Dermoscopy is a less invasive yet efficient method that can minimize the patient's exposure to anesthesia and prevent the formation of a biopsy induced ulcer in diabetic patients.

AUTHORS' CONTRIBUTIONS

The authors contributed equally to the production of the paper. All conceived the topic, performed the initial literature reviews, evaluated abstracts, authored introduction, results and discussion. All authors drafted, read, reviewed, and agreed upon the final manuscript.

STATEMENT OF COMPETING INTERESTS

The authors declare that they have no competing interest associated with this manuscript.

REFERENCES

1. Stevens NG, Liff JM, Weiss NS. Plantar melanoma: is the incidence of melanoma of the sole of the foot really higher in blacks than whites? *Int J Cancer* 1990;45:691–3

2. Saida, T., Koga, H., & Uhara, H. Key points in dermoscopic differentiation between early acral melanoma and acral nevus. *The Journal of Dermatology.* 2010;25-34

3. Fortin PT, Freiberg AA, Rees R, Sondak VK, Johnson TM. Malignant melanoma of the foot and ankle. *J Bone Joint* Surg Am. 1995;77:1396–403

4. Mansur AT, Dermirici GT, Ozel O, Ozker E, Yildiz S. Acral melanoma with satellitosis, disguised as a longstanding diabetic ulcer: a great mimicry. *Int Wound J.* 2015; doi: 10.1111

5. Saida, T., Koga, H., Goto, Y., & Uhara, H. Characteristic Distribution of Melanin Columns in the Cornified layer of Acquired Acral Nevus: An Important Clue for Histopathologic Differentiation From Early Acral Melanoma. *The American Journal of Dermatopathology*. 2011; 468-473

6. Somach SC, Taira JW, Pitha JV, Everett MA. Pigmented lesions in actinically damaged skin. Histopathologic comparison of biopsy and excisional specimens. *Arch Dermatol* 1996;132:1297-1302

7. Oh TS, Bae EU, Ro KW, Seo SH, Son SW, Kim IH. Acral lentiginous melanoma developing during long-standing atypical melanosis: usefulness of dermoscopy for detection of early acral melanoma. *Ann Dermatol.* 2011; 23(3): 400-404

8. Jin, L., Arai, E., Anzai, S., Kimura, T., Tsuchida, T., Nagata, K., & Shimizu, M. Reassessment of histopathology and dermoscopy findings in 145 Japanese cases of melanocytic nevus of the sole: Toward a pathological diagnosis of early-stage malignant melanoma in situ. *Pathology International*. 2010;65-70

9.Lallas, A., Kyrgidis, A., Koga, H., Moscarella, E., Tschandl, P., Apalla, Z., Argenziano, G. The BRAAFF checklist: A new dermoscopic algorithm for diagnosing acral melanoma. *Br J Dermatol British Journal of Dermatology.* 2015;1041-1049

10.Braun, R.. Dermoscopy of Acral Melanoma: A Multicenter Study on Behalf of the International Dermoscopy Society. *Dermatology.* 2013;*227*(4). doi: 10.1159/000356178

11. Bristow, I., Bowling, J. Dermoscopy as a technique for the early identification of foot melanoma. *Journal of Foot and Ankle Research J Foot Ankle Res.* 2009;14-14

12. Ise M, Yasua F, Konohana I, Miura K, Tanaka M. Acral melanoma with hyperkeratosis mimicking a pigmented wart. *Dermatol Pract Concept*. 2012; 3(1):10

13. Watanabe S, Mizuki S, Sumiko I, Kobayashi K, Tanaka M. Comparison of dermatoscopic images of acral lentiginous melanoma and acral melanocytic nevus occurring opn body weight-bearing areas. *Dermatol Pract Concept*. 2014; 4(4):8

*The design of this journal was conceived by J. Adrian Wright, AM.