PubMed and Full-Text Retrieval

Disclaimer:

This presentation is not about the intricacies of searching (strategies and the like) but about the mechanics of retrieving the full-text of a record you have found on PubMed.

Outline

- We will review the different steps to accessing PubMed from the NYCPM Library website.
- We will also explore the on- and off-campus differences
- After performing your search, and once PubMed has displayed a list of records of your choice, we will investigate different options to retrieve the text of an article

Whether you are on-campus or off-campus, go to NYCPM Library website, located at http://www.nycpm.edu/library.asp



NYCPM
NEW YORK COLLEGE OF PODIATRIC MEDICINE

Email | Foot Center of NY | Library Services | Contact Us | Intranet

Welcome | Prospective Students | Students | Faculty | Alumni | News & Events | GME & CME | Classifieds

LIBRARY

Thomas Walker, M.S.L.I.S., Director (212) 410-8020

Librarian	Paul Tremblay, MLIS, MA
Library Assistant	Merleen Chisholm
Library Assistant	Richard Mandel
Assistant Librarian	Michael Perlman, MSLS

View the **2012-2013 Library operating schedule** here.

Click **here** to browse our on-line book catalog .

To request materials from us please click for our **Interlibrary Loan Request Form**.

Library Hours:

The Library is open for general use as follows:

Library hours*

Welcome to the Library site! Now the hard part (believe it or not!)

- If you are **on-campus**, no problem, the system recognizes the IP Address and treats you like family! No need to log in.

If you are **off-campus**, you will see a dialog box (about halfway down the page) asking you to log in.
Your login info has been emailed to you by the Library Director already. When in doubt, ask us.
Once you have input your login info, the system recognizes you as an NYCPM member and you are as good as on-campus (almost…)

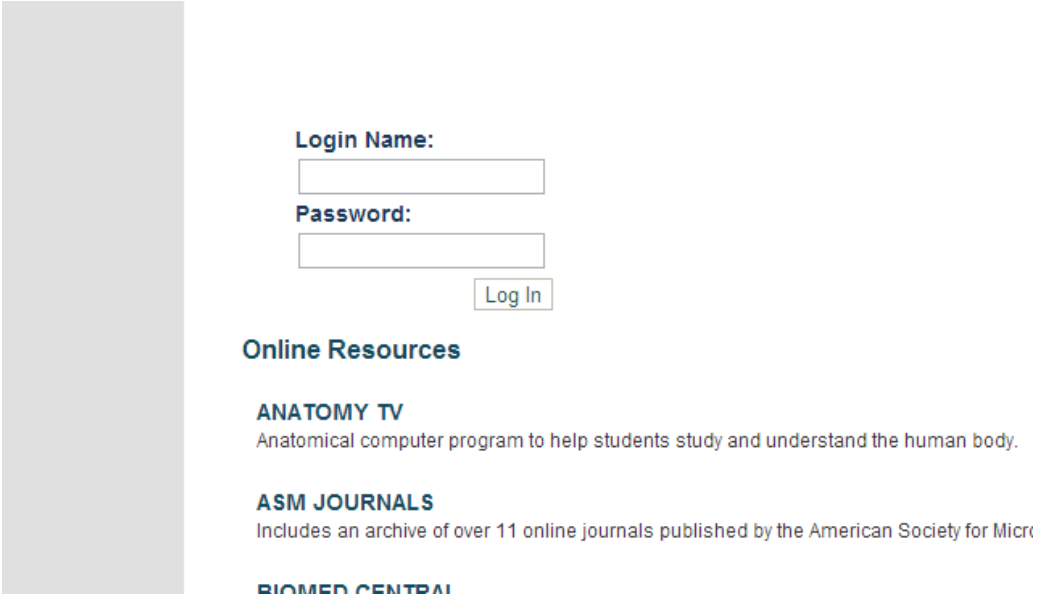

Next step…

- Scroll down the page and click on PUBMED…
- Do not type in the PubMed.gov address (or URL) in the URL box, as the system will not recognize your affiliation and full-text, if available, will not be retrievable

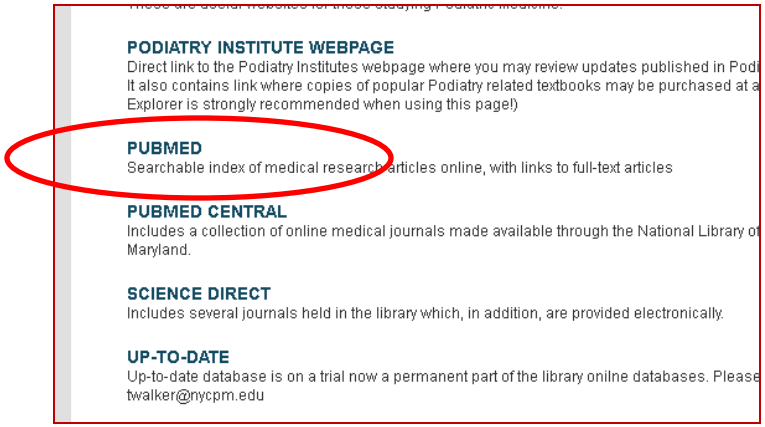

Welcome to PubMed

NCBI Resources How To Sig

PubMed.gov
US National Library of Medicine
National Institutes of Health

PubMed Search

Advanced

PubMed

PubMed comprises more than 22 million citations for biomedical literature from MEDLINE, life science journals, ar
online books. Citations may include links to full-text content from PubMed Central and publisher web sites.

Using PubMed

- PubMed Quick Start Guide
- Full Text Articles
- PubMed FAQs
- PubMed Tutorials
- New and Noteworthy

PubMed Tools

- PubMed Mobile
- Single Citation Matcher
- Batch Citation Matcher
- Clinical Queries
- Topic-Specific Queries

More Resources

- MeSH Database
- Journals in NCBI Databases
- Clinical Trials
- E-Utilities
- LinkOut

You are here: NCBI > Literature > PubMed

Write to t

GETTING STARTED	RESOURCES	POPULAR	FEATURED	NCBI INFORMATION
NCBI Education	Chemicals & Bioassays	PubMed	Genetic Testing Registry	About NCBI
NCBI Help Manual	Data & Software	Nucleotide	PubMed Health	Research at NCBI
NCBI Handbook	DNA & RNA	BLAST	GenBank	NCBI Newsletter
Training & Tutorials	Domains & Structures	PubMed Central	Reference Sequences	NCBI FTP Site
	Genes & Expression	Gene	Map Viewer	NCBI on Facebook
	Genetics & Medicine	Bookshelf	Human Genome	NCBI on Twitter
	Genomes & Maps	Protein	Mouse Genome	NCBI on YouTube

Reminder!

- We will *not* cover Search Strategies, boolean logic, truncations, MESH, etc.
- The Director of the Library usually teaches workshops to that effect.
- We will assume that you have correctly searched for articles, based on a topic or research project.

Let us assume that you have searched for …

- Hallux Valgus AND Juvenile*
- …you came up with 38 records.

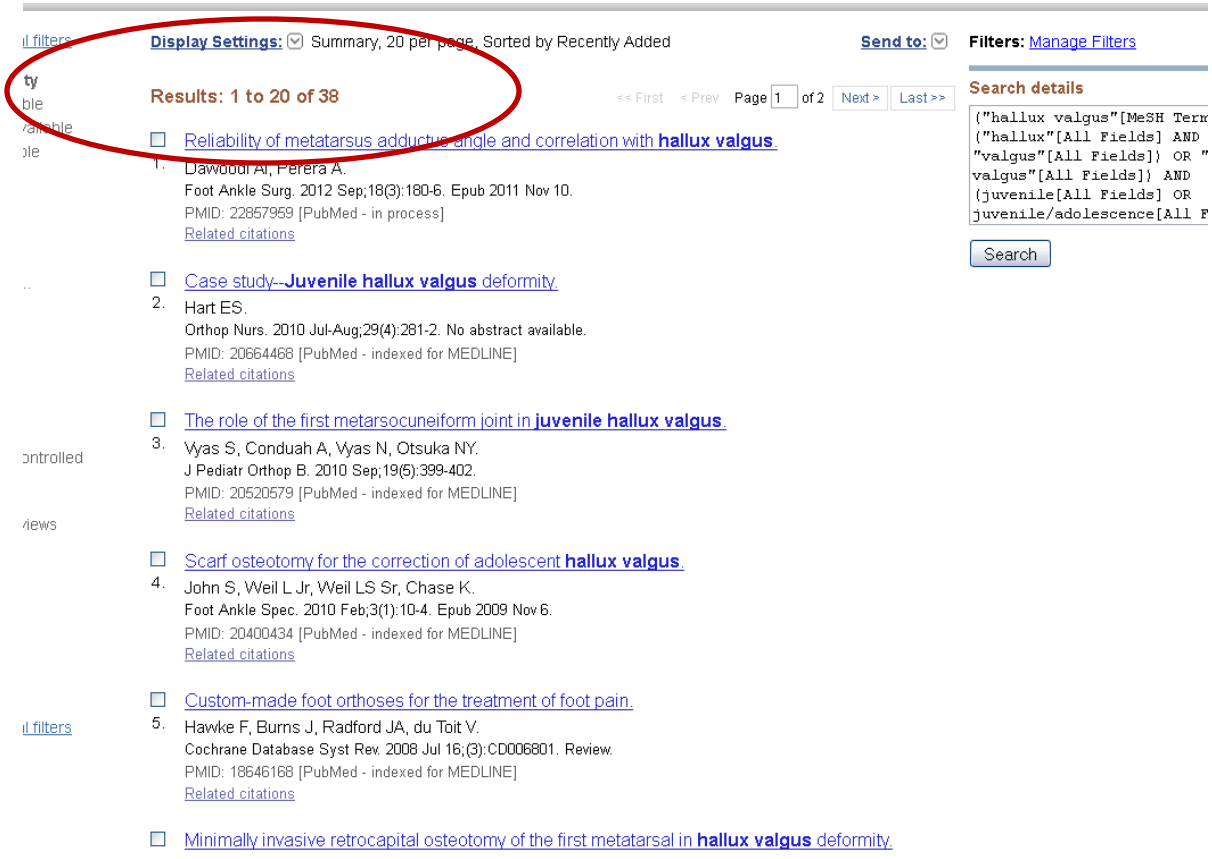

What now?...

- The correct and sensible way to figure out if the results (hits) fit your needs is to open each and every link and read the abstract (if available).
- You have noticed that the list does not inform you upon the full-text availability of the records. You need to click on the links
- For instance, let's open Record #4 (Scarf osteotomy for the correction of adolescent **hallux valgus.**)

…click on the "title" (blue link)

Case study--**Juvenile hallux valgus** deformity.

2. Hart ES.
Orthop Nurs. 2010 Jul-Aug;29(4):281-2. No abstract available.
PMID: 20664468 [PubMed - indexed for MEDLINE]
Related citations

The role of the first metarsocuneiform joint in **juvenile hallux valgus**.

rolled

3. Vyas S, Conduah A, Vyas N, Otsuka NY.
J Pediatr Orthop B. 2010 Sep;19(5):399-402.
PMID: 20520579 [PubMed - indexed for MEDLINE]
Related citations

vs

Scarf osteotomy for the correction of adolescent **hallux valgus**.

4. John S, Weil L Jr, Weil LS Sr, Chase K.
Foot Ankle Spec. 2010 Feb;3(1):10-4. Epub 2009 Nov 6.
PMID: 20400434 [PubMed - indexed for MEDLINE]
Related citations

Custom-made foot orthoses for the treatment of foot pain.

ters

5. Hawke F, Burns J, Radford JA, du Toit V.

…a good idea would be to read the abstract first…

- Maybe this is a good article for your project. The abstract (a summary of the article) could be anything between 10 to a few hundred words.
- The goal, methodology, findings and conclusion are usually summarized.
- Let's say that this is the article of your dreams…
- From here, you have a few options, depending on the situation…

Option 1, the easiest, the full-text is readily available. Always, always look up the upper right-hand corner for an icon

Display Settings: Abstract

Send to:

NYCPM Full Text Available

Foot Ankle Spec. 2010 Feb;3(1):10-4. Epub 2009 Nov 6.

Scarf osteotomy for the correction of adolescent hallux valgus.

John S, Weil L Jr, Weil LS Sr, Chase K.

Weil Foot and Ankle Institute, Des Plaines, Illinois 60016, USA. sj@weil4feet.com

Abstract

Adolescent hallux valgus deformity is a complex surgical condition. Although several techniques have been described to correct this deformity in adults, limitations exist for adolescents because of the presence of open growth plates and high recurrence rates. This retrospective study reports results of 7 patients (14 feet) using the Scarf osteotomy for correction of adolescent hallux valgus deformity. All patients underwent concomitant bilateral hallux valgus surgery. Radiographic evaluation measures included intermetatarsal 1-2 angle, hallux valgus angle, and distal metatarsal articular angle. Data recorded from the lateral radiograph evaluated the first metatarsal declination angle. Postoperative patient satisfaction was assessed using a standard patient satisfaction survey. Postoperative, subjective, and objective measurements were calculated using the American College of Foot and Ankle Surgeons (ACFAS) Scoring Scale for the First Metatarsophalangeal Joint and First Ray and the American Orthopaedic Foot & Ankle Society (AOFAS) Hallux Metatarsophalangeal-Interphalangeal Scoring Scale. Average patient age and follow-up were 14.43 years and 57 months, respectively. There was 100% maternal inheritance of hallux valgus deformity. The average postoperative ACFAS Metatarsophalangeal Joint and First Ray Scale (module 1) score was 94.72, and the average AOFAS Hallux Metatarsophalangeal-Interphalangeal Scale score was 96.43. Complications included 1 patient who underwent revision surgery on 1 foot 18 years after the date of index surgery because of painful recurrence of the deformity. The authors believe the Scarf osteotomy is a safe, effective, and versatile procedure for the correction of juvenile and adolescent hallux valgus deformity.

PMID: 20400434 [PubMed - indexed for MEDLINE]

MeSH Terms

LinkOut - more resources

Save items

Add to Favorites

Related citations in PubMed

[Scarf osteotomy for the treatment of forefoot deformity]. [Acta Chir Orthop Traumatol Cec...]

Arthroscopy-assisted correction of hallux valgus deformity. [Arthroscopy. 2008]

Hallux valgus and first ray mobility. A prospective study. [J Bone Joint Surg Am. 2007]

Review Percutaneous distal metatarsal osteotomy for corn [J Bone Joint Surg Am. 2006]

Review Modified Austin procedure for correction of hallux valgus [Foot Ankle Int. 1997]

See reviews...

See all...

Recent activity

Turn Off Clear

Click on the icon… et voilà!

Clinical Research

Scarf Osteotomy for the Correction of Adolescent Hallux Valgus

Shine John, DPM, AACFAS,
Lowell Weil Jr, DPM, MBA, FACFAS,
Lowell Scott Weil Sr, DPM, FACFAS,
and Kari Chase, MS

Abstract: *Adolescent hallux valgus deformity is a complex surgical condition. Although several techniques have been described to correct this deformity in adults, limitations exist for adolescents because of the presence of open growth plates and high recurrence rates. This retrospective study reports results of 7 patients (14 feet) using the Scarf osteotomy for correction of adolescent hallux valgus deformity. All patients underwent concomitant bilateral hallux valgus surgery. Radiographic evaluation measures included intermetatarsal 1-2 angle, hallux valgus angle, and distal metatarsal articular angle. Data recorded from the lateral radiograph evaluated the first metatarsal declination angle. Postoperative months, respectively. There was 100% maternal inheritance of hallux valgus deformity. The average postoperative ACFAS Metatarsophalangeal Joint and First Ray Scale (module 1) score was 94.72, and the average AOFAS Hallux Metatarsophalangeal-Interphalangeal Scale score was 96.43. Complications included 1 patient who underwent revision surgery on 1 foot 18 years after the date of index surgery because of painful recurrence of the deformity. The authors believe the Scarf osteotomy is a safe, effective, and versatile procedure for the correction of juvenile and adolescent hallux valgus deformity.*

Keywords: adolescent bunion; juvenile bunion; Scarf osteotomy; hallux valgus;

seal growth plates can limit the surgical correction in a juvenile deformity. High recurrence rates have been noted in this younger patient demographic.[1]

Adaptations of various osteotomies and use of multiple osteotomies have been described in the literature for juvenile hallux valgus.[2-4] Recently, Davids et al[1] reported their results of lateral hemiepiphyseodesis of the first metatarsal as an alternative to other skeletal and soft-tissue balancing procedures. This was anecdotally reported by Stephen D. Smith, DPM, 30 years ago, but it was never published in the literature.

The Scarf bunionectomy was originally described and has been used by the senior author (L.S.W.) for more than 2 decades.[5] The senior authors (L.S.W.

Save it, Print it, Read it, Email it…

Option 2: the article is available *in print*, in the library; in which case you will see this icon:

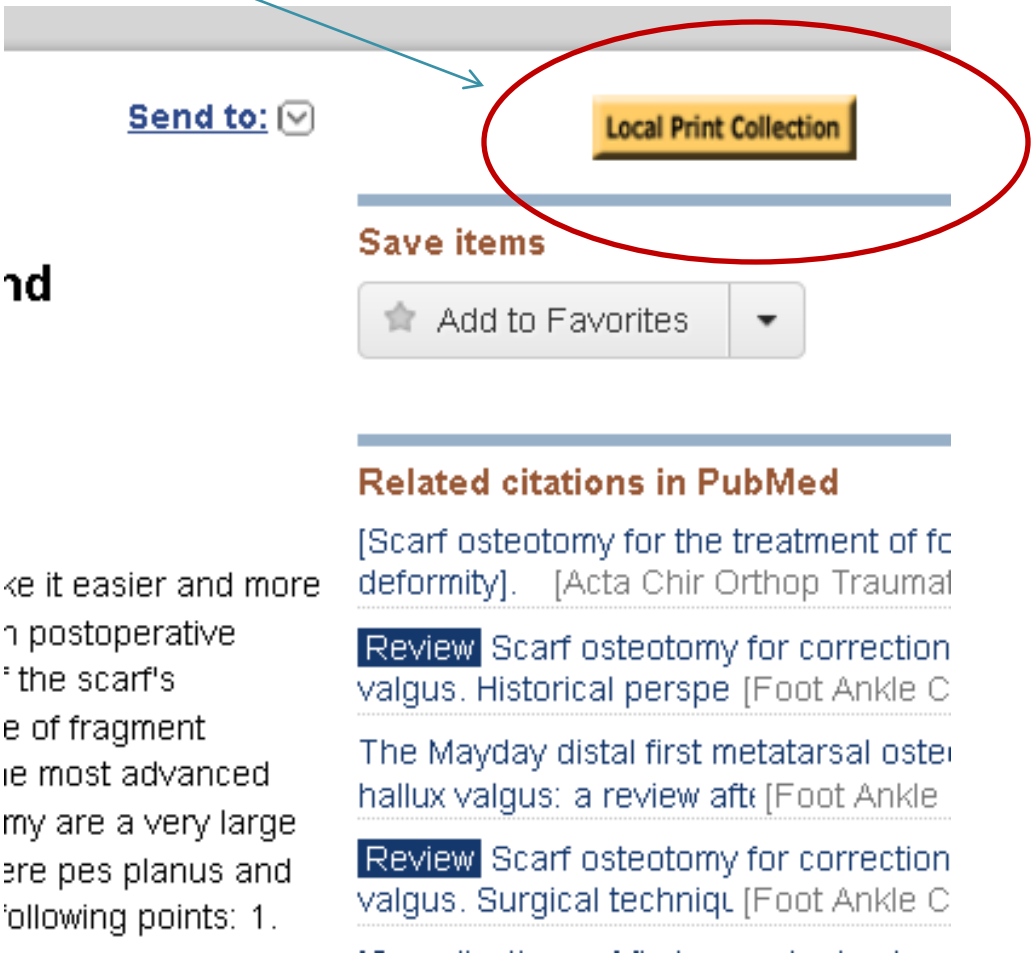

In this event…

- … you need to visit the library, find the journal and photocopy the article…
- Call/email us if you need help.

Option 3

- In the event that we do not have direct access to the full-text of the article…
- Let's say that there is no icon of any sort…
- No problem!!
- Just request the article through our Inter Library Loan Request Form page.
- Just go to the library page and click on…

…this link…

LIBRARY

Thomas Walker, M.S.L.I.S., Director (212) 410-8020

Librarian	Paul Tremblay, MLIS, MA
Library Assistant	Merleen Chisholm
Library Assistant	Richard Mandel
Assistant Librarian	Michael Perlman, MSLS

View the **2012-2013 Library operating schedule** here.

Click **here** to browse our on-line book catalog .

To request materials from us please click for our **Interlibrary Loan Request Form**.

Library Hours:

The Library is open for general use as follows:

Library hours*

Fill in the form, we will request the article for you…

- …in a very timely manner. We'll email you the PDF version of the article once we obtain it from another institution.

…any questions?

- You know where we are.
- Do not hesitate to call, email us anytime.
- We are here to help!!
- Good luck!